

Unusual Case of Respiratory Failure in a HIV Infected Patient: HSV Type 2 Pneumonia

B Vahid, F Jaffe

Citation

B Vahid, F Jaffe. *Unusual Case of Respiratory Failure in a HIV Infected Patient: HSV Type 2 Pneumonia*. The Internet Journal of Pulmonary Medicine. 2005 Volume 6 Number 1.

Abstract

We report a case of HSV type 2 pneumonia in an HIV infected patient. The patient was empirically treated for severe *Pneumocystis jiroveci* community acquired pneumonia. Bronchoscopy with bronchoalveolar lavage was done, the cytology of which was negative for *Pneumocystis jiroveci*. All cultures were negative. HSV type 2 was isolated from BAL on culture. The patient died of pulmonary embolism. The autopsy showed lymphocytic interstitial pneumonia and HSV type 2 was isolated from lung tissue.

FOOT NOTE

HSV: Herpes simplex virus

BAL: Bronchoalveolar lavage

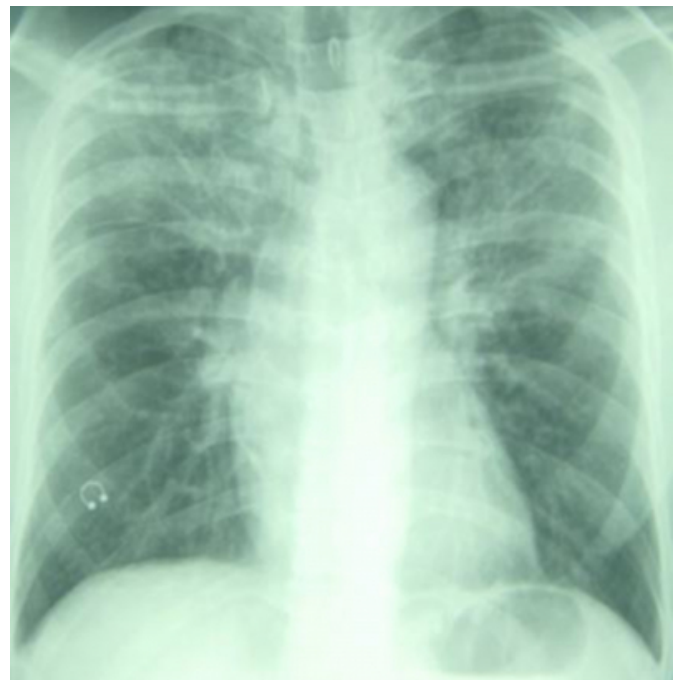HIV: Human Immunodeficiency Virus

CASE REPORT

A 42 year-old African American man presented to the emergency department (ED) with complaints of fever, cough and progressive dyspnea in the past several days. One month before presentation, he was diagnosed with Human Immunodeficiency Virus (HIV) infection, the origin of which was thought to be as a result of unprotected homosexual intercourse. His CD4 lymphocyte count was 34 /ml at that time. Highly Active Anti-Retroviral Therapy (HAART) and prophylactic Bactrim was offered to him, but he declined. One week before presentation, he was seen at ED for fever and cough. Chest radiograph revealed bilateral interstitial infiltrates (Figure 1). *Pneumocystis jiroveci* (*Pneumocystis carinii*) pneumonia was suspected and he was treated and discharged on oral Bactrim.

Figure 1

Figure 1: Chest radiograph one week before presentation showing interstitial infiltrates.

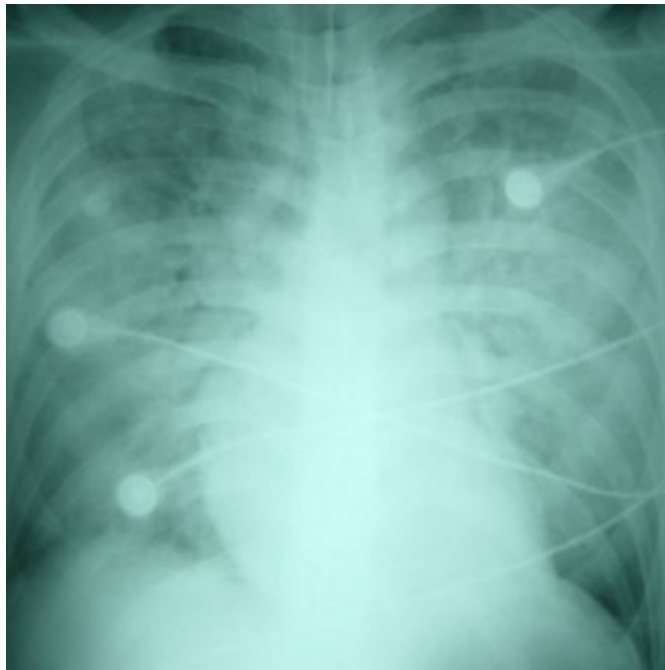


On the admission physical examination his temperature was 38.5°C, heart rate was 140 beats/min, respiratory rate was 40 breaths/min, and oxygen saturation was 70% on room air. Skin and mucosal surfaces were free of any lesions. Chest auscultation revealed diffuse bilateral crackles. The cardiac and abdominal exams were unremarkable. The neurological examination was normal. White blood cell count was 19,800 /ml³. Blood chemistry and hemoglobin level were normal.

The patient was intubated for hypoxia and transferred to intensive care unit. Repeat chest radiograph showed worsening of bilateral infiltrates (Figure 2).>

Figure 2

Figure 2: Chest radiograph on admission showing progression of bilateral infiltrates.



A fluoroquinolone and a macrolide were empirically started to treat presumed severe community acquired pneumonia. Patient also received Bactrim along with corticosteroids for possible *Pneumocystis jiroveci* pneumonia. Several blood cultures were negative. An echocardiogram showed normal left ventricular systolic function. Bronchoscopy with bronchoalveolar lavage (BAL) was done. BAL cytological evaluation revealed no evidence of *Pneumocystis jiroveci* infection. BAL cultures were negative for bacteria, mycobacteria, and legionella. BAL viral culture grew Herpes Simplex Virus (HSV) type 2. This positive result for HSV was thought to be due to contamination or colonization of respiratory tract. Unfortunately the patient developed multiple pulmonary emboli and died. An autopsy was performed. The pathologic examination of lung tissue showed lymphocytic interstitial infiltrates. Viral inclusions were noticed in endothelial cells and macrophages. HSV type 2 was isolated from lung tissue (cell culture by ELVIS® method). These findings strongly suggest a diagnosis of HSV type 2 pneumonia in an HIV infected patient.

DISCUSSION

Herpes simplex virus (HSV) is a widespread pathogen that is capable of causing a lower respiratory tract infection in a susceptible host, the most common form of which is tracheobronchitis. Although rare, HSV also can cause pneumonia. HSV type 2 pneumonia is extremely rare¹. HSV lower tract infection is most likely the result of the reactivation of endogenous herpes virus. In recipients of liver and heart-lung transplants, HSV pneumonia was diagnosed only in patients that were Anti-HSV-IgG seropositive preoperatively^{2, 3}. Although few cases of HSV pneumonia have been reported in immunocompetent hosts, it seems that suppression of cell-mediated immunity is the most important risk factor for development of HSV pneumonia. Conditions that are associated with HSV pneumonia includes HIV infection⁴, aplastic anemia, acute myeloblastic leukemia, acute lymphoblastic leukemia, plasma cell leukemia, Hodgkin's disease, bone marrow transplantation, solid organ transplantation, alcoholism⁵, burns⁶, postthoracotomy⁷, and cardiac surgery⁸. In one report, all three patients that developed HSV pneumonia after thoracotomy were immunosuppressed, had a recent history of chemotherapy, malnutrition, and severe postoperative complications⁷. Depressed cell-mediated immunity after cardiopulmonary bypass has been described as an important risk factor in the development of HSV pneumonia after cardiac surgery⁸. Pulmonary HSV infection has also been associated with intubation and mechanical ventilation in patients with chronic disease. Since HSV usually infects squamous epithelial cells, squamous metaplasia of tracheobronchial tree as a result of intubation may explain the association between intubation and HSV lower respiratory tract infection. Infection and colonization of squamous metaplasia of trachea could lead to an extension of the infection to the lower respiratory tract and eventually could cause pneumonia in a susceptible patient¹.

Two patterns of HSV pneumonia have been identified. The first pattern is a focal or multifocal necrotizing pneumonia caused by the direct spread of the virus from lesions in the upper respiratory tract or through the extension of herpetic tracheobronchitis. The second pattern is a diffuse pneumonia secondary to the hematogenous dissemination of HSV, most likely from oral or genital mucocutaneous lesions^{1, 9}. In one study, all bone marrow transplant recipients developed HSV pneumonia within 28 days after transplantation. Interestingly, at the time diagnosis of pneumonia most of these patients were neutopenic⁵. In another observation in

recipients of heart-lung transplants, all cases of HSV pneumonia were diagnosed within 2 months after transplant². Oral and genital herpetic lesions, tracheitis, and esophagitis are commonly reported in patients with HSV pneumonia. Clinical manifestations of HSV pneumonia include fever, cough, dyspnea, and respiratory failure⁵. Diffuse infiltrates, lobar consolidation, multifocal infiltrates, unilateral and bilateral pleural effusions can be seen on chest imaging¹⁰. Detection of HSV in sputum, BAL, lung tissue by culture, polymerase chain reaction (PCR), and immunochemical staining has been utilized to establish the diagnosis of HSV pneumonia^{3, 5, 7}. HSV pneumonia is a potentially fatal condition⁵. Successful treatment with Acyclovir and supportive care has been reported in the literature^{1,8}. The acyclovir-resistant HSV strains causing pneumonia have been described. These strains of HSV are also resistant to Gancyclovir. Foscarnet is an alternative agent for treatment of these patients¹¹.

HSV type 2 pneumonia is extremely rare. HSV pneumonia should be considered in susceptible patients with pneumonia and respiratory failure who do not respond to antibiotics. When no bacterial or fungal pathogenic agent can be identified, empiric Acyclovir could be considered. Herpetic oral, genital, and tracheal lesions should alert the physicians to the possibility of HSV pneumonia.

ACKNOWLEDGEMENT

We would like to thank Miss Poopak Vahid for her support and Dr Tuhina Raman for editing the manuscript.

CORRESPONDENCE TO

Bobbak Vahid, MD Thomas Jefferson University 1015 Chestnut Street, Suite M-100 Philadelphia, PA 19107 Tel: 215 955-6591 Fax: 215 955-0830
Bobbak.vahid@mail.tju.edu

References

1. Calore E E. Herpes simplex type 2 pneumonia. BJID.2002 6:305-308.
2. Smyth RL, Higenbottam TW, Scott JP, et al. Herpes simplex virus infection in heart-lung transplant recipients. Transplantation. 1990; 49:735-739.
3. Allen KA, Markin RS, Rennard SI, et al. Bronchoalveolar lavage in liver transplant patients. Acta Cytologica. 1989; 33:539-543.
4. Umar SH, Kanth A. Disseminated cutaneous herpes simplex virus type-1 with interstitial pneumonia as a first presentation of AIDS. J Nat Med Asso. 1999; 91:471-474.
5. Ramsey PG, Fife KH, Hackman RC, et al. Herpes simplex virus pneumonia. Ann Intern Med. 1982; 97:813-820.
6. Byers RJ, Hasleton PS, Quigley A, et al. Pulmonary herpes simplex in burns patients. Eur Respir J. 1996; 9:2313-2317.
7. Camazine B, Antkowiak JG, Nava MR, et al. Herpes simplex viral pneumonia in the postthoracotomy patient. Chest. 1995; 108:876-879.
8. Shimokawa S, Watanabe S, Taira A, et al. Herpes simplex virus pneumonia after cardiac surgery: Report of a case. Surg Today. 2001; 31:814-816.
9. Martinez E, de Diego D, Paradis A, et al. Herpes simplex pneumonia in a young immunocompetent man. Eur Respir J. 1994; 7:1185-1188.
10. Umans U, Golding RP, Duraku S, et al. Herpes simplex 1 pneumonia: Conventional chest radiograph pattern. Eur Radiol. 2001; 11:990-994.
11. Ljungman P, Ellis MN, Hackman RC, et al. Acyclovir-resistance herpes simplex virus causing pneumonia after marrow transplantation. J infect. 1990; 162:244-248.

Author Information

Bobbak Vahid, M.D.

Department of Pulmonary and Critical Care Medicine, Thomas Jefferson University

Fredric Jaffe, D.O.

Department of Pulmonary and Critical Care Medicine, Thomas Jefferson University