

Spontaneous expulsion of Urethral Foreign Body: A case Report

A Ajape, A Abdulkadir, A Babata, S Kuranga, O Adesiyun

Citation

A Ajape, A Abdulkadir, A Babata, S Kuranga, O Adesiyun. *Spontaneous expulsion of Urethral Foreign Body: A case Report*. The Internet Journal of Urology. 2008 Volume 6 Number 1.

Abstract

Numerous accounts of foreign objects, which sometimes defy imagination and include all types of objects, inserted into the urethra have been documented. The frequency of such cases renders these an important addition to the diseases of the genitourinary organs. Most cases are associated with psychiatric disorders, senility, intoxication, or autoerotic stimulation. Regardless of the motive for insertion, the extraction, can be challenging and requires creative deployment of the full armamentarium of the specialist. The techniques for the extraction include open, laparoscopic, and endoscopic surgery or a combination of these approaches. To the best of our knowledge, hardly is an option of expectance approach considered. We report a 49-year-old psychologically stable man, hospitalized for urethral foreign body that was expelled spontaneously.

INTRODUCTION

All manner of foreign bodies have been extracted from the urethra^{1,2,3,4,5,6,7,8,9,10}. Introduction into the urethra may be through self-insertion or iatrogenic means. The most common motive associated with the insertion of foreign bodies into the genitourinary tract is sexual or erotic in nature. In adults this is commonly caused by the insertion of objects used for masturbation and is frequently associated with mental health disorders¹⁰. Presentation could be acute or chronic symptoms due to complications which arose later. Extraction should be tailored according to the nature of the foreign body and should minimize urethral and/or bladder trauma. Complete extraction should also be confirmed by pan-endoscopy at the end of the extraction procedure in cases of multiple foreign bodies. The possibility of an expectant management protocol has never been explored.

CASE REPORT

A 49-year-old teacher presented to the emergency room with one-hour history of foreign body in the urethral. He claimed an office pin accidentally got inserted into his urethral while cleaning underneath his bed space and attempts at removing it failed. All effort at unraveling the mechanism of the injury yielded no additional information. No history to suggest assault.

Thereafter, he had painful micturition and tinge of blood stained urine. No known pre-morbid psycho-social illness.

He is married with four children and lives with his spouse. No preceding history suggestive of lower urinary tract symptoms. He drinks neither alcohol nor smoke cigarette. He has never been hospitalized and he is not a known hypertensive or diabetes patient. Drug history was uneventful.

Clinical finding revealed an anxious middle-age man, well kempt, and oriented in time place and person. The chest and cardiovascular findings were essentially normal. The perineum was tender but there was nothing palpable. There was neither evidence of bruising nor swelling noticed.

Plain radiographs of the perineum show a linear opacity of metallic density within the penile shaft (fig1&2), which confirmed the urethral foreign body. The results of biochemical and haematological work up were essentially normal.

Figure 1

Figure 1: plain pelvic radiography (AP) showing the foreign body (pin) in the bulbar urethra

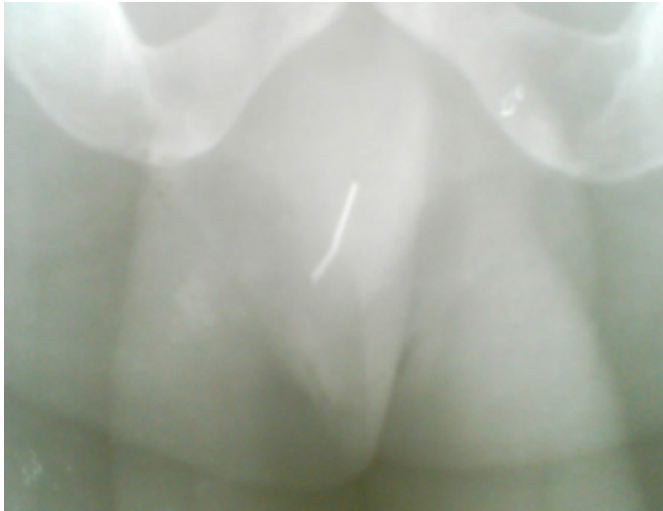

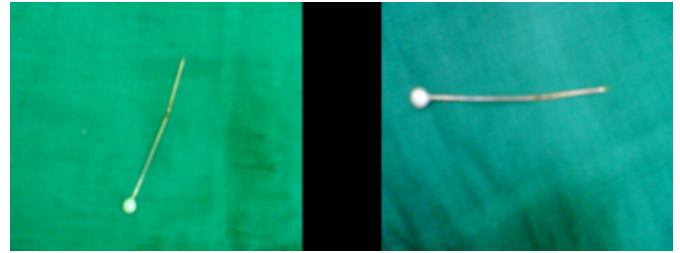
Figure 2

Figure 2: plain pelvic radiography (lateral) showing the foreign body (pin) in the bulbar urethra

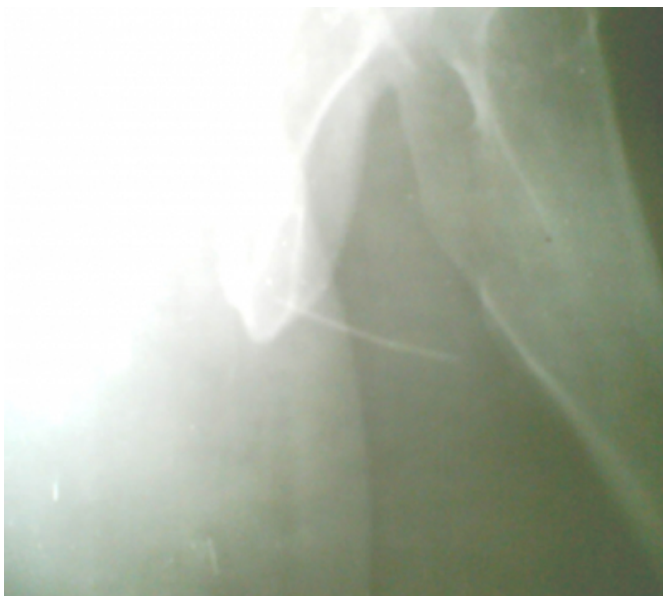

Figure 3

Figure 3: the photograph of the urethra foreign body after spontaneous expulsion



Patient was planned for endoscopic extraction, but had to be delayed because of numerous more emergent procedures. However, he spontaneously expelled the foreign body (an office pin) about 40 hours later (Fig. 3).

Further evaluation of the patient by psychiatrist confirmed him psychologically stable. A follow-up review at one year revealed no feature of bladder outlet obstruction.

DISCUSSION

Several cases of urethral foreign bodies have been documented in the literature, some defy imagination. The frequency of such cases renders these an important addition to the diseases of the genitourinary organs¹²³⁴⁵⁶⁷⁸⁹¹⁰.

There are multitudes of reasons for such insertion, which include psychiatric disorders, intoxication and masturbation¹⁸. No reason or explanation could be adduced to the present case being reported, which appear stranger than fiction. The patient accounts appear rather spurious and defied reasoning. His age and educational status (a teacher by profession) makes accidental urethral foreign body in him even more bizarre. The occurrence following molestation or assault appears very remote in this patient not only for lack of history but also for non-demonstration of bruise or other evidence of trauma. It is difficult to exclude auto-erotic intent, which the patient denied. However, the deep location of the inserted pin at the penobulbar region cannot be explained base on this.

Although Psychiatrist evaluation shows patient to be psychologically stable, the possibility of psychosexual disorder seems more likely.

The presentation of such patients could be either acute or late, whence complication has set-in. Such presentation may include lower urinary tract symptoms. The most common of which is frequency with dysuria, but there is sometimes gross haematuria and urinary retention¹²³⁴⁵⁶⁷⁸⁹¹⁰. The

presentation in our patient was consistent with the foregoing.

Diagnostic imaging techniques are quite important in evaluating these patients. Plain pelvic images were sufficient in most of the patients. The plain radiograph has an advantage of been simple, relatively available and easily repeatable. This is in addition to being able to determine the size, location and number of foreign bodies involved. However, radiolucent foreign bodies could be missed. The metallic density of the foreign body lodged in our patient urethral, makes plain radiograph sufficiently diagnostic. Thus, no further radiological work up was employed.

Ultrasonography, contrast urethrography or computed tomography may be needed in instances where plain radiograph is not diagnostic or for further evaluation of complication(s)¹¹¹².

Regardless of the motive for placement of these foreign bodies, their extrications can be challenging and may require the creative use of urologists' surgical and occasionally the interventional radiologists' armament in their removal¹³¹⁴¹⁵¹⁶¹⁷.

To the best knowledge of the present authors, attempt at expectant mode of management has never been considered in the management protocol before the often-invasive modes of treatment, which are not without complication, are instituted.

We are aware that conclusion may not be valid based on a single case report, but awareness can be generated. Probably, temporization of emergency procedure in cases of urethral foreign body where there is no obstructive symptom(s) or acute/severe haematuria could have yielded similar result with ours.

CONCLUSION

Urethral foreign body in men remains a grotesque oddity. Radiologic evaluation is paramount to its diagnosis and the simple plain radiograph remains a vital diagnostic tool. Although, spontaneous expulsion of the urethral foreign body in our patient occurred, albeit following inadvertent expectant management, it is probable that temporizing emergency intervention in selected stable cases especially in a resource-poor setting where open surgical extraction is usually employed may lead to spontaneous expulsion and less morbidity.

CORRESPONDENCE TO

Dr. AA Ajape P.O. Box 4850, GPO, Ilorin, Nigeria. E-mail: ajsnrkudimoh@yahoo.co.uk, ajsnrkudimoh@gmail.com

References

1. Gunay N, Isir AB, Yildirim C, Akieke M. A rare foreign body into the male penile urethra. *Saudi Med J*. 2006 May; 27(5):704-6.
2. Cury J, Coelho RF, Srougi M. Retroperitoneal migration of a self-inflicted ballpoint pen via the urethra. *Int Braz J Urol*. 2006 Mar-Apr;32(2):193-5.
3. Gokce G, Topsakal K, Ayan S, Kilicarslan H, Gokce SF, Gultekin EY. Case report: Nonobstructive giant urethral stone with two safety pins. *Int Urol Nephrol*. 2004; 36(1):65-6.
4. Sukkarieh T, Smaldone M, Shah B. Multiple foreign bodies in the anterior and posterior urethra. *Int Braz J Urol*. 2004 May-Jun; 30(3):219-20.
5. Chang AY, Koh CJ, Stein JP. Urethral foreign body management: a case report. *ScientificWorldJournal*. 2004 Jun 7; 4 Suppl 1:56-8.
6. Singla SL, Chitkara N, Sultania N. Impacted wire in the urethra. *J Indian Med Assoc*. 1997 Jun; 95(6):191.
7. Rajesh L, Kader A, B VB. Unusual foreign body in the male urethra. *Indian Pediatr*. 2000 Apr;37(4):450-2.
8. al-Durazi M, Saleem I, Mohammed AA. Urethral foreign body. *Br J Urol*. 1992 Apr; 69(4):434.
9. Ansari MS, Goel A, Hemal AK, Gupta NP. Open thumb forceps. An unusual foreign body in the urethra: technique of its removal. *Urol Int*. 2000;64(1):43-4.
10. Quin G, McCarthy G. Self insertion of urethral foreign bodies. *J Accid Emerg Med*. 2000 May; 17(3):231.
11. Barzilai M, Cohen I, Stein A. Sonographic detection of a foreign body in the urethra and urinary bladder. *Urol Int*. 2000; 64(3):178-80.
12. Noble JG, Chapple CR. Formation of a urethral calculus around an unusual foreign body. *Br J Urol*. 1993 Aug; 72(2):248-9.
13. Bird ET, Huckabay C, Waxman JA. Endoscopic evangelism: unique presentation and management of perforating urethral foreign body. *Urology*. 2004 Dec; 64(6):1229-30.
14. Al-Zahrani A, El-Darawani H, Al-Jehani YM, Moghazi K, El-Sadr A. Self-inflicted needle in the urethra retrieved endoscopically from the bladder. *Saudi Med J*. 2005 Dec; 26(12):2002-3.
15. Rahman NU, Elliott SP, McAninch JW. Self-inflicted male urethral foreign body insertion: endoscopic management and complications. *BJU Int*. 2004 Nov; 94(7):1051-3.
16. Johnin K, Kushima M, Koizumi S, Okada Y. Percutaneous transvesical retrieval of foreign bodies penetrating the urethra. *J Urol*. 1999 Mar;161(3):915-6.
17. Phillips JL. Fogarty catheter extraction of unusual urethral foreign bodies. *J Urol*. 1996 Apr; 155(4):1374-5.
18. Costa G, Di Tonno F, Capodiecici S, Laurini L, Casagrande R, Lavelli D. Self-introduction of foreign bodies into the urethra: a multidisciplinary problem. *Int Urol Nephrol*. 1993; 25(1):77-81.
19. Trehan RK, Haroon A, Memon S, Turner D. Successful removal of a telephone cable, a foreign body self-inserted through the urethra into the bladder: a case report. *J Med Case Reports*. 2007 Nov 27; 1(1):153.

Author Information

A.A. Ajape

Division of Urology, Department of Surgery, University of Ilorin Teaching Hospital

A.Y. Abdulkadir

Department of Radiology, University of Ilorin Teaching Hospital

A.L. Babata

Division of Urology, Department of Surgery, University of Ilorin Teaching Hospital

S.A. Kuranga

Division of Urology, Department of Surgery, University of Ilorin Teaching Hospital

O.A.M. Adesiyun

Department of Radiology, University of Ilorin Teaching Hospital