

Anterior Chamber Maintainer (ACM): A useful aid in small incision cataract surgery

P Sambarey, P Maithil., Y Vabale., S Bandhu, B Kambale., V Barhate.

Citation

P Sambarey, P Maithil., Y Vabale., S Bandhu, B Kambale., V Barhate.. *Anterior Chamber Maintainer (ACM): A useful aid in small incision cataract surgery*. The Internet Journal of Ophthalmology and Visual Science. 2009 Volume 7 Number 2.

Abstract

In order to promote the use of Anterior Chamber Maintainer (ACM), a prospective intervention study was carried out. The ACM was introduced in the anterior chamber at various steps of surgery in 82 patients. Sixty one patients underwent manual small incision cataract surgery (MSICS) and 21 patients phacoemulsification. Forty four males & 38 females were included in the study. Construction of sclero-corneal tunnel and aspiration of sub incisional cortex could be done with relative ease with the use of ACM. Thirty eight patients (46.34%) unaided and 56 patients (68.29%) aided with pinhole had V/A 20/60 or better (mode 20/30) on the first post operative day. Use of ACM leads to better cortical cleaning and lesser postoperative uveal inflammation. It was helpful even with phacoemulsification and during secondary surgeries.

ACKNOWLEDGEMENTS

The study was only possible because of the support and encouragement by the authorities and staff of Bhausaheb Sardesai Talegaon Rural Hospital (BSRTH) Talegaon (Dabhade).

INTRODUCTION

The use of Anterior Chamber Maintainer (ACM) maintains the integrity and internal pressure of the ocular chambers and thus prevents damage to vulnerable structures like corneal endothelium, iris and lens capsule during manipulation of the instruments.¹ A well maintained anterior chamber helps to achieve a capsulorhexis of optimal size and shape at the best possible location.² Aspiration of subincisional cortex too has always been a difficult task, especially in manual small incision cataract surgery (MSICS). The use of ACM and aspiration of cortex from side ports on either side considerably reduces the problem and associated inflammation. In addition it also facilitates construction of a good sclero-corneal tunnel and ensures in-the-bag placement of the intra ocular lens (IOL).

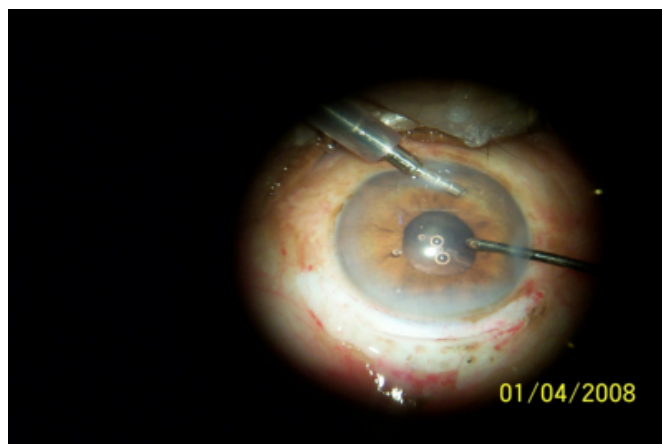
To ascertain the utility of ACM in different steps of both MSICS & phacoemulsification and to promote its use whenever necessary, a prospective intervention study of 82 patients undergoing small incision cataract surgery (SICS) was done at a rural hospital from April 2006 to Dec 2008, after approval from ethical committee. MSICS was done in

61 patients and phacoemulsification in 21 patients.

Technique: All surgeries were performed under peribulbar anesthesia. ACM was introduced at various steps of surgery. A corneal side port was made just near the limbus. A separate 1.5 mm corneal tunnel was made near 6O'clock position in the inferior temporal quadrant with the help of 20 gauge microvitrectomy (MVR) blade and ACM was introduced through it [Figure 1].

Figure 1

Figure 1: ACM near 6O'clock position & aspiration through the side port



Flow of ring lactate with preservative free adrenaline 0.3ml in 500cc was started once the ACM was in place. Capsular opening was made through the already created side

port with 26 gauge bent needle on a syringe in 15 patients without the use of viscoelastic. A sclerocorneal tunnel of approximately five to seven mm external frown/straight incision was made superiorly in a globe firmed with ACM. An additional side port was made in the same meridian as the first one but on the opposite side. Hydro-dissection and hydro-delineation were performed. Bottle height was lowered and the nucleus was prolapsed in the anterior chamber (AC). Nucleus delivery was done by hydrodynamic expression by increasing the height of the bottle. Sometimes viscoelastic (Hydroxypropyl methylcellulose (HPMC) 2%) was needed for protection of corneal endothelium during nucleus delivery. Aspiration of cortex was done with the help of a cannula with silicone tubing attached to a five milliliter (ml) disposable syringe through the side port on either side in a closed, well-maintained AC provided by the ACM. A 6 to 6.5 mm optical diameter rigid polymethylmethacrylate (PMMA) posterior chamber IOL (PCIOL) was implanted. The ACM was withdrawn without stopping the irrigation so that the wound of entry was hydrated. The two side ports too were hydrated. Fornix based conjunctival flap was repositioned in its place and cauterized.

In 39 cases, capsulorrhexis was performed after injection of viscoelastic in the anterior chamber. ACM was then introduced, followed by construction of the tunnel and all other steps.

ACM was used only for subincisional cortical aspiration after nucleus delivery in 26 patients.

In four patients (two undergoing MSICS & the other two phacoemulsification), only cortical cleanup was done using ACM along with aspiration cannula- attached to the syringe, each in one side port after the placement of PCIOL.

In one patient having previously introduced anterior chamber IOL (ACIOL) and the other one having anterior displacement of PCIOL, ACM was only used for removing the cortex during re-operations after a week. In both these cases ACM was positioned in the side port and another side port as made to aspirate the cortex..

All patients were examined on the next day. The subsequent follow up examinations were done after one week and four to six weeks after surgery.

RESULTS

There were 44 males & 38 females. The age range was 35

yrs to 87 yrs (mean age 60.95 yrs, standard deviation 10.29) [Table1].

Figure 2

Table1: Age & Sex distribution

Age	No. of Males	No. of Females
35-45 yrs	02	05
46-55 yrs	06	10
56-65 yrs	20	15
66-75 yrs	11	08
76-85 yrs	03	-
>85 yrs	02	

Various problems encountered are shown in Table2.

Figure 3

Table2: Problems & Complications

PROBLEMS	NO.OF PATIENTS
Stripping of Descemet's membrane	2
Constriction of pupil	7
Difficult nucleus prolapse	4
Zonulodialysis	2
Nucleus drop	1
Iridodialysis	2
Posterior capsular rent	1
Difficult cortical aspiration	26
Difficult nucleus delivery	3
Uveitis	3
Corneal oedema	12
Posterior capsular opacification	2

ACIOL was implanted in five patients. Thirty eight patients (46.34%) unaided and 56 patients (68.29%) aided with pinhole had V/A 20/60 or better (mode 20/30) on first post operative day. The anterior chamber reaction observed on the next day of operation was 1+ to 2+ flare & cells in all except five patients who either had constricted pupil and floppy iris or difficult nucleus maneuvering where the cells and flare were 4+. Twelve patients having corneal edema either had stripping of the Descemet's membrane at the site of ACM entry, or had a problem with bringing the nucleus in the anterior chamber (seven cases with intra operative miosis) or out of the eye.

Only 51(62.19%) patients reported after 4-6 weeks. The best corrected V/A (BCVA) was 20/60 or better in 39(76.47%) patients. There was astigmatism against the rule in all the patients. The cylindrical power required was between -0.25D to -3.00 D (mode -1.00D), with the axis between 80° to 120°. Refraction was not done in two of these patients because of corneal edema and in the other three patients having ACIOL due to vitreous haze. In 12 patients the BCVA was less than 20/60. Table 3 enlists the causes for decreased vision.

Figure 4

Table3: Causes of V/A < 20/60 after 4-6 wks

CAUSES	NO.OF PATIENTS
Corneal oedema	2
Vitreous haze	3
Retinal detachment	1
Macular degeneration	4
Optic atrophy	1
Amblyopia	1

The patient with nucleus drop was left aphakic after vitrectomy and nucleus removal as he had silicone oil after surgery for giant retinal tear. Silicone oil was removed five months later and ACIOL implanted. The patient improved to BCVA 20/60.

Acquired macular degeneration (AMD) was present in four patients. One person had pseudoexfoliation with

glaucomatous optic nerve damage and another had amblyopia.

Two patients reported one year after surgery with decrease in vision due to posterior capsular opacification (PCO) after YAG capsulotomy BCVA was 20/30.

DISCUSSION

The main advantage of ACM was facilitation of the aspiration of subincisional cortex (22 MSICS & four phacoemulsification). The operating surgeon had tried to use various designs of simultaneous irrigation and aspiration (I&A) cannulae for the purpose in the past, but the use of ACM and aspiration through the side ports on either side worked like bimanual automated I&A system. Use of ACM helped during phacoemulsification when the mechanized I&A system failed. Anterior chamber reaction was very much less with the use of ACM. No patient in our study had cystoid macular edema. The use of ACM did not contribute to most of the reported complications as these are established complications of MSICS.³

Ravi Thomas describes MSICS as a low cost, equally effective alternative technique, as phacoemulsification is not always possible in our unequally developed country.⁴

The use of ACM makes it more advantageous. Blumenthal in 1987 first developed, promoted and recommended the use of ACM.^{5,6} To start with, the operating surgeon was hesitant to perform anterior capsular opening without the use of viscoelastic in the anterior chamber, but with practice it was possible to perform a good capsulorrhexis under positive pressure achieved by the ACM. Harinder S Sethi et al have used irrigation hand-piece of bimanual I/A system to achieve good capsulorrhexis during phacoemulsification. It maintained the depth of the anterior chamber somewhat similar to the use of ACM.⁷

Krishan PS Malik & Ruchi Goel suggested filling the anterior chamber with viscoelastic before capsulorrhexis and nucleus prolapse in the anterior chamber in MSICS using ACM. They recommend closure of ACM when viscoelastic was injected in the anterior chamber.⁵ It was difficult for us to prolapse the nucleus in the anterior chamber with high anterior chamber pressure, so the pressure was decreased by lowering the bottle height. Sometimes ACM was blocked by the viscoelastic injected in the anterior chamber. There occurred one posterior capsular rent while aspirating when the ACM was blocked by the viscoelastic resulting in collapse of anterior chamber. Blumenthal used Sheet's glide

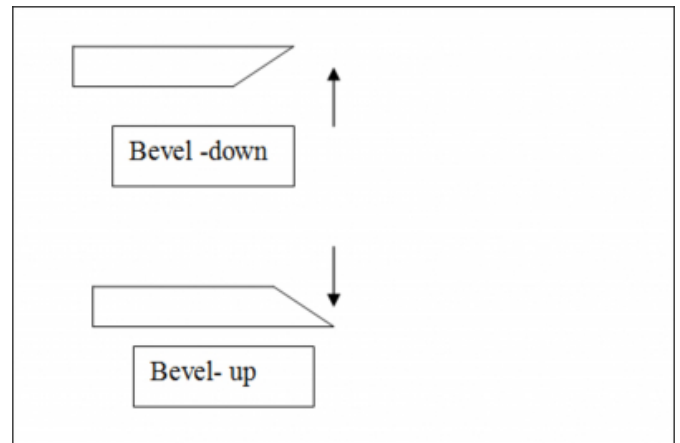
during nucleus delivery.¹⁸ In our series, the visco- cannula was used to engage the nucleus in the tunnel and depress the posterior lip of the incision. The viscoelastic was injected only when needed to build up pressure inside the anterior chamber in order to propel out the nucleus. Mark Wright et al have used ACM without the use of viscoelastics. They found visual outcome comparable to the other techniques, but recommend the use as there was more endothelial cell damage when no viscoelastic was used.⁹

The misdirected flow through ACM caused iris prolapse and iridodialysis in two patients. Nikhil Gokhale too mentions the need for adequate care during the step.¹⁰ In one case iridodialysis was sutured with Mc Cannel suture.³

Difficult and prolonged nucleus expression was the main cause of corneal edema in our series. Parikshit Gogate has reported endothelial cell damage during the MSICS procedure.¹¹ The stripping of Descemet's membrane was due to placement of ACM in the corneal canal instead of anterior chamber and intra lamellar injection of fluid.³ The use of blunt MVR blade was responsible for improper construction of entry wound and stripping of the Descemet's membrane.¹² Though not related to the use of ACM, there was astigmatism against the rule in all the patients who came for follow up four to six weeks after surgery. Haldipurkar recommends centering the incision on the steepest meridian to decrease induced astigmatism.¹² Gokhale found less astigmatism in superotemporal or temporal incisions as the site was away from visual axis and there was lesser drag by gravity and blink than in the case of superiorly placed incision.¹¹ Paul Koch explains the use of bevel up blade for dissection of tunnel and bevel down blade for extension of inner opening sideways as the bevel up keratome would lead to extension of the cut deeper towards the scleral spur due to the tendency to sinkcompromising the function of corneal valve.¹³ [Figure 2]

Figure 5

Figure: 2 Effects of bevel down & bevel up blades



The use of bevel up blades even for sideways extension of corneal cut has contributed to the astigmatism in the present study. Moreover induced astigmatism was not considered in our study.

In a patient with phacodonesis, the brown nucleus dropped in the vitreous after striking against the tip of the ACM while it was being prolapsed in the anterior chamber. There were in all five patients in our study having ACIOL. In one of the patients, the ACM was used only during second operation to maintain the anterior chamber during cortical aspiration with already implanted ACIOL as a primary procedure. We had to abandon the use of ACM in two patients having zonulodialysis and one patient having posterior capsular rent. Thomas R et al have described the presence of ACM when there is posterior capsular rent as a double-edged sword. It can facilitate removal of the vitreous but at the same time can extend the rent and push the cortex and epinucleus into the vitreous when the bottle height is not lowered as soon as the tear occurs.¹

According to Ravi Thomas, the use of ACM decreases the chances of endophthalmitis because of the continuous egress of fluid outside, implying a lesser chance of contamination.² The authors too agree, but with a word of caution as in one of the patients a small piece of thread was observed to be lodged in the ACM port the next day. It probably went inside with the ACM from the sterile linen on the instrument trolley.

CONCLUSION

The use of ACM is helpful in MSICS in all steps. Aspiration of subincisional cortex is especially facilitated. It helps in phacoemulsification where chances of sudden fluctuations in

intra-ocular pressure are high and when automated I&A fails. Less quantity of viscoelastic required during surgery reduces the cost. It also aids cortical aspiration in secondary surgeries with ACIOL in place or with anterior displacement of PCIOL.

References

1. Thomas R, Kuriakose T, George R. Towards achieving small-incision cataract surgery 99.8% of time. *Indian J Ophthalmol* 2000; 48:145-51.
2. Lucio Buratto, MD. Anterior Capsulotomy. Lucio Buratto Phacoemulsification: Principles and techniques., Thorafare, NJ 08086-9447 USA, SLACK Incorporated 1998 Pages 49-63.
3. Dr. G. Natchiar. Complications of Manual Small Incision Cataract Surgery and their Management. Dr. G. Natchiar. Manual Small Incision Cataract Surgery an alternative technique to instrumental phacoemulsification. Aravind Eye Hospital & Postgraduate Institute of Ophthalmology Madurai, India. Aravind Publications December 2000. Pages 35-42.
4. Ravi Thomas Role of small incision cataract surgery in the Indian scenario. *Indian J Ophthalmol* 2009; 57:1 1-2.
5. Krishan PS Malik, Ruchi Goel. Nucleus management with Blumenthal technique: Anterior chamber maintainer. *Indian J Ophthalmol* 2009; 57:1 23-25.
6. Blumenthal M, Moilssiew J. Anterior chamber maintainer for extracapsular cataract extraction and intraocular lens implantation. *J Cataract Refract Surg* 1987; 13:204-6.
7. Harinder S Sethi, Tanuj Dada, Harminder K Rai and Prabhpreet Sethi. Closed chamber globe stabilization and needle capsulorhexis using irrigation hand piece of bimanual irrigation and aspiration system. *BMC Ophthalmology* 2005; 5:21
8. Blumenthal M, Askenazi I, Fogel R, Assia E I. The gliding nucleus. *J Cataract Refract Surg* 1993; 19: 435-37
9. Mark Wright, Hector Chawla, Alistair Adams. Results of small incision extracapsular cataract surgery using the anterior chamber maintainer without viscoelastic. *Br J Ophthalmol* 1999(January; 83: 71-75
10. Nikhil S Gokhale. Viscoexpression technique in manual small incision cataract surgery *Indian J Ophthalmol* 2009; 57: 39-40.
11. Parikshit M Gogate. Small- incision cataract surgery: Complications & mini-Review. *Indian J Ophthalmol* 2009; 57:1 45-49.
12. S.S.Haldipurkar, Hasanian. T Shikari, Vishwanath Gokhale Wound construction in manual small incision cataract surgery. *Indian J Ophthalmol* 2009; 57: 9-13
13. Paul S.Koch. Incisions. Paul S.Koch. Mastering phacoemulsification. A Simplified Manual of Strategies for Spring, Crack and Stop & Chop Technique. 4 th ed, First Indian Edition 1995. Published by Jaypee Brothers Medical Publishers, New Delhi, INDIA 110002, Pages 7-44.

Author Information

Prajakta P Sambarey, MS

Professor& Head, Department of Ophthalmology

Preeti Maithil., DNB

Lecturer

Yogendra G Vabale., MS.

Associate Professor

Seema Bandhu, MD.

Lecturer

Bhamini S Kambale., DOMS.

Senior Resident

Vibhavari R Barhate., DOMS.

Junior Resident