

Signal Intensity Of Cerebrospinal Fluid On MR Images Indicates The Severity Of Degenerative Lumbar Spinal Canal Stenosis

T Sakamaki, H Mikami, Y Okada, T Tamura, K Shinohara, T Mishiro, K Sairyo

Citation

T Sakamaki, H Mikami, Y Okada, T Tamura, K Shinohara, T Mishiro, K Sairyo. *Signal Intensity Of Cerebrospinal Fluid On MR Images Indicates The Severity Of Degenerative Lumbar Spinal Canal Stenosis*. The Internet Journal of Spine Surgery. 2004 Volume 1 Number 2.

Abstract

Conservative management is unlikely to be effective in patients with degenerative lumbar spinal canal stenosis (LSCS), when stenosis is severe. In this study, we investigated the significance of the signal intensity of cerebrospinal fluid (CSF) on MRI with respect to the severity of stenosis. Twenty LSCS patients were reviewed. They all showed single level stenosis, and patients showing multiple stenosis were excluded. The severity of stenosis was evaluated by myelograms, and they were divided into two groups based on the severity on the myelograms. Ten were in complete block (CB) and 10 in incomplete block (IB). On MR T2-weighted images, we measured the signal intensity of CSF at both the cranial and caudal side from the stenotic level; then the signal intensity ratio (SIR) was calculated as the relative value of cranial CSF compared to caudal side. In results, SIR was 1.26 ± 0.16 in CB group, and 0.96 ± 0.14 in IB group. There was a significant difference between the two groups ($p < 0.05$; unpaired t-test). In this analysis using NIH image software, high number indicated low signal intensity on MRI. This result indicated the CSF in the IB group showed similar signal intensities at both the cranial and caudal side; whereas, in the CB group, the CSF showed higher signal intensity (brighter) on MRI at the caudal side compared to that at the cranial side. In other words, when CSF at the caudal side shows higher signal intensity on T2-MR images compared to the cranial side, the spinal canal stenosis is severe and shows complete block on myelograms.

INTRODUCTION

The natural history of degenerative lumbar spinal canal stenosis is not completely understood, thus, the timing for surgery has not been clearly decided. It was stated in a text book (MacNab's Low Back Pain) that conservative management is unlikely to be effective in patients with lumbar spinal canal stenosis (LSCS) when stenosis is severe.⁵ Postacchini^{9, 10} reached the similar conclusion, since among most patients with severe central lumbar stenosis, symptoms tend to remain unchanged or to worsen with the natural course. He also noted most patients with severe spinal canal stenosis shows temporary relief after conservative treatment. Although controversy still exists concerning the effects of severity of stenosis on the surgical outcomes, some reports concluded that better results were obtained in patients with mild stenosis,^{7, 12} and supported the MacNab's and Postacchini's statements. Therefore, it is very important to understand its severity for deciding surgical indication.

The severity of stenosis is usually evaluated by myelograms. Although MRIs can be taken less invasively and provide valuable information, the images are not suitable to evaluate the severity of stenosis. Especially, to understand very severe stenosis such as complete block on myelograms, MRI can not show appropriate information. MRI is the least invasive diagnostic tool, and is good for screening for understanding spine related disorders. Thus, it is very important to establish methods to evaluate its severity using less invasive MR images. In this study, we investigated the significance of the signal intensity of cerebrospinal fluid (CSF) regarding the severity of stenosis.

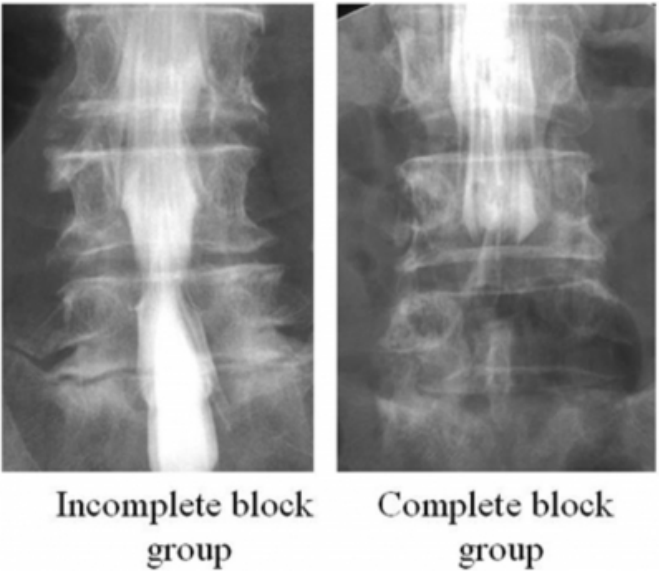
METHODS

Patients: Twenty LSCS patients were reviewed. Included were 9 men and 11 women. Their mean age was 71.6 years old (range: 62 to 86). They all showed single level stenosis, and patients showing multiple stenosis were excluded. The severity of stenosis was evaluated by myelograms, and they were divided into two groups based on the severity on the

myelograms (Figure 1);

Figure 1

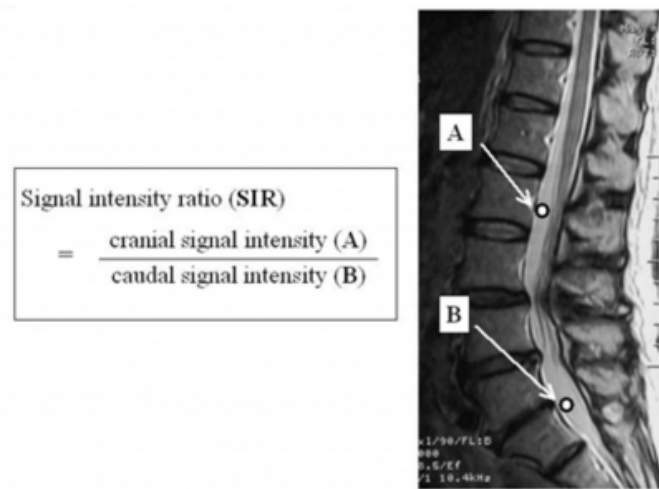
Figure 1: Myelograms for incomplete and complete block group 10 were in complete block (CB) and 10, in incomplete block (IB) group.



MRI measurement: For all patients, routine T1 and T2 MRIs were taken. On mid-sagittal MR T2-weighted images (TR: 3000 msec, TE 120 msec), the region of interest at both the cranial and caudal side from the stenotic level were observed. Figure 2 indicates the region of interests on MRI.

Figure 2

Figure 2: Location of region of interests for measurement of signal intensity and equation for calculating signal intensity ratio



The picture was scanned and installed into the personal computer. NIH image software was used to measure signal intensity. In this software, brighter images correspond to low

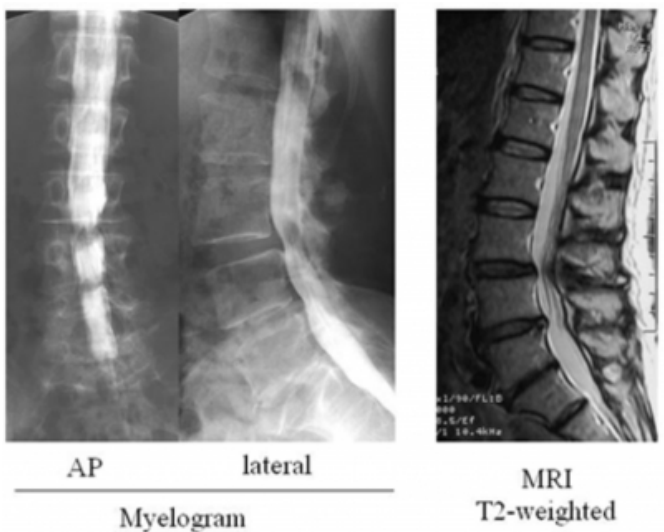
values. The signal intensity ratio (SIR) was calculated as the relative value of cranial CSF compared to caudal side. The MRI system used in this study was GE Signa MRI equipment with 1.0 Tesla magnetic field.

RESULTS

The SIR was 1.26 +/- 0.16 in the CB group, and 0.96 +/- 0.14 in the IB group. There was a significant difference between the two groups (p<0.05; unpaired t-test). In this imaging analysis using NIH image software, high number indicated low signal intensity. The results indicated the CSF in the IB group showed similar signal intensities at both the cranial and caudal side; whereas, in the CB group, the CSF showed higher signal (brighter) intensity at the caudal side compared to that at the cranial side. Figure 3 demonstrated an example in the IB group.

Figure 3

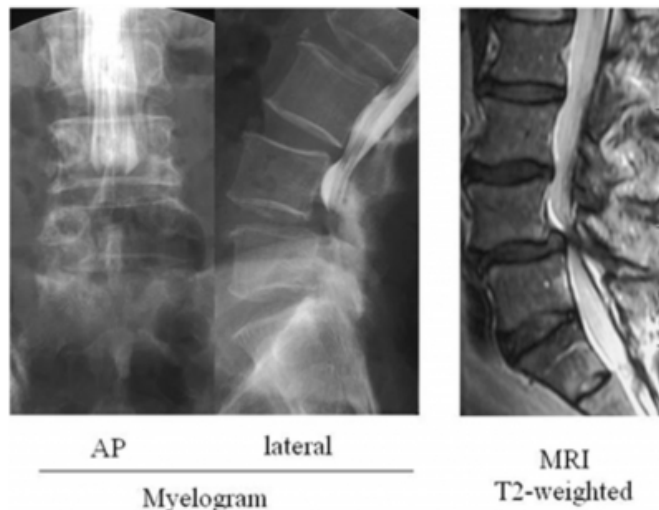
Figure 3: A case in the IB group (64 years old female). Lumbar spinal canal stenosis is seen at L3/4. The signal intensity of CSF at L2/3 and L5/S showed similar number. The SIR was 1.08.



This patient is 64 years old female and shows lumbar spinal canal stenosis at L3/4. According to a finding on myelogram, she was categorized in IB group. The signal intensity of CSF at L2/3 and L5/S showed similar number. The SIR was 1.08. In figure 4, myelogram and MRI are shown of 65 years old female patient.

Figure 4

Figure 4: A case in the CB group (65 years old female). Lumbar spinal canal stenosis is seen at L4/5. The signal intensity of CSF at L5/s was smaller than that at L2/3, indicating the CSF at L5/s was brighter than that at L2/3. The SIR on MRI is calculated as 1.46.



The myelogram indicates the complete block at L4/5. The signal intensity of CSF at L5/s was smaller than that at L2/3, indicating the CSF at L5/s was brighter than that at L2/3. The SIR on MRI is calculated as 1.46.

DISCUSSION

As for the treatment of the degenerative lumbar spinal canal stenosis, surgical treatment seems to be recommended when the conffiction of spinal canal is severe, because conservative treatment is unlikely to be effective.^{5,9, 10} Also, surgical outcome was reported not to be favorable for patients with severe canal stenosis.^{9, 10, 12} Surin et al.¹² reviewed 22 patients and found that leg pain in all patients with moderate stenosis recovered; whereas, leg pain in 20% of patients with marked spinal stenosis did not heal well. Thus, it is very important to understand how severely constricted the spinal canal was when surgical intervention was considered. In this study, we clarified that the signal intensity of CSF on T2-weighted MR images can indicate the severity of the constriction of canal. When CSF at the caudal side from the stenotic level showed higher intensity (brighter) than that at the cranial level, the constriction of the canal is severe and may show complete block on a myelogram. On the other hand, when the signal intensities at both areas were similar, the stenosis is mild. In other words, it is suggested that when the CSF at the caudal side is brighter, conservative treatment may not be effective, because the stenosis is very marked.

The cerebrospinal fluid (CSF) always flows and it shows pulsation in its velocity due to a respiration or a heartbeat.^{1, 3, 4, 8} Bankhof et al.¹ measured CSF flow at aqueductal on cine-phase-contrast MR imaging. The average peak velocity in rostral direction was 4.2 cm/sec, and 7.8 cm/sec in caudal direction. Friese et al.⁴ measured CSF flow velocity using echo planner imaging and found respiration affected the velocity. Velocity increased by 28% at Th12 level due to respiration. Thus, it is suggested that the flow of the CSF can affect the signal intensity because of the flow void phenomenon.^{2, 6, 11} Within fluid collections not communicating with the physiological CSF space, signal loss on T2-weighted MR images is considered not to occur because of no flow void effects there.^{2,11}

The present study applied this concept to understand severity of degenerative lumbar spinal canal stenosis. The present results were in good agreement with this concept. Similarly, Sherman et al.¹¹ used this concept for diagnosing the communication of CSF within the syrinx cavity of the spinal cord. They examined 24 patients with syringomyelia and found flow void effects in 40% of them. They concluded that the syrinx with flow void effects would have a pulsation movement in the syrinx. Also, Brooks et al.² observed the signal intensity of three isolated arachnoid cysts on MRI to know the communication between the cyst and CSF. They found signal loss in all cysts maybe due to flow void, and concluded that there was a communication between them.

In conclusion, when CSF at the caudal side shows higher signal intensity on T2-MR images compared to the cranial side, the spinal canal stenosis is severe and shows complete block on myelograms.

ACKNOWLEDGEMENT

The authors wish to thank Mr. Ian Cowgill, Spine Research Center, Department of Bioengineering, University of Toledo, Toledo, Ohio for his help during editing process.

CORRESPONDENCE TO

Koichi Sairyo, MD., PhD. Spine Research Center, 5040 Nitschke Hall, Department of Bioengineering, University of Toledo, Toledo, Ohio 43606 TEL: 1-419-530-8030 FAX: 1-419-530-8076 Email: sairyokun@hotmail.com

References

1. Barkhof F, Kouwenhoven M, Scheltens P, Sprenger M, Algra P, Valk J. Phase-contrast cine MR imaging of normal aqueductal CSF flow. Effect of aging and relation to CSF void on modulus MR. *Acta Radiol.* 1994; 35 (2): 123-30.

2. Brooks ML, Jolesz FA, Patz S. MRI of pulsatile CSF motion within arachnoid cysts. *Magn Reson Imaging*. 1988; 6(5): 575-84.
3. Freund M, Adwan M, Kooijman H, Heiland S, Thomsen M, Hahnel S, Jensen K, Gerner HJ, Sartor K. Measurement of CSF flow in the spinal canal using MRI with an optimized MRI protocol: experimental and clinical studies. *Rofo*. 2001; 173 (4): 306-14.
4. Friese S, Hamhaber U, Erb M, Kueker W, Klose U. The influence of pulse and respiration on spinal cerebrospinal fluid pulsation. *Invest Radiol*. 2004; 39 (2): 120-30.
5. McCulloch J, Transfeldt E. *MacNab's Backache*. 1999. Williams & Wilkins, Baltimore, PP 538- 586
6. Ohara S, Matsumoto T, Nagai H, Banno T. Observation of CSF pulsatile flow in MRI--the signal void phenomenon. *No To Shinkei*. 1987; 39 (10): 991-6.
7. Paine KW. Results of decompression for lumbar spinal stenosis. *Clin Orthop*. 1976; 115: 96-100.
8. Panigrahi M, Reddy BP, Reddy AK, Reddy JJ. CSF flow study in Chiari I malformation. *Childs Nerv Syst*. 2004; 20 (5): 336-40.
9. Postacchini F. Long-term results. Lumbar spinal canal stenosis. In *The Lumbar Spine second edition Volume 2*. Edited by International Society for the study of the lumbar spine. W.B. Saunders Company. Philadelphia 1996, pp 766-781
10. Postacchini F. Surgical management of lumbar spinal stenosis. *Spine*. 1999; 24 (10): 1043-7.
11. Sherman JL, Barkovich AJ, Citrin CM. The MR appearance of syringomyelia: new observations. *AJR Am J Roentgenol*. 1987; 148 (2): 381-91.
12. Surin V, Hedelin E, Smith L. Degenerative lumbar spinal stenosis: results of operative treatment. *Acta Orthop Scand*. 1982; 53 (1): 79-85.

Author Information

Tadanori Sakamaki

Department of Orthopedic Surgery, Oe-kyodo Hospital

Hiroshi Mikami

Department of Orthopedic Surgery, Oe-kyodo Hospital

Yuji Okada

Department of Orthopedic Surgery, Oe-kyodo Hospital

Tatsuya Tamura

Department of Orthopedic Surgery, Oe-kyodo Hospital

Kazuhito Shinohara

Department of Orthopedic Surgery, Kochi National Hospital

Takuya Mishiro

Department of Orthopedic Surgery, Kochi National Hospital

Koichi Sairyo

Department of Bioengineering, Spine Research Center, University of Toledo