

Osteoporotic Unstable Scoliosis In Lumbar Spine Associated With Progressive Hemi-Vertebral Compression Fractures Following Long -Term Glucocortisone Therapy

T Iizuka, S Yamada

Citation

T Iizuka, S Yamada. *Osteoporotic Unstable Scoliosis In Lumbar Spine Associated With Progressive Hemi-Vertebral Compression Fractures Following Long -Term Glucocortisone Therapy*. The Internet Journal of Spine Surgery. 2006 Volume 3 Number 1.

Abstract

We report a complication caused by progressive hemi-vertebral compression fractures associated with steroid induced osteoporosis. Loss of spinal balance would accelerate the progressive compression fractures because of the fragility of spinal column. It is important to reconstruct the spinal alignment and to medicate the osteoporosis itself.

INTRODUCTION

The loss of spinal balance causes the progression compression fractures in osteoporotic patients^(1,2,3,4). The surgical goal is not only the relief of the present complains, but also the prevention of the further complications after the surgical intervention. The careful surgical strategies must be made for the reconstruction of the spinal alignment and for the fragile vertebrae because of osteoporosis with medications.

progressed with L3 left hemi-vertebral fracture.

CASE REPORT

A sixty-four-year-old woman, who were medicated with prednisolone 10mg/day for nineteen years without treatment of osteoporosis because of AIHA (autoimmune hemolytic anemia), presented persistent left anterior thigh pain and sever low back pain. The first episode of acute low back pain occurred at 58 years old when fell on the floor. Lumbar scoliosis with left side vertebral fractures of L1 and L2 was demonstrated on x-ray examination (Fig.1a) and she was observed with NSAIDs conservatively and settled the clinical symptoms, but the subsequent discomfort and dull pain on the back were persistent.

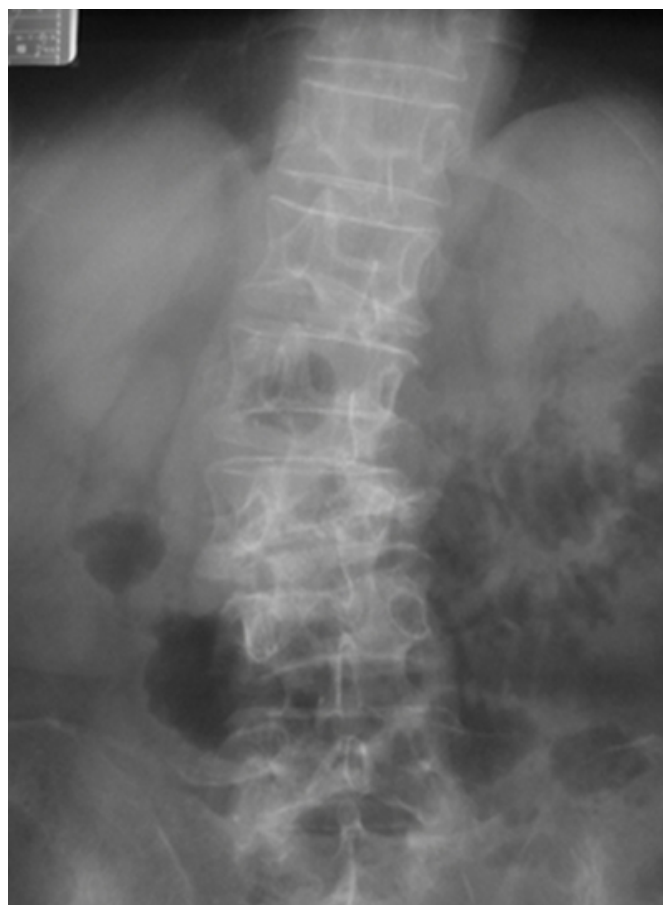
She presented, however, sever low back pain again and radiating pain in the left anterior thigh at 64 years old. On physical examination, she could not stand with one leg because of sever low back pain, and neurologically femoral nerve stretching test was positive in the left lower extremity. The lumbar scoliosis on the X-ray examination (Fig.1b) was

Figure 1

Figure 1: a. Vertebral compression fractures of L1 and L2, Cobb's angle 6 degree(L1-L3) at 58 y.o. b. X-ray examination showed progressive hemi-vertebral compression fracture on the left side and scoliosis. Cobb's angle was 18 degree(L1-L4).

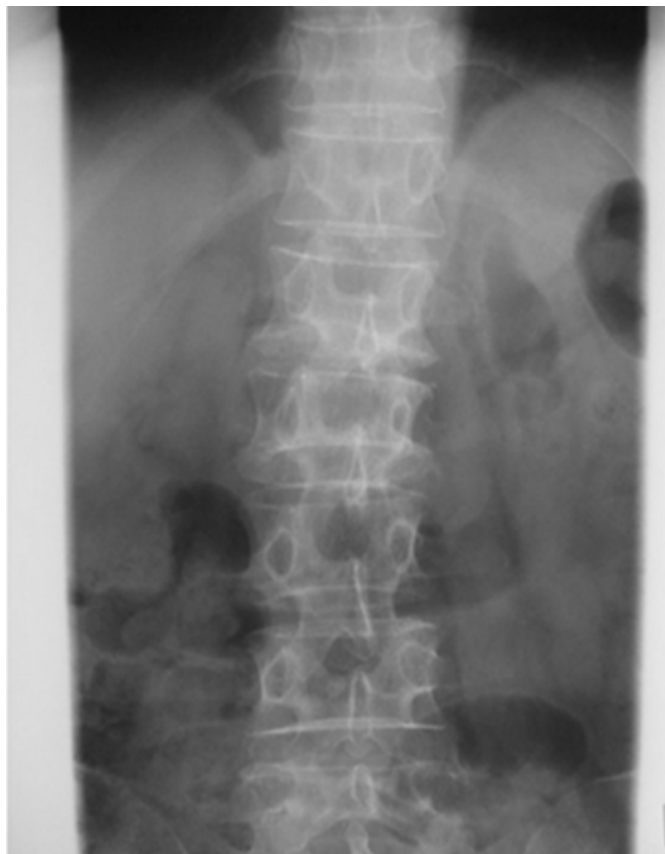

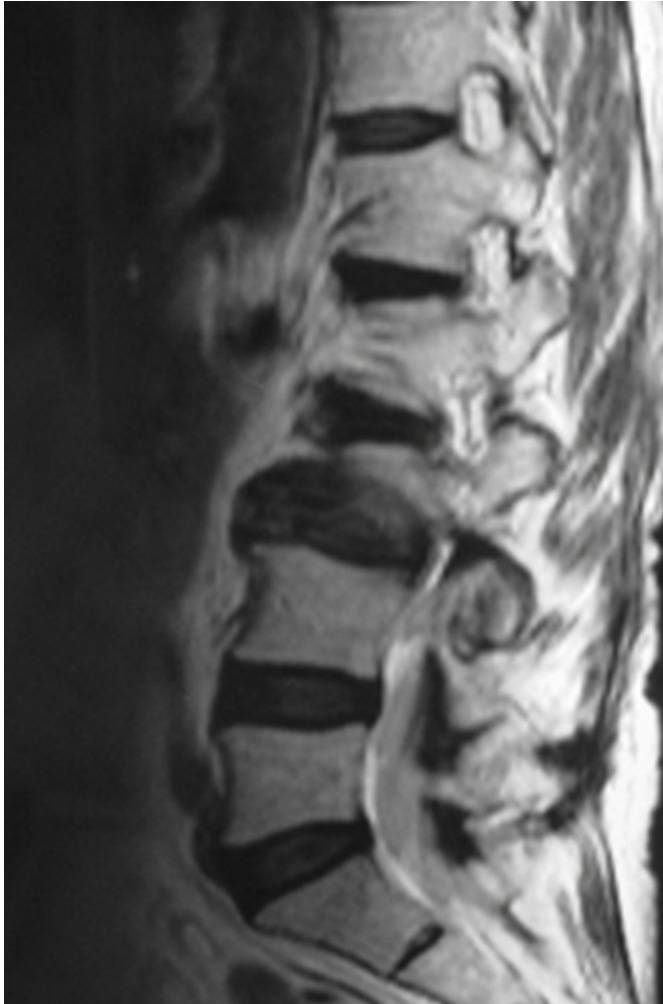Figure 2



Cobb's angle progressed 6 to 18 degree in coronal plane. Magnetic resonance imaging showed a foraminal stenosis caused with disc material and the deformity of vertebral body at L3/4 in para-sagittal section (Fig.2).

Figure 3

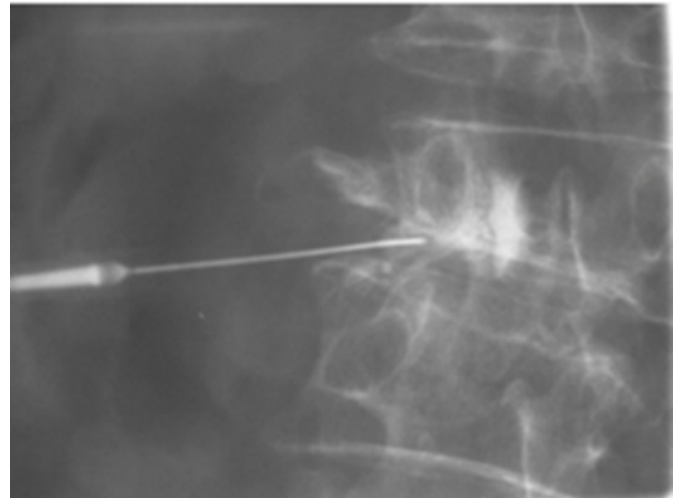
Figure 2: a. MRI(T2w.i.) showed the L1,2 and L3 vertebral fractures and kyphotic deformity of the spinal alignment. b. Foraminal stenosis of L3/4 on right para-sagittal section. c. left foraminal stenosis on axial view.



Myelography and radiculography revealed the left L3 nerve root entrapment at L2/3 (Fig.3).

Figure 4

Figure 3: L3 radiculography showed the entrapment of L3 nerve root at pedicle. The radicular pain was relieved after infection of 1.0 ml xylocaine.



Epidural block therapy was less effective. The posterior vertebral osteotomy and interbody fusion, therefore, was performed with polyaxial screws and with additional laminar hooks. The scoliosis was corrected completely in surgical procedure. Cobb's angle was corrected from 18 to 0 degree without loss of correction on the following X-ray examinations (Fig.4).

Figure 5

Figure 4: Posterior correction osteotomy and interbody fusion with polyaxial pedicle screws and laminar hooks (Moss Miami, DePuy AcroMed) was performed . Pedicle screws were enhance by hydroxyapatite granule (HA) sticks. The HA were shown as a soft shadow around screws. The deformity was corrected completely.

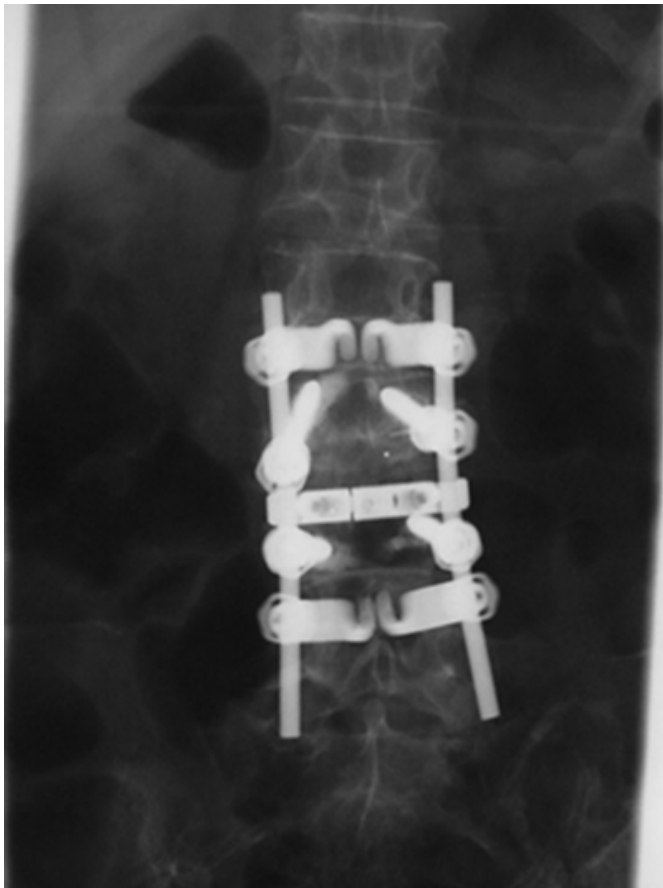
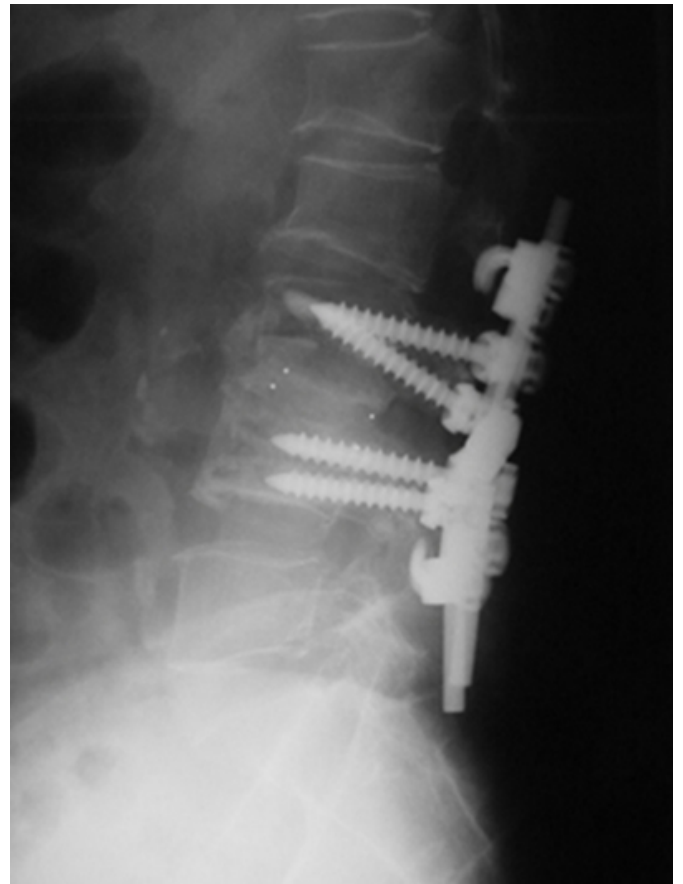


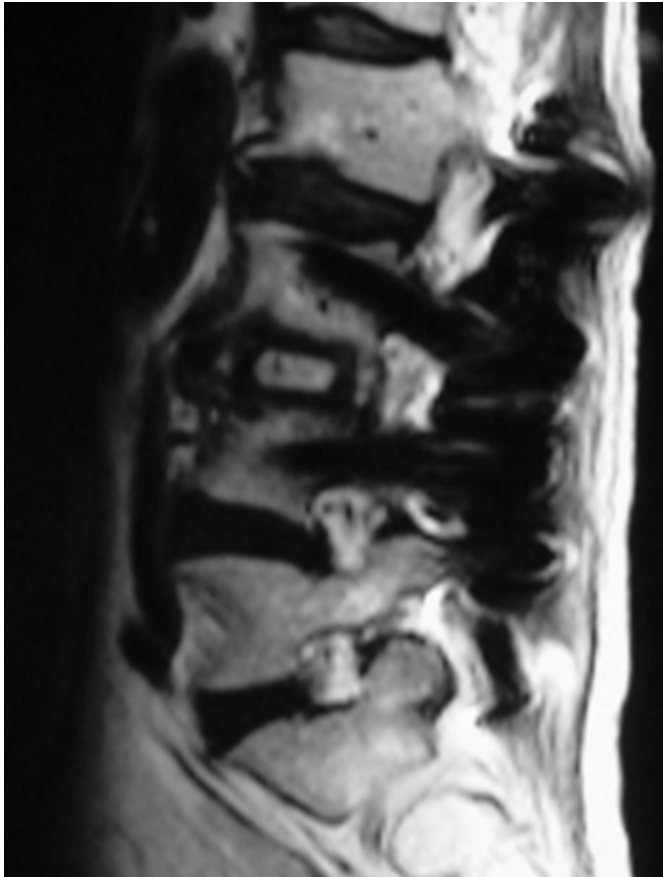
Figure 6



MRI examination after operation also showed the complete decompression of dura and nerve roots and the adequate anterior reconstruction with bone grafts and spacers (Fig.5).

Figure 7

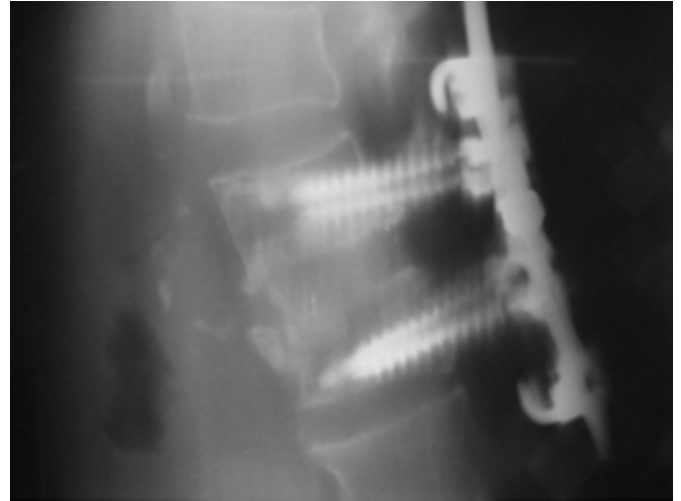
Figure 5: a. Post-operative MRI on sagittal view showed the bone grafts and interbody cage(Brantigan's carbone I/F cage) between L3 and L4. b. The dural sac was decompressed and the nerve roots in the dura are located in the center of the spinal canal.



Tomography revealed the satisfactory bony fusion in anterior column (Fig.6) at six months after the operation.

Figure 8

Figure 6: a.Tomography,which is taken at six months after surgery, shows the complete bony fusion in L3/4. b.No sinking of grafted bone and interbody cages was observed on the tomography.



The severer low back pain and radiating pain in the left thigh were relieved completely at two years after surgery. And no compression fractures are encountered.

DISCUSSION

Spinal compression fractures are very common (5) in postmenopausal women and also in the patients who take long-term glucocortisone therapy because of osteoporosis (6,7,8,9). And compression fractures in osteoporotic spine usually progress in adjacent vertebrae because of imbalance of spinal alignment (1,2,3,4). Fractures are not a well-recognized cause of scoliosis (10). However, compression fractures with more than 30 degrees of kyphosis or more than a 30 per cent loss in height have the potential for increasing late deformity(10,11). We experienced the rare case with L3 radicular pain in the anterior thigh associated with lumbar scoliosis caused by progressive hemi-vertebral compression fractures in steroid-induced osteoporotic spine because of coronal imbalance of spinal alignment. There are some difficulties in the treatment of this case: sever osteoporosis caused by glucocortisone therapy and the progressive compression fractures because of imbalance of the spinal alignment. Surgical indication, therefore, should be careful and the method of reconstruction should be well considered because of weakness of spinal column. The decompression of nerve roots is essential and the reconstruction of vertebrae and the correction of alignment, which is already collapsed because of osteoporosis, are necessary. And it is significantly important to maintain the

alignment, to prevent further compression fractures and to prevent the complications when reconstructed with instrumentation after surgical procedures (_{12,13}).

Some authors(_{12,14}) reported the danger of reconstruction surgery with instrumentations for osteoporotic spine. The knowledge about osteoporosis and spinal mechanical stress after reconstructions is very important in the surgical treatment. We previously reported the efficacy of instrumentations in osteoporotic spine and the problems of reconstruction with instrumentations (₁₅). We consider, in osteoporotic spine, that it is important to correct the spinal alignment in order to make the equal axial forces in coronal plane and also in sagittal, and that it is important to disperse the mechanical stress in reconstructed anterior column with adequate autologous bone grafts and interbody spacers in order to disperse the axial forces (_{15,16}). The instrumentations are necessary in reconstruction of spine in elder people to prevent collapse of grafted bone and to obtain fusions (₁₇). The severe osteoporotic spine should not be corrected with rigid instrumentation because it is in danger of fractures (_{12,18}). Hence, polyaxial pedicle screws are preferred in osteoporotic spine for in situ fusions (₁₄). The stiffness of combination of pedicle screw and laminar hook (₁₈) against the pullout stress is 150% of that with only pedicle screws (_{19,20}). Especially after surgical treatment Therapy for osteoporosis is essential in the patients with glucocorticosteroid therapy in order to prevent collapse of spinal column.

The American College of Rheumatology reported: supplementation with calcium and vitamin D should be offered to all patients receiving glucocorticoids, to restore normal calcium balance and treatment with a bisphosphonate is recommended to prevent bone loss in whom long-term glucocorticoid treatment at 5mg/day is being initiated (_{6,7,8,9}). The purpose of treatment is not only the relief of the present clinical symptoms but also the prevention of complications related to the reconstruction fusion surgery (₁₀). We face the high-aged society in which the number of osteoporotic patients is still increasing. We must know the biological mechanical stress and the quality of the vertebral bodies when reconstruction in surgical procedure of the spine indicated. Therefore the knowledge of the balance in spinal alignment and biological therapy for osteoporosis may be required.

CORRESPONDENCE TO

Takahiro IIZUKA M.D
KAWASAKI Hospital
Division of Orthopaedic Surgery
244 Mizuma Kaizuka City, OSAKA, JAPAN
Tel. 001-81-724-46-1105
Fax.001-81-724-46-3196

References

1. Vanderpool D.W., James.J.I.P., Ruth Wynne-Davies,. Scoliosis in the Elderly. J Bone Joint Surg [A], 1969;51-A:446-455.
2. Lieberman I.H., Dudeney S., Reinhardt M.K.et al. Initial Outcome and Efficacy of "Kyphoplasty" in the Treatment of Painful Osteoporotic Vertebral Compression Fractures. Spine, 2001;26:1631-1638.
3. Healey J. H., Lane J.M.. Structural Scoliosis in Osteoporotic Women. ClinOrthop, 1985;195: 216-223.
4. Willen J. , Lindahl S.. Nordwall A.. Unstable Thoracolumbar Fractures (A Comparative Clinical Study of Conservative Treatment and Harrington Instrumentation). Spine, 1985;10:111-122.
5. Lane J.M., Vigorita V.J.. Current Concepts Review; Osteoporosis. J Bone Joint Surg [A], 1983; 65-A:274-278.
6. American College of Rheumatology. Ad Hoc Committee on Glucocorticoid-Induced Osteoporosis. Recommendations for the Prevention and Treatment of Glucocorticoid-Induced Osteoporosis. Arthritis & Rheumatism, 2001;44: 1496-1503
7. American College of Rheumatology. Two-Year Effects of Alendronate on Bone Mineral Density and Vertebral Fracture in Patients Receiving Glucocorticoids. Arthritis & Rheumatism , 2001 ; 44: 202-211.
8. Andress H.J., Schurmann M., Heuck A. et al. A rare case of osteoporotic spine fracture associated with epidural lipomatosis causing paraplegia following long-term cortisone therapy. Arch Orthop Trauma Surg , 2000;120:484-486.
9. Tanaka I., Ohshima H.. Clinical Features in Glucocorticoid-Induced Osteoporosis. Jpn. J. Clin.Immun., 2001;24:142-151.
10. Malcolm B.W. Spinal Deformity Secondary to Spinal Injury. Orthopedic Clinics of North America, 1979; 10:943-952.
11. Gertzbein S.Scoliosis Research Society(Multicenter Spine Fracture Study) . Spine, 1992;17: 528-540.
12. Ueta T, Shiba K., Takemitsu Y. Spinal Instrumentation Surgeries for the Aged People. SekituiSekizueiga, 1999; 12:181-190.
13. Chapman W.C., Thompson R. C. Compression Fracture as a Complication of Pseudarthrosis in a Scoliosis Fusion Clin Orthop, 1971;81:136-138.
14. Sasaki K. Spinal Instrumentation for Osteoporotic Spine in Thoracolumbar Region. SekituiSekizueiga, 1998; 11: 349-353.
15. Iizuka T., Harada N., et al. Influence of BMD on Spinal Reconstruction in Lumbar Spine. RinshoSeikeigeka , 2001;36:741-747.
16. Yamamoto H., Shibata T., Ikeuchi M.. Calcium Phosphate Cement Infection for Osteoporotic Vertebral Fracture. Rinsho Seikei Geka(Clinical Orthopaedic Surgery) , 1999;34:435-442.
17. Zindrick M. R., Wiltse L.L., Widell E.H., et al. A Biomechanical Study of Intrapeduncular Screw Fixation in

the Lumbosacral Spine. Clin Orthop , 1986;203:99-112.

18. Sasaki K.. Poserior Spinal Instrumentation for Osteoporotic Vertebral Fracture of the Thoracolumbar Spine. SekituiSekizuigeka 1997;10: 921-927.

19. Hasegawa K., Takahashi H., Uchiyama S., et al. An

Experimental Study of a Combination Method Using a Pedicle Screw and Laminar Hook for the Osteoporotic Spine. Spine, 1997;22:958-963.

20. Sano S. Multi-level Spinal Insturumentation for Patients with Severe Osteoporosis. Rinsho Seikei Geka (Clinical Orthopaedic Surgery), 1999; 34:471-478.

Author Information

Takahiro Iizuka, M.D.

Division of Orthopaedic Surgery, KAWASAKI Hospital

S. Yamada, M.D.

Division of Orthopaedic Surgery, Kawanishi Municipal Hospital