

# Intrahepatic gallbladder - A case report and review of literature

P Audi, F Noronha, J Rodrigues

## Citation

P Audi, F Noronha, J Rodrigues. *Intrahepatic gallbladder - A case report and review of literature*. The Internet Journal of Surgery. 2009 Volume 24 Number 1.

## Abstract

Congenital anomalies of the gallbladder have been reviewed by several authors<sup>(1-3)</sup> and the intrahepatic gallbladder specifically by McNamee<sup>(4)</sup>. Intrahepatic gallbladder is one of the ectopic locations of the gall bladder resulting from a developmental anomaly. It is the second most frequent ectopic location of the gall bladder<sup>(4)</sup>. We report a case of intrahepatic gallbladder presenting with acute calculous cholecystitis. This patient underwent laparotomy with cholecystectomy and made an uneventful recovery.

## INTRODUCTION

Intrahepatic gallbladder is one of the ectopic locations of the gallbladder. The gallbladder is usually intrahepatic during its embryologic period and becomes extrahepatic later on in its development. In adults approximately 60% of intrahepatic gallbladders are associated with gallstones. Intrahepatic gallbladders can be readily imaged by either ultrasonography or CT scan.

## CASE REPORT

A 45-year-old female presented with complaints of pain in the right hypochondriac region, jaundice and vomiting for 15 days.

On examination, there was tenderness over the right hypochondrium, with minimal guarding.

Investigations: Total WBC count = 12,000 per cumm, Neutrophils = 65%, Lymphocytes = 33%, Monocytes = 2%

LFT at admission: Serum bilirubin—total—8.2mg%

direct—5.3mg%

SGPT—173U/l

SGOT—114U/l

Alkaline phosphatase—361U/l

Ultrasonography showed an intrahepatic gallbladder with multiple small calculi and dilated common bile duct (CBD).

The patient was admitted as acute calculous cholecystitis and was treated conservatively, with NBM, Ryles tube aspiration and injectable 3<sup>rd</sup> generation cephalosporins and metronidazole.

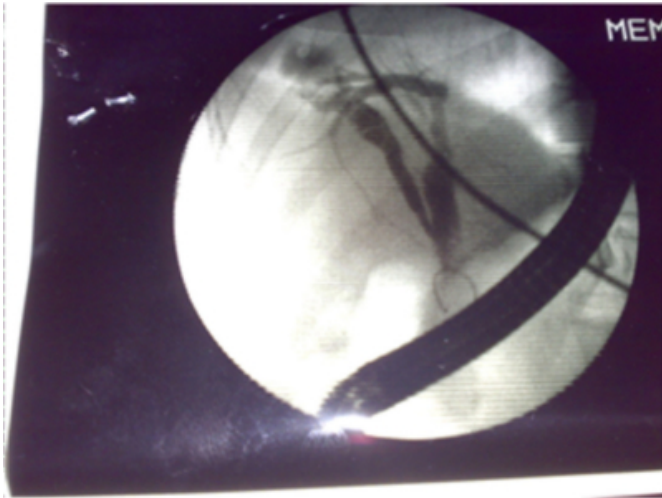
ERCP with biliary sphincterotomy and CBD stenting was done on the 5<sup>th</sup> day after admission. At ERCP, the intrahepatic gallbladder was confirmed, with sludge in the CBD.

Laparotomy with thoracic extension and cholecystectomy was done on the 15<sup>th</sup> day of admission. The entire operation was performed without the provision of a C-arm facility. The gall bladder was found to be completely embedded within the substance of the liver. Laparotomy was done by a right paramedian incision which was extended upwards cutting the right 10<sup>th</sup> and 11<sup>th</sup> rib with the help of a rib shear to gain better access. Abdominal closure was done in layers

The patient had an uneventful post-operative course and was discharged in due course of time.

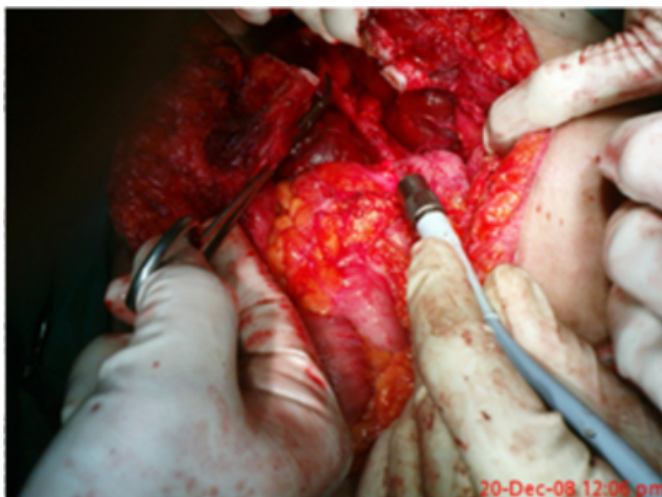**Figure 1**

Figure 1: ERCP picture showing an intrahepatic gallbladder with dilated CBD



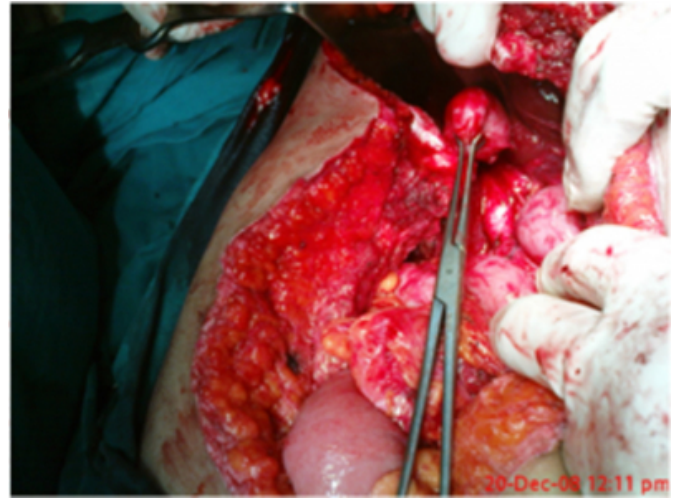
**Figure 2**

Figure 2: Intraoperative picture showing cut ribs with artery forceps pointing towards the intrahepatic gallbladder.



**Figure 3**

Figure 3: Gallbladder grasped by Babcock forceps



**FOLLOW-UP:** The CBD stent was removed 6 weeks after surgery. The patient has since followed up for 1 year and is doing well with no recurrence of abdominal pain.

## **DISCUSSION**

An intrahepatic gallbladder is one that is partially or completely embedded within the substance of the liver.<sup>[5,6]</sup>

Intrahepatic gallbladders have a subcapsular location along the anterior inferior right lobe of the liver<sup>[7]</sup>, occasionally a small portion of the intrahepatic gallbladder may protrude from the liver. An intrahepatic gallbladder results from a developmental anomaly or a congenital arrest which prevents the gallbladder from moving from its intrahepatic position in the 2<sup>nd</sup> month of gestation to its normal superficial location. The condition may be suspected, if the cholecystogram or USG reveals a gallbladder in an unusually high location.

An intrahepatic gallbladder has usually impaired function because it does not empty completely. This may result in gallstone formation due to stasis. Most intrahepatic gallbladders are only partially embedded within the hepatic parenchyma and then can usually be easily identified at the time of cholecystectomy. Those that are completely buried within the liver may be a challenge for the general surgeon.

A completely embedded gallbladder is best approached by first identifying the cystic duct where it joins the common hepatic duct and then following the cystic duct back to the gallbladder.

## **CORRESPONDENCE TO**

Dr. PANDARINATH AUDI, House no 21, BALLI ,  
QUEPEM, GOA pin code 403703

E-mail: audipankaj@rediffmail.com

## **References**

1. Gross RE: Congenital anomalies of gallbladder: A report of 148 cases with report of a double gallbladder. Arch Surg; 1936; 32: 131-162.
2. Corcoran DB, Wallace KK: Congenital anomalies of the gallbladder. Am Surg; 1954; 20: 709-725.
3. Flanery MG, Caster MP: Congenital abnormalities of gallbladder: 101 cases. Instr Abstr Surg; 1956; 103: 439-457.
4. McNamee EP: Intrahepatic gallbladder. Am J Roentgenol; Radium Ther Nucl Med 1974; 121: 396-400.
5. Bockman DE, Freeny PC: Anatomy anomalies of the biliary tree. Laparos Surg 1992; 1: 92.
6. Couinaud C, cited in Smadja C and Blumgart LH (ed): Surgery of the Liver and Biliary tTract. Edinburgh, Churchill Livingstone 1988, p.16.
7. Meilstrup JW, Hopper KD, Thieme GA: Imaging of gallbladder variants. AJR 1991; 157: 1205-1208.

**Author Information**

**Pandarinath Audi**

Department of Surgery, Goa Medical College

**F. P. Noronha**

Department of Surgery, Goa Medical College

**Jude Rodrigues**

Department of Surgery, Goa Medical College