

Multi Level Cervical Spine Chondroma With Subpriosteal Mass And Abscess

A Babashahi, M Panahbekhoda, M Mashari, S Fallahpour

Citation

A Babashahi, M Panahbekhoda, M Mashari, S Fallahpour. *Multi Level Cervical Spine Chondroma With Subpriosteal Mass And Abscess*. The Internet Journal of Spine Surgery. 2009 Volume 5 Number 2.

Abstract

Chondromas are rare primary spine tumors, and few cases of chondromas

located in the cervical spine have been reported in the literature up to now¹. we report a case of a cervical periosteal chondroma in a 16-year-old girl presenting with progressive neck pain, hand radiculopathy and a syndrome of spinal cord compression since 4 months before admission. Magnetic resonance imaging revealed a lesion that was hypo- or isointense on T1-weighted images and iso-hyperintense on T2-weighted images. Administration of Gd-DPTA resulted in margin enhancement on T1-weighted images. CT scans revealed destruction of the C3 vertebral body and epidural compressing mass from C2-C4. The patient underwent a C3- C4 corpectomy with complete en-block removal of the mass. The authors emphasize that early identification of the initial lesion should be coupled with total surgical resection, as a definitive treatment, in order to prevent malignant transformation and development of neurologic deficit⁽²⁾.

INTRODUCTION

Enchondromas (sometimes known as chondromas) are that result from failed migration of chondrocytes. Only about 1% of enchondromas occur in the spine, although they are more common in the setting of Ollier's syndrome or Maffucci's syndrome.^(3,4) They can present from the first to sixth decade of life, although they are more common in the second and third decades. There may be a male predominance, although this is controversial.

CASE REPORT

A 16 years old Iranian female presented with a complaint of neck pain and radicular pain to right hand gradually since 4 months ago. On examination, the active range of movement of the cervical spine was painfully decreased by approximately 10 percent of normal. Neurological examination revealed muscle power of 4/5 in proximal and 4/5 in distal parts of the upper extremities. Systemic workup did not reveal evidence of disease elsewhere. Lateral

cervical X-ray showed destruction of the C4 body fig (1). MRI revealed a lesion that was hypo- or isointense on T1-weighted images and iso-hyperintense on T2-weighted images. Administration of Gd-DPTA resulted in margin enhancement on T1-weighted images. The noticeable point about this patient was that during mass extraction, a yellowish pus substance was drawn off through corpectomy that mimicked infective problems such as a TB infection, however no infective pathology was reported after laboratory examinations and the pathologic study was compatible with chondroma.

TREATMENT

The surgical procedure was conducted in one stage by anterior cervical approach and exposing the C2-C5 vertebrae. C2-C3, C3-C4 and C4-C5 microdiscectomy in addition with anterior total C3 and C4 corpectomy were done, then total resection of the epidural subpriosteal mass and jelly yellowish material were done. Reconstruction was

performed using a harvested graft from iliac crest and then was fixed with anterior cervical plate with screw (ADDplus a device consist of titanium cylindrical cage and plate from the Ulrich company) fig(2). The patient didn't suffer any other new neurological deficits and was able to ambulate with out Philadelphia cervical collar post operatively. After one week she was with out any pain was satisfactory controlled with analgesic medication.

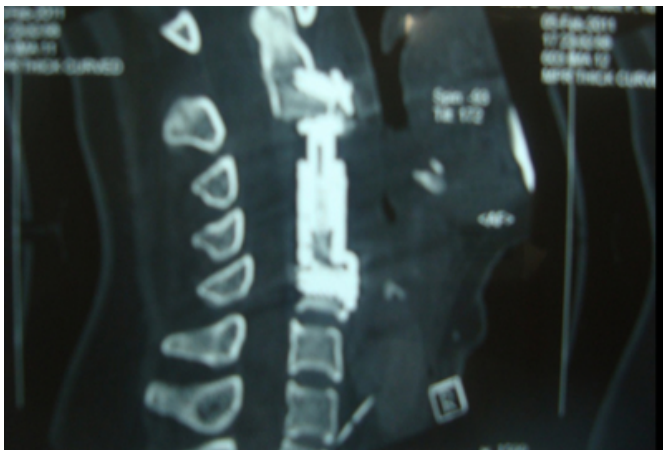
Figure 1

Figure 1

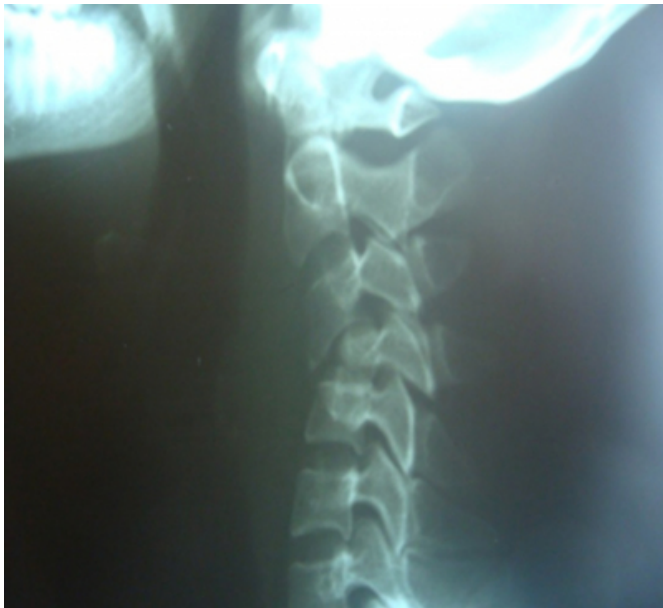

Figure 2

Figure 2



DISCUSSION

10% to 25% of patients with multiple hereditary exostosis have solitary lesions.(7,8) Patients are rarely symptomatic from isolated enchondromas of the spine. However, symptomatic patients can develop a progressive and

destabilizing deformity. An enchondroma most often affects the cartilage that lines the inside of the bones. The bones most often involved with this benign tumor are the miniature long bones of the hands and feet.(5). While the exact cause of enchondroma is not known, it is believed to occur either as an overgrowth of the cartilage that lines the ends of the bones, or as a persistent growth of original, embryonic cartilage. Individuals with an enchondroma often have no symptoms due to isolated spinal chondroma. However, symptomatic patients can develop a progressive and destabilizing deformity. Plain radiographs may demonstrate a lucency within the vertebral body, but the sensitivity for detection is low. Bone scans are positive if done during skeletal growth.

Treatment for asymptomatic lesions are grafting and instrumentation. Malignant progression to chondrosarcoma must be verified by needle biopsy when suspected.(5,6). When the pain, a palpable mass, or neurological compromise, or the diagnosis is in question, surgery should be considered. Surgery is usually curative and because most tumors stop growing after closure of the epiphyseal plate during puberty, recurrence is rare. Malignant degeneration into chondrosarcoma occurs in 1% to 5%.

CONCLUSION

While the exact cause of enchondroma is not known, it is believed to occur either as an overgrowth of the cartilage that lines the ends of the bones, or as a persistent growth of original, embryonic cartilage. Specific treatment for enchondroma is determined by a physician based on the age, overall health, and medical history of the patient. If there is no sign of bone weakening or growth of the tumor, observation only may be suggested. However, follow-up with repeat x-rays may be necessary. Some types of enchondromas can develop into malignant, or cancerous, bone tumors later. Careful follow-up with a physician may be recommended.(3,5,7). Finally, we think some patients with cervical chondroma can mimic epidural abscess, although further case study is recommended.

References

1. Tsulee J, Edward B: Primary tumors of the spine. Contemporary Neurosurgery 2006; 28(6): 1-8.
2. Narayan S: Chordomas. Clinical Orthopaedics and Related Research 1986; (204): 135-42.
3. Lane J, Cammisa FJ, Glasser D: Benign cartilage tumors of the spine, In Sundaresan N, Schmidek HH, S M e r AL, Rosenthal DI (eds): Tumors of the Spine: Diagnosis and Clinical Management. Philadelphia, WB Saunders, 1990, pp 146-148.
4. Scarborough M, Moreau G: Benign cartilage tumors.

Orthop Clin North Am 27:583-589,1996

5. Wang XL, De Beuckeleer LH, De Schepper AM, Van Marck E (2001). "Low-grade chondrosarcoma vs enchondroma: challenges in diagnosis and management". European radiology 11 (6): 1054-7

6. Winn RH, Youmans JR: Youmans Neurological Surgery,

5th ed. Philadelphia: Saunders, 2004, pp 4840-4843

7. Akeyson EW, McCutcheon IE: Single-stage posterior vertebrae tomy and replacement combined with posterior instrumentation for spinal metastasis. J Neurosurg 85:211-220, 1996.

8. Dahlin DC, Unni KK: Bone Tumors. Springfield, IL, Charles C Thomas, 1986, pp 19-32,228-229.

Author Information

A. Babashahi, MD

Assistant Professor, Department of Neurosurgery, Ahwaz University of Medical Sciences

M.H. Panahbekhoda, MD

Resident, Department of Neurosurgery, Ahwaz University of Medical Sciences

M.A. Mashari, MD

Resident, Department of Neurosurgery, Ahwaz University of Medical Sciences

S. Fallahpour, MD

Resident, Department of Neurosurgery, Ahwaz University of Medical Sciences