

# Histoenzymic Effects Of Cigarette Smoke On The Superior Colliculus Of Rattus Norvegicus.

G Omotoso, O Akinola, E Caxton-Martins, R Kadir, A Akinyinka

## Citation

G Omotoso, O Akinola, E Caxton-Martins, R Kadir, A Akinyinka. *Histoenzymic Effects Of Cigarette Smoke On The Superior Colliculus Of Rattus Norvegicus.* The Internet Journal of Toxicology. 2009 Volume 8 Number 1.

## Abstract

The study was conducted using twenty adult Wistar rats that were randomly grouped into a treatment and a control group comprising both sexes. The control group was exposed to smoke from cotton wool, while the treatment group inhaled smoke from a completely burnt cigarette containing 0.735 g tobacco, once daily for 14 days. The rats were sacrificed by cervical dislocation and the superior colliculi (SC) excised, weighed, homogenized and assayed for the activities of lactate dehydrogenase (LDH), glucose-6-phosphate dehydrogenase (G6PDH), and alkaline phosphatase (ALP). SC tissues for histological studies were fixed in formol calcium and subsequently processed using Feulgen reaction for nucleic acids and Cresyl violet stain for Nissl bodies studies. There was an increase in the enzyme activities in the treated group, compared to the control; and this increase was more in the female rats although not statistically significant. The derangements observed in the enzyme studies led to various histoarchitectural changes in the SC of the rats exposed to tobacco smoke, and a gradual depletion of DNA positive cells and Nissl bodies in the neurons.

## INTRODUCTION

Many of the 4 000 constituents of tobacco smoke are known to be toxic to the body, affecting the brain, cardiovascular and respiratory systems, among other systems and organs of the body<sup>1</sup>. Many of these components are volatilized during burning, and others, including the aromatic hydrocarbons, are formed during combustion of the leaf components<sup>2</sup>. By virtue of the short-term actions of nicotine on the cholinergic system, it has positive effects on certain cognitive domains, and has been said to be neuroprotective in a way<sup>3</sup>. The chief pharmacologically active ingredients are nicotine (acute effects) and tar (chronic effects)<sup>4</sup>. A completely burned cigarette stick usually contains between 1-6 mg of nicotine, apart from the 1-5 % carbon monoxide present in the smoke<sup>5</sup>.

The superior colliculus (SC) functions in visual attention and centering of the visual image on the retina, thereby serving essentially as a visual relay centre<sup>6</sup>. It transforms both visual and non-visual sensory signals into motor commands that control orienting behaviors<sup>7</sup>. Studies by Yildiz et al<sup>8</sup> showed that nicotine is capable of modulating enzyme activities. Vascular injury resulting from ischemic process leads to reduction in the supply of oxygen and nutrients to the brain, thereby causing various forms of degenerative changes in the tissue.

Tobacco smoke, as an exogenous source of reactive oxygen species, has a broad spectrum of oxidant-ionising radiation which generates free radicals in exposed tissues<sup>9</sup>. Due to a low oxygen tension, anaerobic glycolytic pathway is utilized to supply the brain with its ATP requirement. The conversion of lactate to pyruvate is catalyzed by lactate dehydrogenase (LDH). Following nicotine administration, LDH leakage through the membranes is elevated, due to its effects on some membrane markers, thereby increasing the level of this enzyme<sup>8,10</sup>.

Glucose-6-phosphate dehydrogenase (G-6-PDH) is important in the production of reduced nicotinamide adenine dinucleotide phosphate (NADPH) and the production of ribose, which are vital in RNA and DNA replication<sup>11</sup>.

Alkaline phosphatase (ALP), a membrane marker, facilitates transport across cell membranes, causing the breakdown of ATP to ADP and inorganic phosphate, thereby making free energy available for metabolic processes<sup>12</sup>. The present work was designed to study the effect of nicotine on the morphology of the superior colliculus (especially in relation to DNA and Nissl bodies) and certain enzymes of glucose metabolism in a model of Wistar rats.

## MATERIALS AND METHODS

Following appropriate ethical guidelines, twenty (20) adult Wistar rats of both sexes with an average weight of 219.5 g were randomly divided into a control and a treated group. They were allowed to acclimatize, and housed in different cages at normal room temperature, at the Anatomy Department Animal House, University of Ilorin. Feeds and water were available *ad libitum*. Each animal in the treated group inhaled smoke from a stick of cigarette (Benson and Hedges®) containing 0.735 g of tobacco. Each cigarette was completely burnt<sup>13</sup> within 15 min of exposure, once daily for 14 days; while the control group was allowed to inhale smoke from burnt cotton wool of equal weight. A customized exposure chamber was used for the experiment.

The animals were sacrificed by cervical dislocation 18 hours after the last exposure. The cranium was gently opened to expose the brain, and the superior colliculi (SC) were identified and excised. Immediately after, the SC were weighed and placed in 0.25 M sucrose solution, and homogenized using a homogenizer. The homogenate was centrifuged at 500 rpm for 5 min using a centrifuge (Gallenkomp, England). The supernatants collected, using Pasteur pipettes, were stored at -20°C, and thereafter enzyme study was carried out for the activities of lactate dehydrogenase (LDH), glucose-6-phosphate dehydrogenase (G-6-PDH) and alkaline phosphatase (ALP). Through spectrophotometry (Colorimetric method), the activities of LDH and (G-6-PDH) were determined in the homogenates using the RANDOX's Kits (Antrim, UK)<sup>14</sup>, and the Quimica Clinica Aplicada's kit (Spain)<sup>15</sup> for ALP. The tissues for histological studies were harvested on Days 7 and 14, fixed in formol calcium for 24 hrs at room temperature, and histological preparations were carried out using Feulgen reaction for nucleic acids and Cresyl violet staining for Nissl bodies.

The Student's t-test was used in analyzing the biochemical data collected, and p values of < 0.05 were considered significant.

## RESULTS

Increased levels of enzyme activity were noticed in the SC of animals treated with cigarette smoke compared with those exposed to cotton wool smoke. The average LDH activity in the SC of the male treated group was 1262.5 U/L, higher than the control value of 1050.0 U/L. The level of LDH activity in the female rats was significantly higher (1817.5 U/L: p<0.05) in the treated group compared with the control

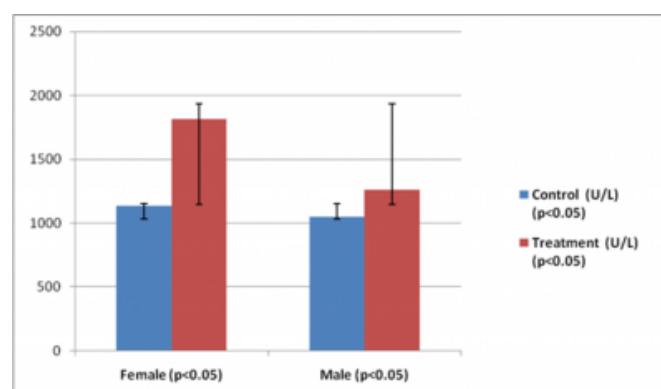
(1135.0 U/L) (Figure 1); and there was statistically significant difference between the treatment groups of both male and female rats (p<0.05).

G-6-PDH activity was slightly higher in the male treated group (1415.0 U/ml homogenate) than the control (1394.0 U/ml homogenate) (Figure 2). However, more increase was noted in the female treated group (1437.5 U/ml homogenate; p<0.05) than the control (1295.0 U/ml homogenate); and, there was a significant difference between the male and female treatment subgroups (p<0.05).

Exposure to cigarette smoke produced higher levels of ALP in the treated groups of both male and female rats (85.5 IU/L:-male and 130 IU/L:-female) than the control groups (71 IU/L:-male and 55 IU/L:-female) (Figure 3), with the females having a more than two-fold increase (p<0.05).

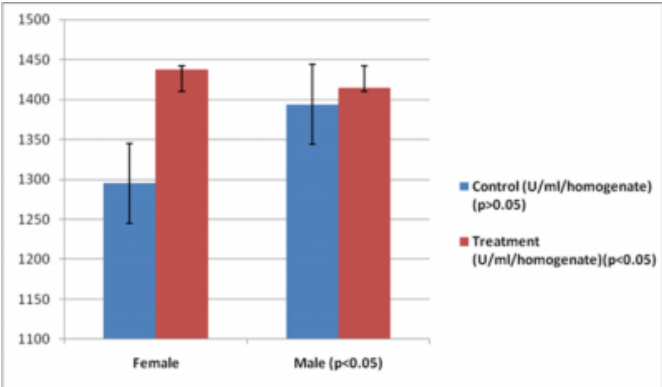
### Figure 1

Figure 1: Activity of lactate dehydrogenase in the superior colliculus of adult Wistar rats, showing statistically significant differences in the control and treatment groups, and between the male and female rats (p



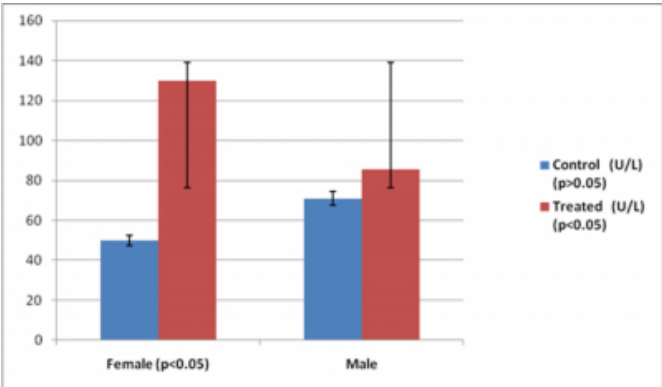
**Figure 2**

Figure 2: Activity of glucose-6-phosphate dehydrogenase in the superior colliculus of adult Wistar rats, showing statistically significant differences between male and female treatment groups, and also between the control and treatment groups of the male Wistar rats ( $p<0.05$ ).



**Figure 3**

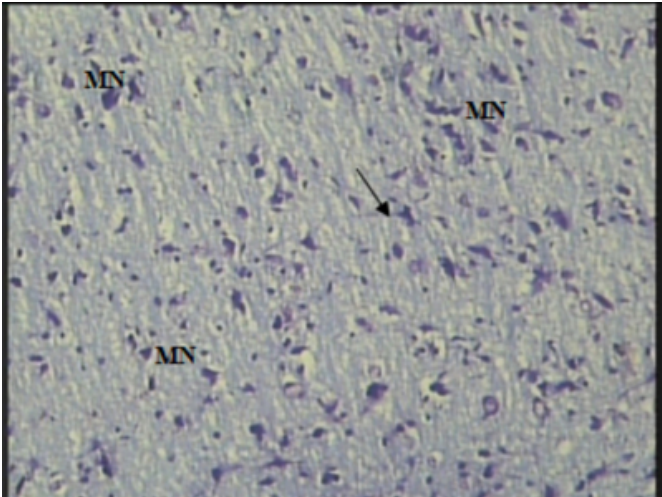
Figure 3: Activity of alkaline phosphatase in the superior colliculus of adult Wistar rats, showing statistically significant differences between the control and treatment groups of the female rats, and also between the male and female treatment groups ( $p<0.05$ ).



The histological findings of the superior colliculus of the male Wistar rats revealed numerous neurons, majority of which were multipolar, with preserved architecture, and presence of Nissl bodies and DNA-positive cells, in the control groups (Figures 4, 7); while the treated groups showed sparsely dispersed neurons, vacuolated spaces, and progressive reduction in intensity of staining for Nissl bodies and DNA (Figures 5, 6, 8, 9) compared with the control.

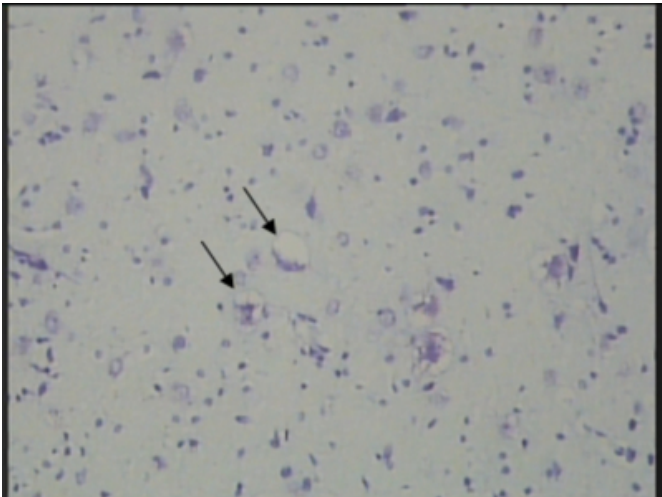
**Figure 4**

Figure 4. Photomicrograph of the superior colliculus of the male control group (Day 7) showing numerous multipolar neurons (MN) per unit area with intact cytoplasmic processes (arrow) and positive Nissl staining. Cresyl Violet X250.



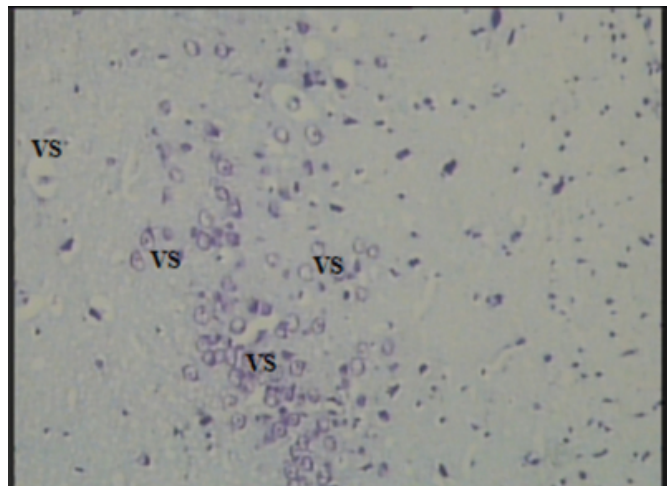
**Figure 5**

Figure 5. Photomicrograph of the superior colliculus of the male treatment group (Day 7) showing reduced staining intensity for Nissl bodies and few vacuolated cytoplasm (arrow). Cresyl Violet X250



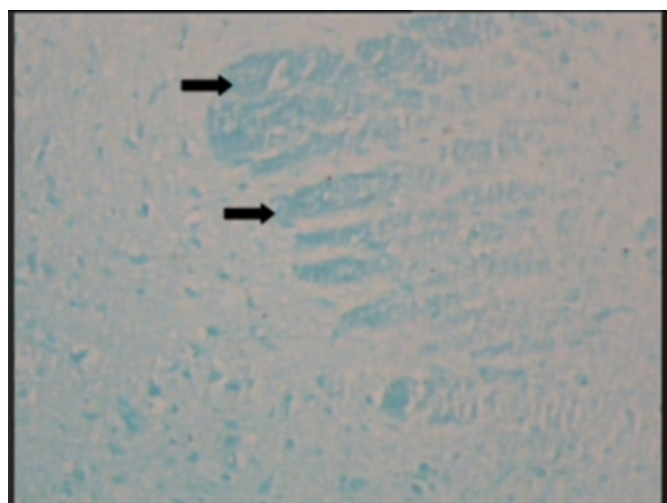
**Figure 6**

Figure 6. Photomicrograph of the superior colliculus of the male treatment group (Day 14) showing numerous vacuolar spaces (VS), reduction in number and density of neurons (per unit area), disintegrated processes, and further reduction in staining intensity for Nissl bodies. Cresyl Violet x250.



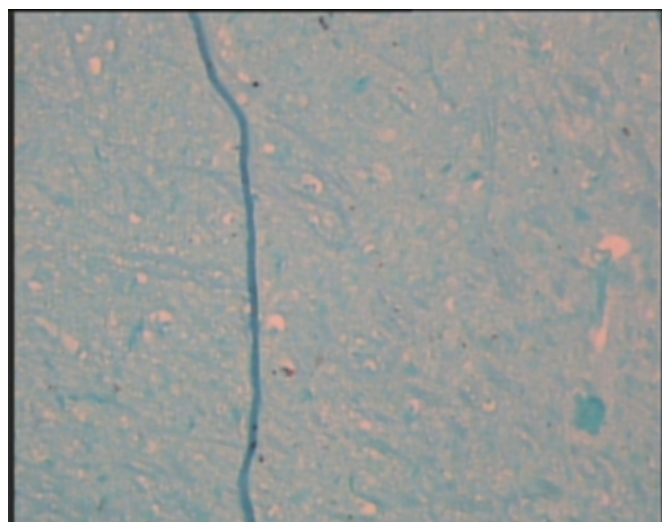
**Figure 7**

Figure 7. Photomicrograph of the superior colliculus of the male control group (Day 7) with areas of high concentration of DNA (thick arrows). Feulgen X100.



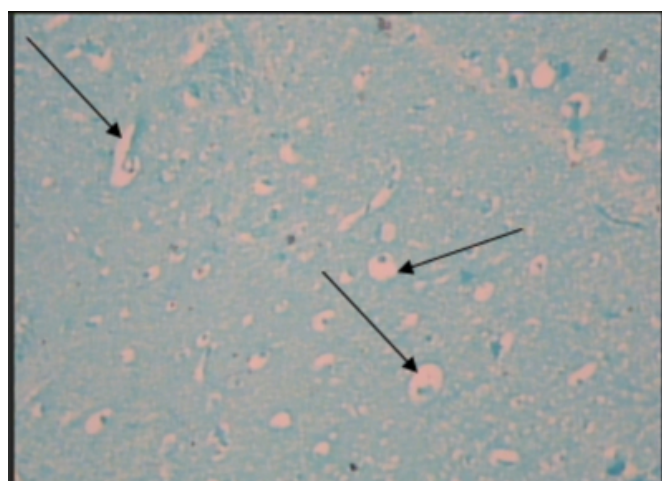
**Figure 8**

Figure 8. Photomicrograph of the superior colliculus of the male treatment group (Day 7): reduced staining for DNA, and some vacuolar spaces. Feulgen X100



**Figure 9**

Figure 9. Photomicrograph of the superior colliculus of the male treatment group (Day 14) showing reduced staining of DNA cells and many vacuolar spaces (arrows). Feulgen X100.



## **DISCUSSION**

Nicotine affects the process of hormone secretion, enzyme activities, and other cellular mechanisms<sup>8</sup>. To maintain brain functions during hypoxia, its energy requirement is generated via anaerobic glycolysis, where LDH catalyses the conversion of lactate to pyruvate.

During cellular oxidative stress, whether endogenous in origin or initiated by drugs, or environmental chemicals, NADPH is critical for maintaining glutathione (GSH) in its reduced form, which is essential for detoxification of

reactive free radicals and lipid hydroperoxidase<sup>11</sup>. Hence, NADPH is important for its role in the detoxification of hydrogen peroxide. The production of ribose by hexose monophosphate shunt (HMS; for which (G-6-PDH) is the rate-limiting enzyme) is relevant to the synthesis of nucleotides used in RNA and DNA replication, and hence, cell division and possibly DNA repair<sup>11</sup>.

Administration of nicotine causes an increased LDH activity, with an attendant disturbance in cellular membrane integrity<sup>8</sup>, and chronic cigarette smoking in man enhances the activity of LDH in the serum<sup>16</sup>.

Carbon monoxide from cotton wool smoke and cigarette smoke (which also contain carbon monoxide) can both induce oxidative stress in the rat's brain, resulting in the increased activity of the enzymes of carbohydrate metabolism following the initiation of anaerobic glycolysis. Consequently, the level of activities of these enzymes were observed in this study to be higher in animals exposed to smoke from completely burnt cigarettes than those exposed only to cotton wool smoke.

The increased LDH level following exposure to cigarette smoke was much more higher among the female rats compared with their control, than it was for the male groups. Similarly, the level of ALP, which is responsible for transport across cell membranes, was especially higher in the female subgroup exposed to cigarette smoke, consequently altering the integrity of the membrane and its ability to mediate normal membrane transport. As a result of this also, leakage of LDH through the membranes was encouraged<sup>10</sup>. Although tobacco has been noted to inhibit ovarian functions<sup>17,18</sup>, the statistically significant higher levels of enzyme activities observed in the superior colliculus of the female Wistar rats might also be due to their lower body weights, compared to the male animals with higher body weights, at the time of sacrifice. At the commencement of the experiment, both male and female Wistar rats had very close body weights, but the rate of growth and increase in body weight was much faster in the male animals compared to the females.

The synthesis of proteins is critical to the growth and development of any cell, and nucleic acids as well as Nissl bodies are crucial in this<sup>19</sup>. Nissl bodies are strongly basophilic inclusions found in the cell body of the neuron, containing numerous ribosomes. The histological findings in the superior colliculus of the male rats showed a sparse distribution of neurons in the animals exposed to cigarette

smoke, and various forms of cellular distortions and degeneration. The longer the number of days the treated groups were exposed, the more the reduction in the number of neurons, the more the degree of architectural distortions, cellular degeneration and vacuolation. There was a gradual decline in the staining intensity of both DNA-containing cells and Nissl bodies, which was associated with prolonged duration of exposure to cigarette smoke. The depletion of the cellular constituents in the neurons could adversely affect protein synthesis and consequently, vital cellular processes and mechanisms.

### **References**

1. American Cancer Society. Prevention and early detection: cigarette smoking. [www.cancer.org](http://www.cancer.org).
2. Lewis, W.H and Elvin-Lewis, M.P.F. Plants affecting Man's health. In, Medical Botany. New York, Wiley-Interscience Publication; 1977: p54.
3. Swan, G.E and Lessov-Schlaggar, C.N. The Effects of Tobacco Smoke and Nicotine on Cognition and the Brain. *Neuropsychol Rev.* 2007;17:259-273.
4. Ritter, J.M., Lewis, L.D and Mart, T.G.K. Drug and alcohol abuse in clinical pharmacology 3rd ed. London, Arnold; 1995: pp 673-675.
5. Bennett, P.N and Brown, M.J. Non-medical use of drugs: Tobacco. In, Clinical Pharmacology. 9th ed. Edinburgh, Churchill Livingstone; 2003: pp173-178.
6. Wurtz, R.H and Goldberg, M.E. The primate superior colliculus and the shift of visual attention. *Invest. Ophthalmol* 1972;11:441-450.
7. Doubell, T.P., Skaliara, I., Baron, J and King, A.J. Functional connectivity between the superficial and deep layers of the superior colliculus: An anatomical substrate for sensorimotor integration. *J. Neurosci* 2003;23:6596-6607.
8. Yildiz, D, Ercal, N and Armstrong, D.W. Nicotine enantiomers and oxidative stress. *Toxicology* 1998;130:155-165.
9. Borek, C. Antioxidant Health Effects of Aged Garlic Extract. *J. Nutr* 2001;131:1010S-1015S.
10. Ho, Y and Chang, Y. Neuropharmacology: Regulation of nicotine-induced cyclooxygenase-2 protein expression in human gingival fibroblasts. *Acta Pharmacologica Sinica* 2006;27:409-413.
11. Sodeinde, O. Glucose-6-phosphate dehydrogenase deficiency. *Brailleire's Clinical Haematology.* 1992;5(2): 367-82.
12. Murray, R.K., Granner, D.K., Mayes, P.A and Rodwell, V.W. Harper's Illustrated Biochemistry. 26th ed. New York, McGraw-Hill 2003: p109.
13. Ayres, P.H., Hayes, J.R., Higuchi, M.A., Mosberg, A.T and Sagartz, J.W. Subchronic inhalation by rats of mainstream smoke from a cigarette that primarily heats tobacco compared to a cigarette that burns tobacco. *Inhal Toxicol* 2001;13(2): 149-86.
14. RANDOX Laboratories Ltd., Ardmore, Diamond Road, Crumlin, Co. Antrim, United Kingdom, BT29 4QY.
15. Quimica Clinica Aplicada S.A. A7 Km 1081- P.O.Box 20, E43870 Amposta, Spain
16. Padmavathi, P., Reddy, V.D. and Varadacharyulu, N. Influence of Chronic smoking on serum biochemical profile in male human volunteers. *J. of Health Sci.*, 2009;55(2):265-270 .
17. Gocze P.M., Freeman D.A. Cytotoxic effects of cigarette

smoke alkaloids inhibit the progesterone production and cell growth of cultured MA-10 Leydig tumor cells. Eur J Obstet Gynecol Reprod Biol 2000;93:77–83.

18. Tanko LB, Christiansen C. An update on the anti-estrogenic effect of smoking: a literature review with

implications for researchers and practitioners. Menopause 2004;11:104–109.

19. McIlwain DL, Hoke VB. The role of the cytoskeleton in cell body enlargement, increased nuclear eccentricity and chromatolysis in axotomized spinal motor neurons. BMC Neurosc 2005;6:19.

**Author Information**

**G.O Omotoso**

Department of Anatomy, Faculty of Basic Medical Sciences, University of Ilorin

**O.B Akinola**

Department of Anatomy, Faculty of Basic Medical Sciences, University of Ilorin

**E.A Caxton-Martins**

Department of Anatomy, Faculty of Basic Medical Sciences, University of Ilorin

**R.E Kadir**

Department of Obstetrics and Gynaecology, Faculty of Clinical Sciences, University of Ilorin

**A Akinyinka**

Department of Chemical Pathology and Immunology, University of Ilorin Teaching Hospital