

An Unusual Presentation Of Metastatic Renal Cell Carcinoma To The Frontonasal Region: A Case Report

P Kumar Parida, R Singh Virk, A Gupta

Citation

P Kumar Parida, R Singh Virk, A Gupta. *An Unusual Presentation Of Metastatic Renal Cell Carcinoma To The Frontonasal Region: A Case Report*. The Internet Journal of Head and Neck Surgery. 2006 Volume 1 Number 1.

Abstract

The paranasal sinuses are a rare location of metastases. The most frequent infraclavicular primary tumor to metastasize to nose and paranasal sinuses is the renal cell carcinoma. To the best of our knowledge this is the first case in the English literature of bilateral renal cell carcinoma with metastases in the paranasal sinuses and destruction of the skull base in a 65-old-man. This patient had a primary renal cell carcinoma on the left side for which he had undergone left nephrectomy 15 year back. Right side renal cell carcinoma was diagnosed only after the patient had developed symptoms secondary to his metastases. The patient presented with an unusual manifestation of right frontal swelling and proptosis. The patient was offered palliative interferon therapy for 2 months after which he was lost to follow up.

INTRODUCTION

Distant metastases in head and neck region are very rare. After lung and breast carcinomas, renal cell carcinoma (RCC) is the third commonest infraclavicular tumor that metastasizes to the head and neck₁. Renal cell carcinoma is the most common primary malignancy responsible for metastatic tumor in the sinonasal tract. In 14- 16% of the patients, renal cell carcinoma metastasizes to the head and neck₂. We report the first case of bilateral RCC with large metastases to the frontonasal region producing unusual symptoms before the primary lesion could be detected.

CASE REPORT

A 65 years old male presented to the out patient department of our institute with history of swelling on the right frontal region of 8 month duration and proptosis left eye of 3 month duration. The past history of the patient revealed the history of left side nephrectomy 15 years back for renal cell carcinoma. The patient was asymptomatic for 15 years after nephrectomy till he developed the present symptoms. There was no history of epistaxis or hematuria. There were no features suggestive of increased intracranial tension. Local examination showed a 5cm x 4cm swelling over right frontal region and root of nose causing a facial deformity. The deforming mass appeared solid in the periphery and cystic in the centre with egg shell crackling. The right eye was displaced downward, forward and laterally by the cystic mass present in superomedial part of the orbit. Visual

acuity of the patient was normal. Remaining ENT examination was unremarkable. Systemic examination and chest X-ray chest were within normal limits. The patient was anemic with deranged renal function. Contrast enhanced Computerized Tomography (CT) scan revealed an expansile mass lesion involving right side frontal bone, ethmoid sinus with intracranial and intraorbital extension (figures 1 and 2).

Figure 1

Figure 1: Contrast enhanced computerized tomography, coronal section showing a mixed mass involving the frontal sinus, ethmoid sinus with intraorbital and intracranial extension.

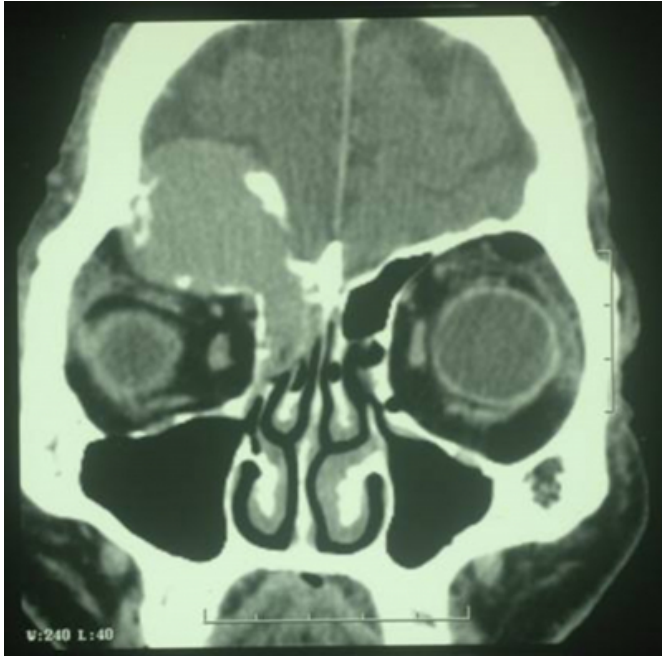
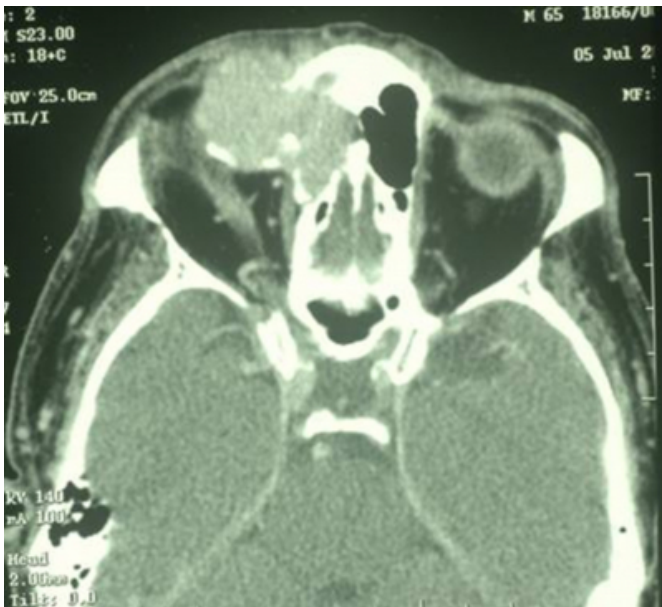

Figure 2

Figure 2: Contrast enhanced computerized tomography, axial section showing a mixed mass involving the ethmoid sinus with intraorbital extension.



Fine needle aspiration cytology (FNAC) from the frontal swelling showed metastatic renal cell carcinoma. The patient was referred to the urology department where he underwent ultrasonography of abdomen which showed right solitary

kidney with 9cm x 8cm renal mass. Subsequently a Contrast CT and CT angiography of abdomen confirmed a large heterogenous space occupying lesion involving the right kidney, suggestive of a renal cell carcinoma (Figures 3 and 4).

Figure 3

Figure 3: Computerised tomography of the abdomen showing a heterogenous mass lesion involving the right kidney with absent of left kidney.

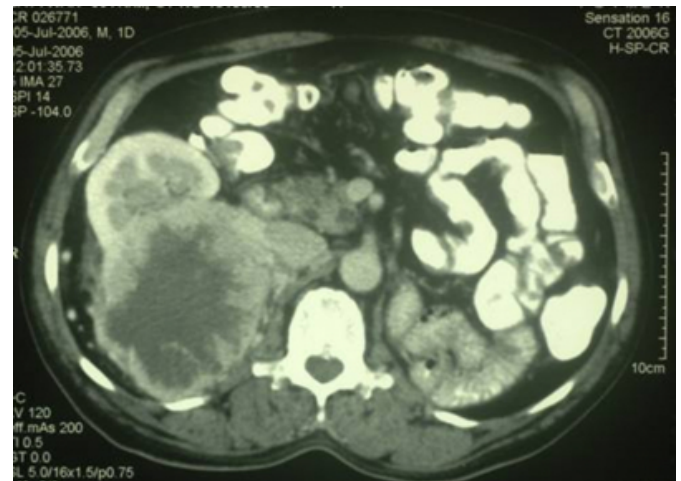
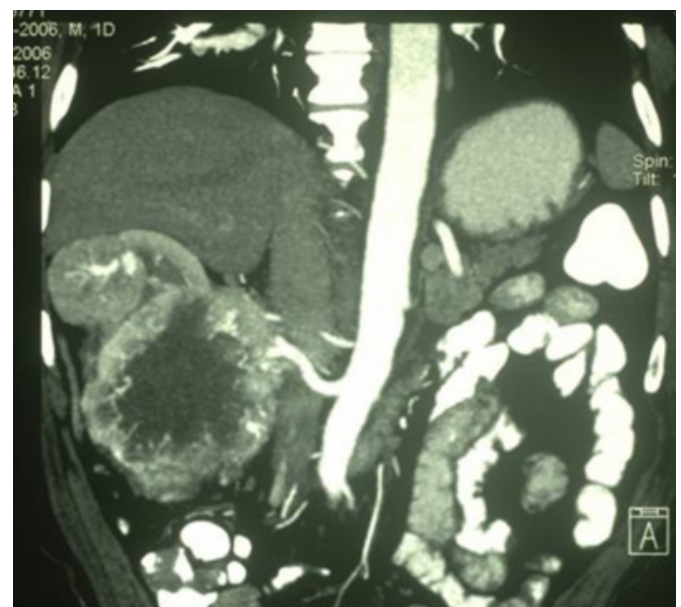


Figure 4

Figure 4: Computrised tomography angiogram showing a heterogenous mass lesion involving the right kidney with absent of left kidney.



The patient underwent CT guided FNAC of right renal mass confirming the diagnosis of renal cell carcinoma. He was subjected to palliative interferon therapy for 2 months after which he was lost to follow-up.

DISCUSSION

RCC occurs more frequently in the fifth and sixth decade of life. The incidence is more in males than females. Metastases may spread to any part of the human body. Lungs (76%), regional lymph node (66%), bone (42%), and liver (41%) are the most common sites³. In 7.5% of patient with RCC, the metastatic tumor may well be the presenting complaint that leads to the diagnosis of the primary tumor² as was the case in this patient. Our patient developed symptoms due to the metastases to frontonasal region and subsequently the primary renal cell carcinoma was detected on the right side. On the right side, it was a second primary RCC. It is known to metastasize many years after the initial treatment of the primary lesion.

Initially, it was thought to be metastases from the left side RCC for which patient had undergone nephrectomy 15 years back but further investigations proved otherwise. Our case represents a case of bilateral RCC, first primary on left with a second primary on right side 15 years after the first primary had been treated with metastases to frontoethmoidal region. Only 1% of the patients with RCC metastases will have isolated head and neck involvement².

Other primary carcinomas metastasizing to the nose and paranasal sinuses are those of bronchus, breast, urogenital tract, gastrointestinal tract, thyroid and pancreas^{1,4}. The pathogenesis of metastatic RCC has been discussed by Nahum and Baily⁵, and also by Boles and Cerny². It apparently passes the fine pulmonary filter bed and metastasizes to the head and neck region². It spreads through the prevertebral venous plexus and reaches the nose and paranasal sinuses via pterygoid plexus. When a sinonasal metastatic RCC is diagnosed, a detailed examination of the renal system by urine analysis, intravenous pyelogram, CT scan and angiogram are required^{5,6}.

Malignant tumors seldom establish metastases in the nose and paranasal sinuses. This is the first case reported in which there was occurrence of second primary in right kidney with metastasis to nose and paranasal sinuses 15 years after nephrectomy for left RCC. In literature epistaxis has been

described as the chief presenting complaint in more than 70% of the cases of metastatic RCC to the paranasal sinuses⁴, but our patient presented with unusual symptoms like frontal swelling and proptosis and denied having any nasal obstruction and epistaxis. It is also important to note that the patient had no renal symptoms, not even hematuria which is present in at least 70% of renal tumors at the time of presentation (8 months after facial tumor)⁶. The present case serves to alert the treating surgeon to the occurrence of symptoms and signs in nose and paranasal sinuses region secondary to the spread of an asymptomatic primary lesion elsewhere in body. Our case presents a clinically challenging condition for clinician as the patient is having solitary right kidney with malignancy

The prognosis for the patients with bilateral renal cell carcinoma with distant metastasis is very poor. Palliative therapy such as irradiation, local arterial perfusion, or chemotherapy, may be used^{1, 6}.

CONCLUSION

The head neck surgeon should consider metastatic RCC as differential diagnosis of paranasal lesion because the symptoms produced by it are very similar to those caused by primary tumors in the nose and the paranasal sinuses.

CORRESPONDENCE TO

Dr. Ramandeep S Virk House No 2168 Sector 15 C
Chandigarh – 160015 INDIA Tel- +91(172)-2782246, Fax-
+91(172)-2727178 E-mail: virkdoc@hotmail.com

References

1. Batsakis JG, McBurney TA. Metastatic neoplasms to the head and neck. *Surg Gynecol Obstet* 1971; 133:673-677.
2. Boles R, Cerny J. Head and neck metastases from renal carcinomas. *Mich Med* 1971; 70:616-618.
3. Saltoh H. Distant metastasis of renal adenocarcinoma. *Cancer* 1981; 48:1487-1491.
4. Bernstein JM, Montgomery WW, Balogh K Jr. Metastatic tumors to the maxilla, nose, and paranasal sinuses. *Laryngoscope* 1966; 76:621-650.
5. Nahum AM, Bailey BJ. Malignant tumors metastatic to the paranasal sinuses: case report and review of the literature. *Laryngoscope* 1963; 73:942-953.
6. Patel MG, Thinakkal R, Soboroff BJ et al. Renal metastatic epistaxis: case report and update of literature. *Illinois Med J* 1980; 158:335-339.

Author Information

Pradipta Kumar Parida, MS, DNB

Senior Resident ENT, Department of Otorhinolaryngology and Head & Neck Surgery, Postgraduate Institute of Medical Education and Research

Ramandeep Singh Virk, MS

Assistant Professor ENT, Department of Otorhinolaryngology and Head & Neck Surgery, Postgraduate Institute of Medical Education and Research

Anish Gupta, MS, DNB

Senior Resident ENT, Department of Otorhinolaryngology and Head & Neck Surgery, Postgraduate Institute of Medical Education and Research