

CSF Rhinorrhoea after Transsphenoidal Surgery

E Elgamal

Citation

E Elgamal. *CSF Rhinorrhoea after Transsphenoidal Surgery*. The Internet Journal of Neurosurgery. 2007 Volume 5 Number 1.

Abstract

Objectives: The author investigated the incidence, risk factors, prevention and management of post-transsphenoidal cerebrospinal fluid (CSF) rhinorrhoea in 146 cases with sellar lesions.

Patients and Methods: A review was conducted of 146 consecutive patients who underwent transsphenoidal (TSS) surgery for mainly pituitary adenomas, or other lesions such as craniopharyngioma, Rathk's cleft cyst, meningioma or chordoma in the sella turcica that performed between January 1995 and December 2007 in King Khalid University Hospital, Riyadh, Saudi Arabia.

Results: Four CSF leaks (2.7%) developed within 7 days after TSS surgery for pituitary adenoma, two were prolactin-secreting, and the other two were non-secretory macroadenomas. One patient with Cushing syndrome developed CSF leak 30 days after TSS surgery. Intra-operative CSF leak was encountered in 31 cases (21%), and insertion of lumbar CSF drain was effective in treating them. Post-operative CSF leak occurred in none of the 31 cases using preventive lumbar CSF drainage, but observed in 4 out of 115 cases without lumbar drain ($P < 0.01$). Lumbar CSF drainage was also effective in the treatment of the postoperative CSF leaks; it cured 4 early CSF leaks out of 5 cases. The case with late CSF leaks needed surgical repair.

Conclusion: When a CSF leak is encountered during TSS procedure, meticulous layered closure of the defect and re-enforcement with tissue glue and fat graft, in addition to insertion of CSF lumbar drain, is necessary to reduce the incidence of postoperative CSF leak.

INTRODUCTION

Transsphenoidal (TSS) surgery remains the mainstay of diagnostic and therapeutic management for many types of pituitary and sellar lesions, because of its high success rate and low rate of morbidity and mortality. [1,2] It provides the means of obtaining at least a descent tissue sample for pathological assessment, a mechanism for effective cytoreduction, and a way of decompressing the optic chiasm and reducing mass effect of large tumors.[3]

The main non-endocrine postoperative potential complication with TSS approach is CSF leak.[1,4,5] It can occur several days or weeks after surgery through a defect in the arachnoid, or secondary to meningitis. The opening in the dura allows CSF to drain through the nose. According to Sudhakar et al, [6] the incidence of CSF leak after TSS surgery is 1.5%- 4.2%.

A tear in the arachnoid may be an unavoidable complication of removing pituitary tumor through a TSS approach. A

large pituitary tumor may press against the arachnoid causing thinning and weakness in such that when the tumor is removed the pressure of CSF behind the arachnoid is sufficient to rupture a pathologically rarefied membrane. [6]

Cerebrospinal fluid leakage is noted at the time of surgery following resection of the pituitary adenoma or other sellar lesions, as the arachnoid descends to fill in the sometimes a large empty space around the tumor. Sometimes, CSF leak is recognized immediately after surgery when the patient feels a salty taste in his throat or by dripping of clear fluid from one or both nostrils. Nasal packing usually mask CSF leak for few days. Postoperative CSF leak may not be evident until after the nasal packs are removed and the patient is sent home. Delayed CSF leak following TSS surgery is occasionally apparent only weeks or months after surgery. In these cases there is often a slowly enlarging defect in the arachnoid. [7]

If CSF leak is seen in the surgical field, a lumbar drain is usually inserted to allow healing at the operative site by

decreasing CSF volume and pressure. A CSF leak following TSS surgery is associated with increased morbidity and mortality. However, most leaks heal spontaneously within 7-10 days. [7] Conservative treatments include cautioning patients not to blow their nose and avoid sneezing, coughing, or any activities that stimulate straining, bed rest, with elevation of the head of bed at 30° for several days, is also beneficial. [8]

CLINICAL MATERIAL AND METHODS

PATIENT POPULATION

The cases in this retrospective review were obtained from a prospectively acquired database of 146 patients who underwent TSS surgery at King Khalid University Hospital, Riyadh, Saudi Arabia, between January 1995 and December 2007. The diagnosis of sellar lesion was made on the basis of clinical features of patients, with or without abnormal hormonal assay and confirmed by the presence of a mass in the pituitary fossa at MRI. Other sellar lesions such as craniopharyngioma, Rathk's cyst, and meningioma are also seen clearly in the MRI. All patients underwent TSS, histological and immunohistochemical examination of the tissues obtained, was performed in all cases. Patients were followed regularly with evaluation of the pituitary function and a MRI scan, as appropriate. Recurrence of pituitary adenoma was defined as a secondary failure to meet the criteria of biochemical remission for different secreting tumour, and/or radiological confirmation by MRI.

In the event of a CSF leak during surgery, it was usually at the end of the case after the majority of the tumor had already been removed. A small fat graft was harvested from the lateral thigh and placed in the sella, followed by a small piece of bone then fibrin glue to seal another fat graft in the sphenoid sinus. Lumbar drainage was routinely used in all cases with obvious CSF leak for a period of 3-5 days postoperatively. All patients were followed up at least for 6 months after TSS. Peroperative insertion of lumbar drain was used for all large sellar tumours treated by TSS approach, particularly when there is a radiological suspicious dural involvement or invasion [Figure 1 (a,b,c)].

Figure 1

Figure 1a: T2WI coronal MRI showing large sellar tumour

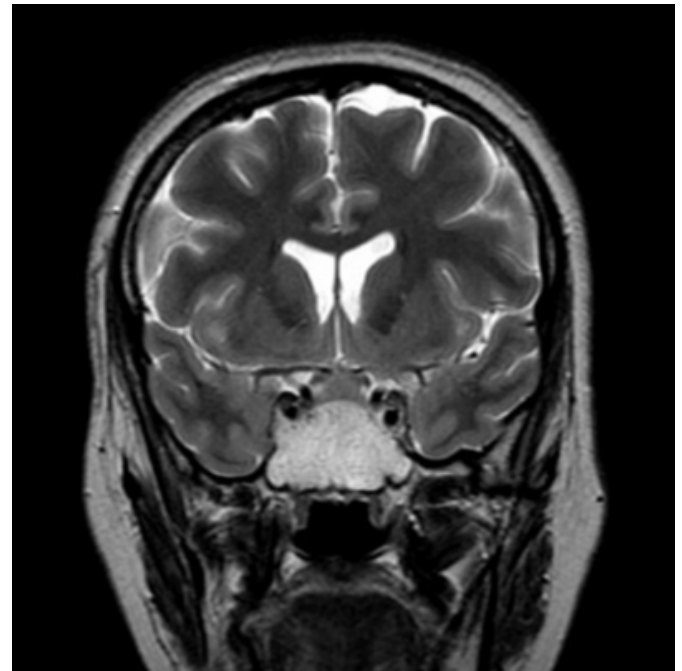


Figure 2

Figure 1b: T1WI Sagittal MRI showing; large tumour filling the sella and extending intradurally in front of the brain stem

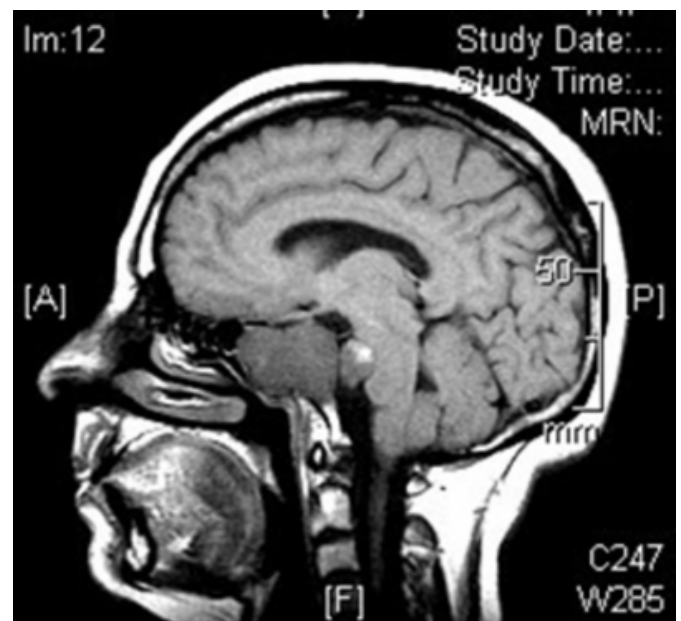
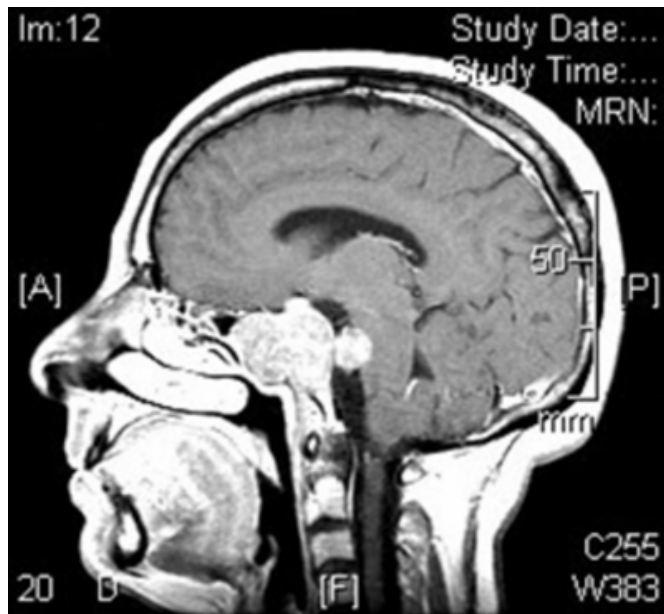


Figure 3

Figure 1c: T1WI Sagittal MRI after intravenous contrast showing; enhancement of the tumour and its intradural component in front of the brain stem.



RESULTS

Of the 146 patients included in the study, 105 (72%) were undergoing their first TSS operation, and 41 (28%) had undergone at least one previous operation via this approach and 6/146 received radiation therapy for residual or recurrent pituitary adenoma. Age ranged between 16 and 83 years and male to female ratio was approximately 1:1.

Intra-operative CSF leak was encountered in 31 cases (21%), and lumbar CSF drain was useful in treating all of them and preventing further postoperative leak. Four patients (2.7%) developed CSF leak within 7 days after TSS surgery for pituitary adenoma, and one developed 30 days after surgery. All of them were giant, two were prolactin-secreting and the other two were non-secreting macroadenomas.

Cerebrospinal fluid leak occurred after 4 weeks from TSS for ACTH-producing microadenoma. Post-operative CSF leak occurred in none of 31 cases using preventive lumbar CSF drainage and in 4 out of 115 cases without it ($P < 0.01$). Lumbar CSF drainage was also effective in the treatment of postoperative CSF leaks; it cured 4 out of 5 CSF leaks. All of them had early CSF leak, and the case with late CSF leaks needed surgical treatment.

Of the original 146 cases underwent TSS surgery, histological diagnosis in 122 found to be pituitary adenoma, and 24 were for other sellar pathology (Table I). Follow-up for the first 6 months after surgery was obtained for 112,

with a median follow-up time of 3.3 year (range, 0.6 –10.1 years). Of these patients, 54 were followed for 5 years or more. No other patients experienced CSF leak or meningitis during the period of follow up.

Figure 4

Table: Histological classifications of sellar lesions in 146 patients treated by Transsphenoidal approach.

Diagnosis	no.	Early CSF Leak	Late CSF Leak
I Pituitary adenoma			
Non-secretory adenoma	40	2	
G-H secreting adenoma	24		
Prolactinoma	20	2	
ACTH - secreting adenoma	12		1
Gonadotroph secreting adenoma	8		
TSH secreting adenoma	1		
Recurrent pituitary adenoma	17		
Total Pituitary Adenomas	122		
Recurrent Irradiated adenoma	6		
II Craniopharyngioma	18		
III Other pathology	6		
Rathk's cyst	1		
Meningioma	1		
Chordoma	1		
Aspergillosis	1		
Myeloma	1		
Non-conclusive	1		
Total Sellar lesions	146	4	1

DISCUSSION

Transsphenoidal route is used to approach most sellar lesions such as pituitary adenoma, craniopharyngioma, Rathk's cleft cyst, mucocele, metastatic tumor, optic or hypothalamus glioma, meningioma, and chordoma. It could be the initial surgical choice for most sellar lesions if the predominant portion is intrasellar. Often, the suprasellar component can be delivered into the sella and evacuated. This approach is well tolerated by patients and is preferable to a craniotomy, when feasible. [8,9]

Cerebrospinal fluid rhinorrhoea following TSS surgery may result from intra-operative rupture of the diaphragma sellae, either by manipulation or by the tumor itself, and/or from inadequate repair of intra-operative leaks or an occult dural injury. Because of the microbiologic nature of the nasal cavity and its continuity with the rest of the upper respiratory and upper digestive tracts, and communication with the intracranial contents, leakage of CSF into the nasal cavity, can lead to meningitis and other intracranial complications, including serious and sometimes lethal medical problems. [10]

The incidence of cerebrospinal fluid fistula following TSS

surgery is low and ranges from 1 to 3% in major series. [11] In our series the incidence of CSF leak after TSS (3.4%) was nearly similar. In the majority of cases, particularly when the diaphragma sellae is intact, no major reconstruction of the sellar dural defect is necessary. Most CSF leaks heal spontaneously within 7-10 days, [7] and conservative treatments usually include cautioning patients not to blow their nose and avoid sneezing, coughing, or any activities that stimulate straining. Bed rest, with the head of bed elevated at 30° for several days, is also beneficial. [8]

A lumbar drain may be inserted to allow healing at the operative site by decreasing CSF volume and pressure. The lumbar drain is usually inserted if CSF is seen in the surgical field or persists with bed rest. Nurses should tell patients and families to ask for assistance in closing the lumbar drainage system before standing and before any other position change or ambulation, so as to prevent overdrainage headaches and accidental disconnection of the lumbar drain system. Assessment for changes in mentation and watching for signs and symptoms of meningitis are also indicated. In 31 patients (21%) lumbar drains was used routinely when significant CSF was seen during TSS, and was successful in prevention of post-operative CSF leak. [7,8]

A variety of methods of reconstruction of the sellar floor have been recommended, Most surgeons use autologous tissues such as muscle, fat, fascia, and a range of synthetic material. [7,8,12] In our unit it is routinely to use a piece of fat usually obtained from the right thigh of the patients, and a layered closure technique using oxidized cellulose (Surgicel)®, Tisseel® fibrin glue along with a piece of bone from the septum. This technique had worked very well and could explain the low rate (3.4%) of post-operative CSF leak in our series. As a matter of fact, the use of autologous grafting usually necessitates a separate incision, prolongs operative time, causes additional discomfort to the patient, and produces thigh scars that can be cosmetically unappealing. However, apart from minimal postoperative discomfort in some of our patients no major complication reported. On the other hand, although an additional incision can be avoided by using synthetic material, these foreign bodies may cause a host reaction, serve as a nidus for infection, or complicate postoperative imaging. [13,14]

The author believes that the risk of CSF rhinorrhoea after TSS is largely related to surgical experience of operator and tumor characteristics. Immediate post-operative CSF leak usually results from inadequate repair of intra-op leaks or

occult dural injury.

The author recommends that neurosurgeons should pay a special attention when dealing with large tumours expanding the sella, recurrent tumours or irradiated sella, and when CSF leak is seen pre or intraoperatively. Pituitary surgeons should avoid opening the sphenoid too far superiorly, they have to recognize the diaphragma (often by its blue color), and do their best to close adequately using a variety of materials, e.g. fibrin glue, autologous fat graft. The use of Valsalva maneuver is sometimes useful to check repair. The author believes also that a pre- or post-operative lumbar drain can effectively reduce the risk of CSF leak.

Cerebrospinal leak was seen in 4 patients, all of them with a very large adenoma, indicating that large sellar solid tumours are at a higher risk of developing CSF leak. The late CSF leak presentation was a microadenoma in patient with Cushing's syndrome, this could be attributed to the disease itself and the effect of disturbed steroid levels. Non of the irradiated cases developed post-operative rhinorrhea.

CONCLUSION

Meticulous layered closure after TSS surgery, particularly for large solid tumours, is the most important factor for prevention of postoperative CSF leak. Lumbar drain should be inserted for all patients when CSF is seen during TSS, and kept for 3-5 days after surgery. Surgical repair should be considered for patients with late CSF leak after TSS.

References

1. Jane JA Jr, Laws ER Jr: The surgical management of pituitary adenomas in a series of 3,093 patients, *J Am Coll Surg* 2001;193: 651-659.
2. Jane JA Jr, Thapar K, Alden TD, Laws ER Jr: Fluoroscopic frameless stereotaxy for transsphenoidal surgery. *Neurosurgery* 2001;48:1302-1308.
3. Elias WJ, Chaddock JB, Alden TD, Laws ER Jr: Frameless stereotaxy for transsphenoidal surgery. *Neurosurgery* 1999;45: 271-277.
4. Black PM, Zervas NT, Candia GL: Incidence and management of complications of transsphenoidal operation for pituitary adenomas. *Neurosurgery* 1987;20: 920-924.
5. Ciric I, Ragin A, Baumgartner C, et al: Complications of transsphenoidal surgery: results of a national survey, review of the literature, and personal experience. *Neurosurgery* 1997;40: 225-237.
6. Sudhakar, N., Ray, A., & Vafidis, J. A. Complications after trans-sphenoidal surgery: Our experience and a review of literature. *British Journal of Neurosurgery* 2004;18, 507-512.
7. Kerr, J. T., Chu, F. W. K., & Bayles, S. W. Cerebrospinal fluid rhinorrhea: Diagnosis and management. *Otolaryngologic Clinics of North America* 2005; 38, 597-611.
8. Couldwell WT, Weiss MH, Rabb C, Liu JK, Apfelbaum RI, Fukushima T. Variations on the standard transsphenoidal

approach to the sellar region, with emphasis on the extended approaches and parasellar approaches: surgical experience in 105 cases. *Neurosurgery* 2004;55:539-547.

9. Dhellemmes P, Vinchon M. Radical resection for craniopharyngiomas in children: surgical technique and clinical results. *J Pediatr Endocrinol Metab* 2006;19 Suppl 1:329-35.

10. Ciric I, Ragin A, Baumgartner C, Pierce D. Complications of transsphenoidal surgery: results of a national survey, review with literature, and personal experience. *Neurosurgery* 1997;40:225 - 37.

11. Goel A, Muzumdar DP. Reconstruction of the sella floor

using vascularized pedicled mucosal flap. *Br J Neurosurg* 2003 Dec;17(6):553-5.

12. Hardy J, McCutcheon IE: Pituitary microadenomas, in Apuzzo MLJ (ed): *Brain Surgery: Complication Avoidance and Management*. New York: Churchill Livingstone, 1993, Vol 1, pp 271-295.

13. Couldwell WT, Kan P, Weiss MH. Simple Closure Following Transsphenoidal Surgery. Technical Note. *Neurosurg Focus* 2006;20(3):E11.

14. Freidberg SR, Hybels RL, Bohigian RK. Closure of cerebrospinal fluid leakage after transphenoidal surgery. Technical note. *J Neurosurg* 1994;35:159 - 60.

Author Information

Essam A. Elgamal, SN

Assistant Professor and Consultant, Neurosurgery Division, College of Medicine & King Khalid University Hospital,