

Postoperative Paraplegia after Nonvascular Thoracic Surgery

K Popat, T Ngyugen, A Kowalski, M Daley, J Arens, D Thakar

Citation

K Popat, T Ngyugen, A Kowalski, M Daley, J Arens, D Thakar. *Postoperative Paraplegia after Nonvascular Thoracic Surgery*. The Internet Journal of Anesthesiology. 2003 Volume 8 Number 1.

Abstract

We describe two cases of paraplegia secondary to spinal cord ischemia after thoracic surgery. After reviewing the literature, we report potential risk factors and the clinical scenarios that put patients at higher risk of spinal cord ischemia. Based on these two cases, nursing practice was revised for this susceptible group (>58 years of age, male sex, atherosclerotic disease, diabetes, hypertension and obesity) at our institution, and we were able to rapidly diagnose and successfully treat paraparesis in another patient, without any neurologic sequel. This report emphasizes the importance of vigilant neurologic and hemodynamic monitoring in patients whose intravascular volume is depleted.

CASE REPORTS

Paraplegia after nonvascular thoracic surgery occurs in 0.08% of cases, and the incidence of spontaneous spinal cord ischemia is unknown (1). Thankfully, these adverse events are very rare, but as we state in this report, they are more likely to occur in certain scenarios and disease processes; therefore, such cases require additional vigilance. We describe two cases of postoperative paraplegia secondary to spinal cord ischemia and discuss the changes in our patient-care policy that resulted from them.

CASE 1

A 74-year-old man with osteosarcoma of the right chest wall and a history of non-insulin-dependent diabetes, hypercholesterolemia, and chemotherapy with doxorubicin had a right chest wall resection, a partial rib resection (2,3,4,5), and a pleurectomy. The patient had an epidural catheter placed intraoperatively for postoperative pain control. During surgery, the patient lost 1000cm³ of blood and had periods of transient hypotension. These were treated with blood, crystalloids, and phenylephrine. Postoperatively, the patient was moving all extremities, and an epidural infusion (0.075% bupivacaine and 10 mcg/ml fentanyl) was started. The patient was given furosemide for diuresis the first night. Twenty-four hours postoperatively, the patient was found to have acute paraplegia with intact fine-touch sensation above T10. The epidural infusion was stopped. When the patient's condition did not improve, a magnetic resonance image (MRI) of the spine was taken 4 hours after the onset of the

neurologic deficit. The MRI initially came back normal but was later reported as "Early ischemic changes in the mid-thoracic spinal cord, mainly in the ventral area." The patient underwent aggressive treatment with intravenous fluids and was started on intravenous steroids, without any improvement in his neurologic status. It was determined from the radiologic and clinical findings that the patient had spinal cord ischemia secondary to anterior spinal artery thrombosis.

CASE 2

A 62-year-old man with recurrent lung adenocarcinoma and a history of two myocardial infarctions, carotid artery occlusive disease, peripheral vascular disease, hypertension, borderline adult onset diabetes mellitus, and heavy smoking and alcohol consumption underwent a right thoracotomy, pericardiocentesis, extended wedge resection of the right lung, and pectoralis major flap reconstruction.

Preoperatively, a thoracic epidural catheter was placed between T7 and T8. The surgery proceeded smoothly, except for periods of transient hypotension that the patient experienced. An epidural infusion of 0.075% bupivacaine and 10 mcg/ml fentanyl was started prior to extubation. The patient's recovery in the post-anesthesia care unit was uneventful, and he was discharged to the floor 4 hours later. At that time, he was moving all four extremities without pain.

About 18 hours after surgery, the patient was found to have

acute flaccid paraplegia, no rectal tone, and no sensation below T9. The epidural infusion was stopped, the catheter removed, and an MRI of the spine was obtained. The spinal MRI (T3-L1) showed abnormal T2-weighted signal hyperintensity at the mid to lower thoracic cord level, suggesting an edematous or ischemic process. No hematoma was present. The correct epidural solution was confirmed by laboratory analysis.

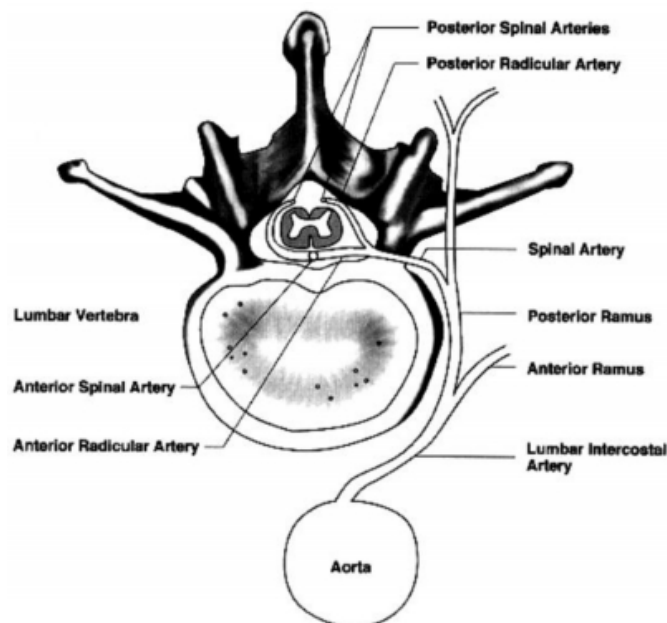
DISCUSSION

Paraplegia is a devastating postoperative complication. Its causes include epidural abscess, epidural hematoma, intrathecal migration of an epidural catheter, local anesthetic neurotoxicity, trauma to the spinal cord, and spinal cord ischemia. The two cases reported here were the result of spinal cord ischemia.

The blood supply to the spinal cord is from richly interwoven anastomoses of the anterior and posterior spinal arteries. Along its discontinuous course, the anterior spinal artery receives input from six to nine radicular arteries. The most significant of these is the arteria radicularis magna, which usually arises on the left between T5 and L2 (6) (See Fig. 1).

Figure 1

Figure 1: Extrinsic arterial supply to the spinal cord. Radicular arteries at various levels join to form the discontinuous anterior spinal artery, which connects via the spinal arterial plexus to the pair of posterior spinal arteries. The anterior spinal artery arises rostrally from branches of the vertebral arteries and caudally from the great radicular artery of Adamkiewicz. Neurology, Aug 1996;47(2):321-330 FG1



Relative hypovascularity exists between T4 and T8 because of fewer anastomoses between the anterior and posterior spinal arteries (6). Infarction is more common in the anterior than in the posterior spinal cord. The clinical presentation of spinal cord ischemia includes flaccid paraplegia (6), areflexia, loss of pain and temperature sensation, and autonomic deficits (e.g., atonic bladder). Factors affecting spinal cord blood flow are shown in Table 1.

Figure 2

Table 1:

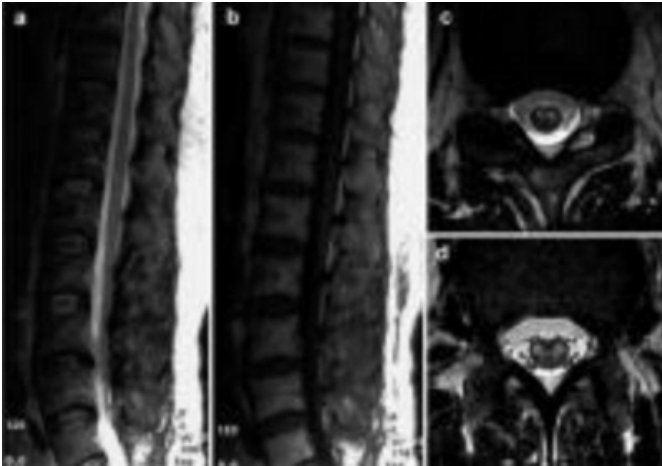
Factors Affecting Spinal Cord Blood Flow	
Iatrogenic	Natural
INTRAOPERATIVE Lateral flexion of spine secondary to thoracic spine Thoracic vascular surgery Posteriolateral thoracotomy Left thoracotomy (2,5) Attempts to control bleeding at costovertebral angle using oxidized cellulose Ligation of intercostal vessels (5,6) Hypotension Blood loss (2-5) Direct trauma to spinal cord during surgery or epidural placement POSTOPERATIVE Hypotension (2-5) Compression epidural hematoma or surgical hematoma (5,7) Vasoconstrictors in epidural infusion (7)	Atherosclerosis Polycythemia (1,2) Anatomic changes of the spine (Kyphoscoliosis) Vascular malformation Infection Hypercoagulability (1)

Of patients with spinal cord ischemia only 23% improve significantly (6). Thus, it is extremely important to recognize the risk factors of spinal cord ischemia, which include age >58 years, male sex, atherosclerotic disease, diabetes, hypertension, and obesity (7).

A diagnosis of spinal cord ischemia is made based on clinical suspicion and an MRI of the spine (Fig. 2).

Figure 3

Figure 2: Sagittal T2-weighted (A) and T1-weighted (B) images in a case of thoracolumbar spinal cord infarction with “pencil-like” hyperintensities on T2-weighted images (A) without cord swelling (B). Axial T2-weighted images at T9 (C) showing bilateral hyperintensities corresponding to the anterior horns of grey matter (“snake eyes”). Axial T2-weighted images at T12 (D) showing hyperintensities in the grey and white matter of the cord. *Neuroradiology* 2002, Oct;44(10):851-7



Treatment includes fluid resuscitation and achieving hemodynamic stability. The role of early steroid administration is questionable.

Because of the cases described above, the standard of care for nursing practice was revised at our institution, and three new policies were developed and implemented for all patients with an epidural catheter:

Unit nurses caring for patients with epidural catheters have expanded their assessments: lower extremity weakness, paresthesia, and neurologic changes are evaluated every 4 hours along with vital signs;

Two registered nurses are required to verify the patient's medication regimen at given intervals; and

There is increased vigilance when these patients begin walking after surgery, with documentation of orthostatic blood pressures.

Since implementing these measures, we have had one case of transient paraparesis, which was identified quickly. The patient was treated aggressively with fluid resuscitation and regained full neurologic function.

CORRESPONDENCE TO

Keyuri U. Popat, M.D. 1515 Holcombe Blvd., Unit 42

Houston, Texas 77030 Phone: (713) 792-6902 E-mail:
kupopat@mdanderson.org

References

1. Cheshire WP, Santos CC, Massey EW, Howard JF. Spinal cord infarction: etiology and outcome. *Neurology* 1996;47(2):321-30.
2. Marsad MG, Donahue PE, Rubeiz H, et al. Paraplegia after esophagectomy: who are the patients at risk? *J Thorac Cardiovasc Surg* 2001;121(2):386-8.
3. Urquhart-Hay D. Paraplegia following epidural analgesia. *Anesthesiology* 1969;24(3):461-70.
4. Bhuiyan MS, Mallick A, Parsloe M. Post-thoracotomy paraplegia coincident with epidural anaesthesia. *Anesthesiology* 1998;53:580-8.
5. Attar S, Hankins JR, Turney SZ, et al. Paraplegia after thoracotomy: report of five cases and review of the literature. *Ann Thorac Surg* 1995;59:1410-6.
6. Kane RE. Neurologic deficit following epidural and spinal anesthesia. *Anesth Analg* 1981;60(3):150-61.
7. Skouen JS, Wainapel SF, Willock MM. Paraplegia following epidural anesthesia. *Acta Neurol Scand* 1985;72(4):437-43.

Author Information

Keyuri U. Popat, M.D. (ABA)

Department of Anesthesiology, M. D. Anderson Cancer Center, University of Texas

Thuy Ngyugen, M.D.

Department of Anesthesiology, M. D. Anderson Cancer Center, University of Texas

Alicia M. Kowalski, M.D.

Department of Anesthesiology, M. D. Anderson Cancer Center, University of Texas

Mary D. Daley, M.D.

Department of Anesthesiology, M. D. Anderson Cancer Center, University of Texas

James F. Arens, M.D.

Department of Anesthesiology, M. D. Anderson Cancer Center, University of Texas

Dilip Thakar, M.D.

Department of Anesthesiology, M. D. Anderson Cancer Center, University of Texas