

Giant Cell Tumor Of The Second Metatarsal

S Mahajan, A Shikari, M Habib, G Kuchey, S Sharma

Citation

S Mahajan, A Shikari, M Habib, G Kuchey, S Sharma. *Giant Cell Tumor Of The Second Metatarsal*. The Internet Journal of Orthopedic Surgery. 2008 Volume 11 Number 1.

Abstract

Giant cell tumor (GCT) or osteoclastoma is an osteolytic, mostly benign but locally aggressive tumor occurring in young adults at the epiphysis. Area of predilection is mainly long bones (85-90). 4% of GCT are also found in iliac bone, spine & only 2% in hand (of which GCT phalanges are more common than metacarpal). GCT of metatarsal is a very rare occurrence with very few cases has been reported so far. We report a case of GCT 2nd metatarsal in a 30 year old female which is a very rare entity. We discuss the clinical features, pathological and radiological hallmarks, and the various treatment modalities of such lesion

INTRODUCTION

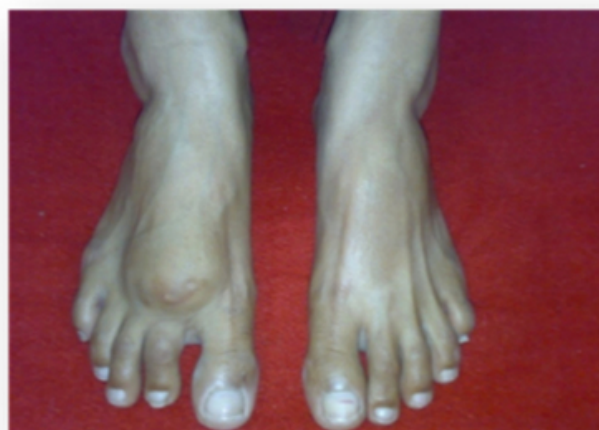Giant cell tumor (GCT) of bone is a benign, aggressive tumor with features of frequent local recurrences and the potential for the metastasis and the malignant transformation. It usually occurs in young adult of 16-35 years in the physal region. The male to female ratio is 3:5. Nearly 85-90% found in long bones, of which 50% occur in the region of knee. Other frequent sites are distal radius, proximal humerus and fibula. 4% occur in pelvic bone and spine. Involvement of small bones of hand and foot is very rare. Unni has reported an incidence of 2% in the hand and 1.5 % in the foot (phalanges being more involved than metacarpals and metatarsals). We are presenting a case of GCT of 2nd metatarsal of right foot which is a very rare site for such tumor.

CASE REPORT

A 30-years- old female presented to us with the chief complaints of swelling over the dorsum of right foot for the duration of 2 years and pain in that foot for 4 months. Swelling was insidious in onset and has progressively increased in size. Pain was mild to moderate in intensity, dull aching, continuous relieved by taking medication and rest, aggravated by activity. There is no history of any constitutional symptoms and trauma.

Figure 1

Figure 1



On physical examination, there was a localised ovoid shaped swelling 8 by 4 cm over the dorsum of right foot opposing 2nd & 3rd metatarsal area with well defined margins and overlying skin stretched and there was shortening of the second toe also. Swelling was tender on deep palpation, hard in consistency, overlying skin was free.

Radiographs revealed an expansile osteolytic lesion of whole 2nd metatarsal involving the articular surface of tarso-metatarso joint and metatarso-phalangeal joint with impingement on 3rd metatarsal with cortical thinning. The classical 'soap bubble appearance' also present.

Figure 2

Figure 2

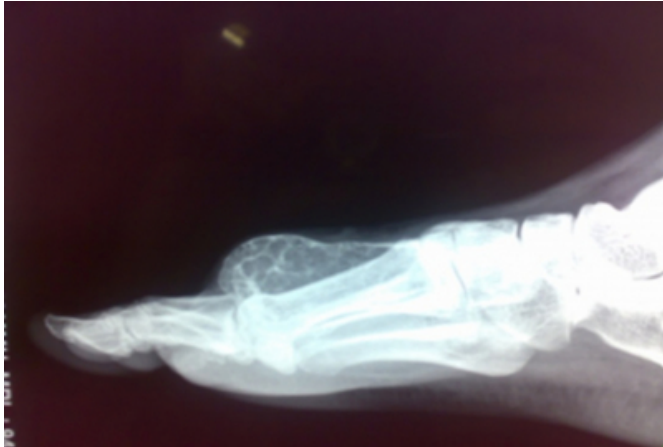
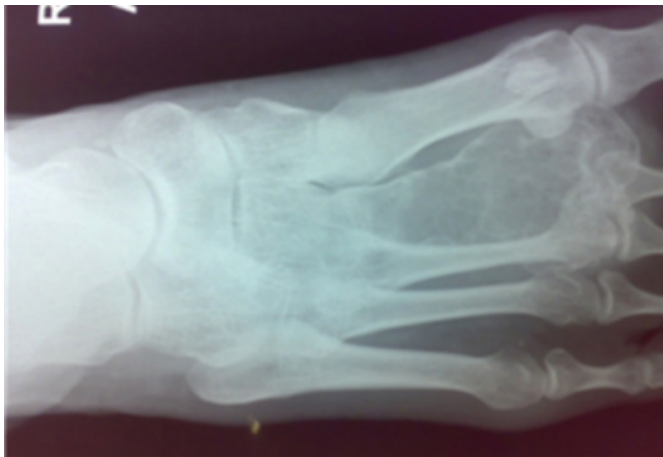
Figure 3

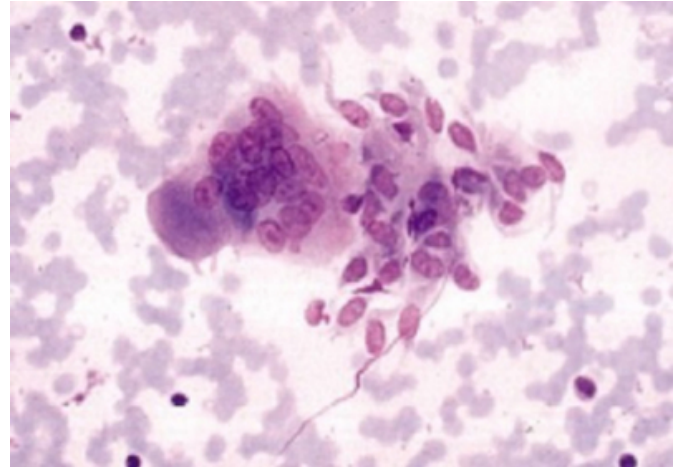
Figure 3



Since we were suspecting giant cell tumor and therefore fine needle aspiration cytology was done to confirm our diagnosis. This tumor had the histological grade according to Campanacci et al was grade II.

Figure 4

Figure 4



A reconstructive surgery with fusion of the cuineformmetatarsal and metatarsophalangeal joint was planned. The tumor was carefully removed with a cuff of normal tissue and the proximal and distal joints inspected. There was no articular cartilage of the cuineformmetatarsal joint. A fibular graft was taken and was inserted into the troughs created in middle cuineform and proximal phalanx and fixed with K-wire, both proximally and distally. The patient was given a below knee cast for three months post operatively. Full weight bearing was started after 3 months. After 9 months of follow-up, the graft was well taken up and there were no signs of recurrence both clinically and radiologically.

DISCUSSION

Giant cell tumor of the bone is a benign, but locally aggressive lesion. It is a relatively rare tumor composed of connective tissue stromal cells having the capacity to recruit and interact with multinucleated giant cells that exhibit the phenotypic features of osteoclasts. [1]

Giant cell tumor predominates in the long bones [75-90% of cases] especially the femur [approximately 30% cases], tibia [25% cases], radius [10% cases] and humerus [6% cases]. The spine and innominate bone are involved occasional. Giant cell tumors of the bones of the hand are rare accounting for only 2% of cases and here too phalangeal location of the tumor is more common than metacarpals. GCT of foot is even rarer than GCT of hand. GCT of the hand & foot seems to represent a different lesion than conventional GCT in the rest of the skeleton [1,6,9]. There is an 18% incidence of multicentric foci [7] indicating that a bone scan should be a part of routine workup of these

tumors. Overall they appear in a younger age group. They also have a shorter duration of symptoms averaging six months or less before a diagnosis is made. [5,9]

Also Differential considerations based on the appearance and location of this tumor included giant cell tumor, giant cell reparative granuloma, aneurysmal bone cyst, chondromyxoid fibroma, brown tumor of hyperparathyroidism, angiosarcoma, myeloma, and an expansile metastatic lesion, such as renal cell carcinoma must be taken into consideration

Despite the fact the GCT is not a sarcoma, the extent of tumor at the time of diagnosis and the high recurrence rate following limited resection often dictate the need of an enbloc resection through normal tissues to prevent local recurrence of the lesion. Such a treatment creates a significant skeletal defect and a challenging reconstructive problem. Reconstruction of the foot after enbloc excision is particularly difficult because of the need to restore the joint surface as well as bone and also foot is the weight bearing area so for the reconstruction bone that match the anatomy of the foot is used. [10]

The various treatment modalities described in literature are curettage, curettage and bone grafting, irradiation, amputation, and resection with reconstruction.

Local resection of the involved metatarsal with autograft or allograft replacement is the preferred surgical treatment for several reasons. First, no correlation has been found between the grade of giant cell tumor and the rate of recurrence. Therefore all giant tumors of foot should be considered locally aggressive. In addition curettage with or without bone grafts has resulted in recurrence rates of about 90%.

Thus curettage is an unacceptable form of treatment. Second, although amputation may prevent recurrence, it is cosmetically deforming and decreases the function of the foot.

CORRESPONDENCE TO

Dr. Sumit Mahajan. 720-A last more Gandhi Nagar, Jammu, J&K Mob no: 094191-89071

Email:mahajan.sumit20@rediffmail.com

References

1. Goldenberg RR, Campbell CJ, Bonfiglio M. Giant cell tumor of bone. An analysis of 218 cases. *Journal of Bone and Joint Surgery [Am]* 1970; 52:619-64.
2. Bone tumors: diagnosis, treatment, and prognosis. Philadelphia, Pa: Saunders, 1991; 429-467.
3. Murphey MD, Nomikos GC, Flemming DJ, Gannon FH, Temple HT, Kransdorf MJ. Imaging of giant cell and giant cell reparative granuloma of bone: radiologic-pathologic correlation. *RadioGraphics* 2001; 21:1283-1309.
4. Dahlin DC, Cupps RE, Johnson EW. Giant-cell tumor: a study of 195 cases. *Cancer* 1970; 25:1061-1070. [CrossRef][Medline]
5. Cavender RK, Sale WG 3rd. Giant cell tumor of the small bones of the hand and feet: metatarsal giant cell tumor. *W V Med J* 1992; 88:342-345. [Medline]
6. Wold LE, Swee RG. Giant cell tumor of the small bones of the hands and feet. *Semin Diagn Pathol* 1984; 1:173-184. [Medline]
7. Cummins CA, Scarborough MT, Enneking WF. Multicentric giant cell tumor of bone. *Clin Orthop Relat Res* 1996; 322:245-252. [Medline]
8. Khanna AK, Sharma SV, Kumar M. A large metatarsal giant-cell tumor. *Acta Orthop Scand* 1990; 61:271-272. [Medline]
9. Mohan V, Gupta SK, Sharma OP, Varma DN. Giant cell tumor of short tubular bones of the hands and feet. *Indian J Radiol* 1980; 34:14-17.
10. Mendicino SS. Giant cell tumor of the first metatarsal bone en bloc resection with autogenous middle fibular strut graft. *J Foot Ankle Surg* 1993; 32:405-410. [Medline]
11. Burns TP, Weiss M, Snyder M, Hopson CN. Giant cell tumor of the metatarsal. *Foot Ankle* 1988; 8:223-226. [Medline]

Author Information

Sumit Mahajan

Post Graduate in Orthopaedic Surgery, Government Medical College, Jammu

Adil Bashir Shikari

Post Graduate in Orthopaedic Surgery, Government Medical College, Jammu

Masood Habib

Post Graduate in Orthopaedic Surgery, Government Medical College, Jammu

Gluzar Ahmed Kuchey

Post Graduate in Orthopaedic Surgery, Government Medical College, Jammu

Sudesh Sharma

Professor in Orthopaedic Surgery, Government Medical College, Jammu