

Retroperitoneal Candidial Abscess

B Davachi, M Hosseini, T Akhondzadeh, M Zare, M Talaei-Khoei

Citation

B Davachi, M Hosseini, T Akhondzadeh, M Zare, M Talaei-Khoei. *Retroperitoneal Candidial Abscess*. The Internet Journal of Infectious Diseases. 2004 Volume 4 Number 1.

Abstract

A rare case of retroperitoneal candidial abscess is described. The patient was an adult woman with two-month history of vague left flank pain. Physical examination revealed a non-tender mass at the left flank. Imaging findings showed a retroperitoneal mass with central necrosis. On the basis of these findings, the provisional diagnosis of retroperitoneal abscess or sarcoma was made, so percutaneous aspiration was performed and thick purulent secretions were aspirated. The pathologic examination revealed candida albicans abscess.

INTRODUCTION

The most important differential diagnoses of a retroperitoneal mass are benign and malignant neoplasms, pyogenic abscess and hematoma. We report a candida albicans abscess in the retroperitoneum, so when a patients presents with a retroperitoneal mass, it should be borne in mind the possibility of fungal abscess, especially in immunocompromised patients.

CASE REPORT

A 48-year-old female presented with a two-month history of vague left flank pain, referring to the lower back and between the scapulas. Also she noted abdominal distension and lower extremities edema progressing over several months as well as irregular menstrual cycles. She had no irritative symptoms of the genitourinary system such as dysuria or frequency, at presentation. Physical examination showed fullness in abdominal percussion, 2+ edema in lower extremities and a huge non-tender mass at the left flank. The vital signs were normal. There was no evidence of inflammation (erythema and heat) at the left flank.

She had a past history of diabetes mellitus, for which she had been prescribed glibenclamide.

The lab test results were as follows: WBC = 5840/mm³, PMN = 60%, RBC = 3570*10³, Hct = 28, FBS = 250 mg/dl, HbA1c = 11%, AST(SGOT) = 36 mg/dl, ALT(SGPT)=37, Total Bilirubin = 1, Direct Bilirubin = 0.2

CT scan demonstrated an ill-defined mass with central necrosis in the retroperitoneal space at the left side which

had deviated the left kidney and adrenal gland anteriorly. Also it showed splenomegaly and ascites. Selected images are shown in figure 1. On the basis of the imaging findings, the provisional diagnosis of retroperitoneal abscess or sarcoma was made, so percutaneous biopsy was performed and thick purulent secretions were aspirated. The pathologic examination revealed candida albicans abscess. The abscess drainage was performed and fluconazole was prescribed. The patient became well after treatment.

Figure 1

Figures 1-4: Contrast-enhanced CT scan demonstrates an ill-defined mass with central necrosis in the retroperitoneal space at the left side which deviates the left kidney and adrenal gland anteriorly.

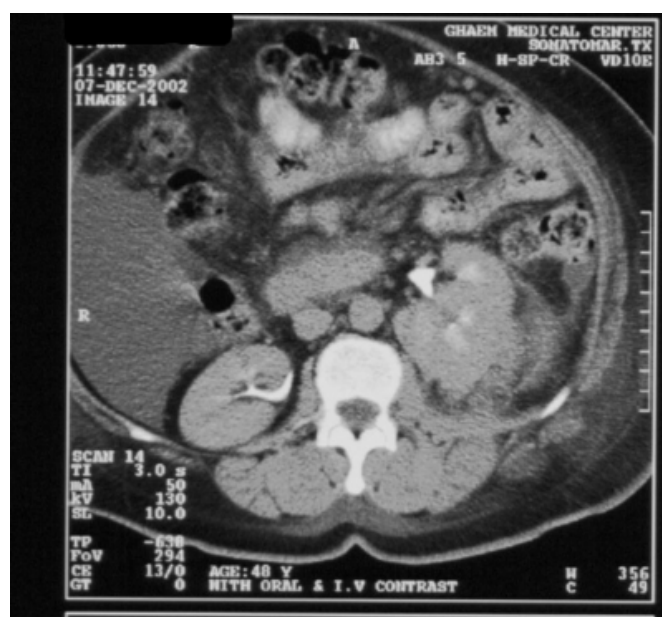


Figure 2

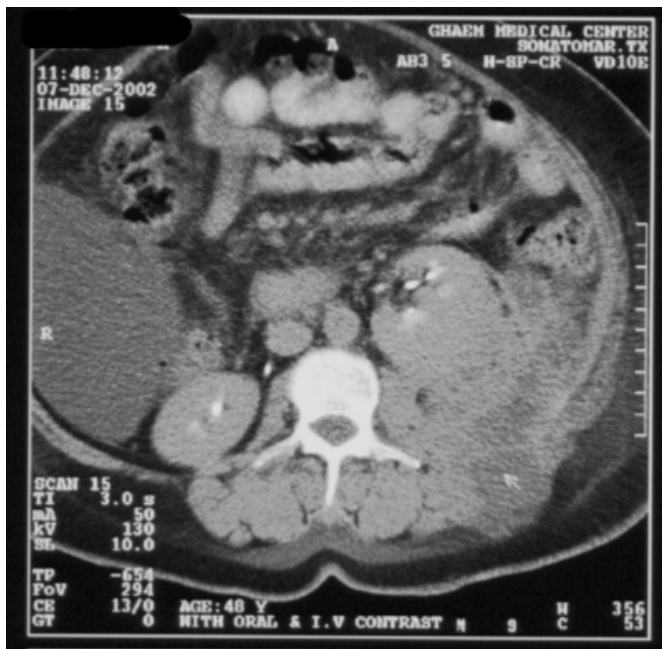


Figure 3

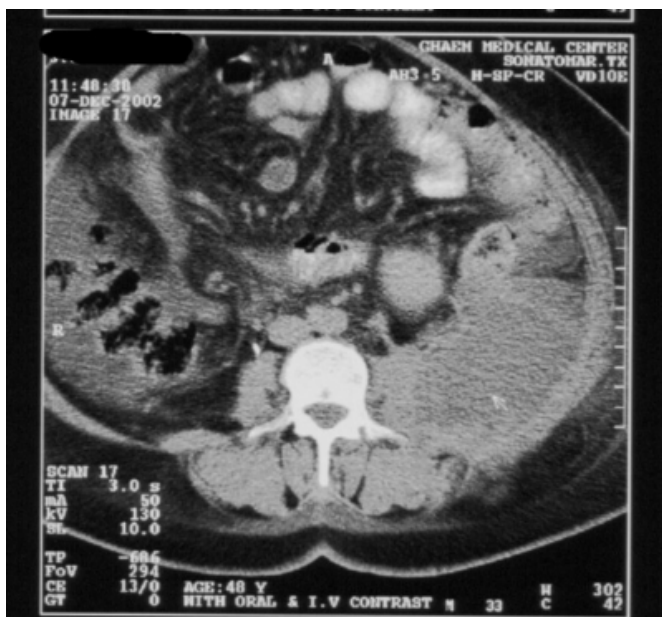
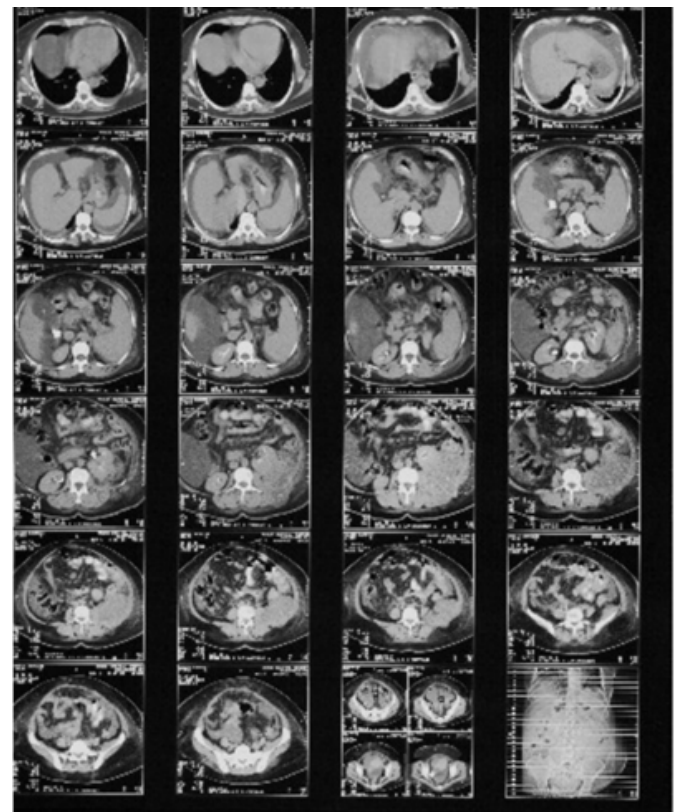


Figure 4



DISCUSSION

Retroperitoneal candidal abscess is a rare disease that has been reported in a few articles [1,2,3,4,5,6,7,8]. This case remember us when a patient presents with a retroperitoneal mass, it should be borne in mind the possibility of fungal abscess, even if there is no evidence of acute infection (especially in immunocompromised patients). Differential diagnoses of a retroperitoneal mass are retroperitoneal benign and malignant neoplasms, pyogenic abscess and hematoma. Candida organisms are yeasts, that is, fungi that exist predominantly in a unicellular form. They are more than 150 species of candida, but only nine are regarded as frequent pathogens for humans. They are *C. albicans*, *C. guilliermondii*, *C. krusei*, *C. parapsilosis*, *C. tropicalis*, *C. pseudotropicalis*, *C. lusitaniae*, *C. dubliniensis* and *C. glabrata* [9].

Candida organisms are yeasts, that is, fungi that exist predominantly in a unicellular form. They are more than 150 species of candida, but only nine are regarded as frequent pathogens for humans. They are *C. albicans*, *C. guilliermondii*, *C. krusei*, *C. parapsilosis*, *C. tropicalis*, *C. pseudotropicalis*, *C. lusitaniae*, *C. dubliniensis* and *C. glabrata* [9]. Candida albicans organisms are the most common and have been recovered from soil, hospital

environments, inanimate objects, and food. However, contamination from humans or animals is probable. The organisms are normal commensals of humans and are commonly found on skin, throughout the entire gastrointestinal tract and in the urine of patients with indwelling Foley catheters [9]. Candidiasis is often preceded by increased colonization of the mouth, vagina and stool with candida due to broad-spectrum antibiotic therapy. Oropharyngeal thrush is particularly likely to occur in neonates and in patients with diabetes mellitus, HIV infection, or denture. Candida from the perineum can enter the urinary tract via an indwelling bladder catheter. Candida can pass from the colonized surface into deep tissue when the integrity of the mucosa or skin is violated as, for example, by perforation of the gastrointestinal tract through trauma, surgery, or peptic ulceration or by mucosal damage due to cytotoxic agents used for cancer chemotherapy [10]. In this case, diabetes mellitus may be the predisposing factor, but the origin of the infection was uncertain. There was no evidence (e.g. leukocytosis, fever, skin erythema) of infection, may be due to diabetes mellitus.

Other differential diagnosis of this case is retroperitoneal neoplasms. Most primary retroperitoneal tumors arise from one or more of the mesenchymal tissues of the retroperitoneum. Others are derived from neuroectodermal elements or from remnants of the urogenital ridge. The great majority of mesenchymal tumors in the retroperitoneum are malignant. Some benign tumors are never discovered during life and many malignant tumors grow to enormous size before their presence is suspected. The commonest primary retroperitoneal benign tumors are lipoma, teratoma, neurogenic tumors and paraganglioma. Lipomas are encapsulated masses composed mostly of mature fat cells [11]. There are no plain film findings to indicate the benign nature of the fatty tumor, but on CT the capsule that defines the outer limits of mass may be seen. Aside from having an occasional thin septum or strand of fibrous tissue, the interior of the mass is homogeneously radiolucent [11].

Benign nerve sheath tumors include schwannomas (neurilemmomas) and neurofibromas. They have similar radiologic features and usually appear as smooth, discrete, round or oval masses.

Teratoma is a cystic mass, so it is not suspected in this case. The most common retroperitoneal malignant tumors are sarcomas, extragonadal germ cell tumors and lymphoma. Sarcomas include 90% of these malignant tumors and the

most common types in order of frequency are liposarcoma, leiomyosarcoma and malignant fibrous histiocytoma (MFH) [12]. Liposarcomas are the most common primary retroperitoneal neoplasms. Lipogenic liposarcomas are of a radiolucency similar to that of normal fat, myxoid liposarcoma occur in range of densities between the densities of fat and muscle, pleomorphic liposarcoma, the least common type have a density similar to that of muscle. Leiomyosarcomas are especially inclined to undergo cystic degeneration. Solid leiomyosarcomatous tissue, on the other hand, tends to be hypervascular [11]. Malignant fibrous histiocytomas tend to be hypervascular and aggressive in their local growth. Calcification is another non-specific finding. Fibrosarcomas and rhabdomyosarcoma appear in young patients, so they are not suspected in this case. With the exception of liposarcoma, which may contain identifiable fat density on CT, the histological type of a soft-tissue sarcoma can not be reliably identified on CT. Areas of necrosis or haemorrhage may result in heterogeneous attenuation within the lesion.

CORRESPONDENCE TO

Mohammadreza Hosseini, MD Department of Radiology, Ghaem Hospital, Ahmadabad street, Mashhad University of Medical Sciences, Mashhad, Iran Fax: +98 511 8409612 Email: mrohosseini@yahoo.com

References

1. Serrano-Heranz R, Hernandez-Muro G, Carbonero P, Santana E. A pancreatic abscess due to candida albicans. *Med Clin (Barc)* 1995; 104(14):558-559.
2. Jalan R, Jones HL, Walker RJ. Multiple pancreatic abscess due to candida albicans following ERCP. *Scott Med J* 1994; 39(1):17-18.
3. Keiser P, Keay S. Candidal pancreatic abscesses: report of two cases. *Clin Infect Dis* 1992; 14(4):884-888.
4. Edelstein HE, McCabe RE, Lieberman E. Perinephric abscess in renal transplant recipients: report seven cases. *Rev Infect Dis* 1989; 11(4):569-577.
5. Fukuhara S, Nishimura K, Yoshimura K, et al. A case of psoas abscess caused by candida albicans. *Hinyokika Kyo* 2003; 49(3):141-143.
6. Howard JM, Bieluch VM. Pancreatic abscess secondary to candida albicans. *Pancreas* 1989; 4(1):720-722.
7. Guastalla PD, Alessandrini H, Pini M, Giannotta A. Multiple splenic and renal abscesses in candida albicans infection. *Radiol Med (Torino)* 1984; 70(9):697-698.
8. Pigrau Serrallach C, Bosch Gil, Ordi Ros J, Tornó Salanó J. Perinephric abscess caused by Candida. *Rev Clin Esp* 1981; 163(2):121-122.
9. Edward JE. Candidal infections. In: Mandell GL, Bennett JE, Dolin R, 5th ed. *Principles and practice of infectious diseases*. 5th ed. Philadelphia: Harcourt Health Sciences Company, 2000:2656-9.
10. Bennett JE. Candida albicans. In: Fauci AS et al, eds. *Harrison's Principles of Internal Medicine*, 15th ed. United States of America: McGraw-Hill Inc., 2001: 1176-9.

11. Stephens DH. Retroperitoneal masses. In: Taveras JM, Ferrucci JT, eds. Radiology, revised ed. Philadelphia: JB Lippincott Company, 1989:3-8.

12. Sutton D, Robinson PJA. The adrenal glands. In: Sutton D, ed. Radiology and Imaging ,7th ed. London: Churchill Livingstone, 2003:845-8.

Author Information

Behrooz Davachi, M.D.

Department of Radiology, Ghaem Hospital, Mashhad University of Medical Sciences

Mohammadreza Hosseini, M.D.

Department of Radiology, Ghaem Hospital, Mashhad University of Medical Sciences

Taher Akhondzadeh, M.D.

Department of Radiology, Ghaem Hospital, Mashhad University of Medical Sciences

Mohammad A. Zare, M.D.

Department of Radiology, Ghaem Hospital, Mashhad University of Medical Sciences

Mojtaba Talaei-Khoei, M.D.

Department of Radiology, Ghaem Hospital, Mashhad University of Medical Sciences