

Methods for human identification in Forensic Dentistry: A Review

C Stavrianos, I Stavrianou, E Dietrich, P Kafas

Citation

C Stavrianos, I Stavrianou, E Dietrich, P Kafas. *Methods for human identification in Forensic Dentistry: A Review*. The Internet Journal of Forensic Science. 2008 Volume 4 Number 1.

Abstract

The contribution of dentistry to human identification takes two main forms: the identification of human remains according to dental records existing antemortem, and a postmortem dental profiling in cases where there are no antemortem records. This review analyzed the available basic methods of human identification.

INTRODUCTION

Defining forensic dentistry means including two definitions: human identification and bite marks ¹. In this way dentistry can contribute to the identification of human remains after disasters or crimes, assisting other medical specialties. It must be mentioned that forensic medicine plays the role of the last counsel of defence, by helping to ascertain the circumstances of death.

The contribution of dentistry to human identification takes two main forms: the identification of human remains according to dental records existing antemortem, and a postmortem dental profiling in cases where there are no antemortem records. The antemortem records are compared with the dental status of the cadaver giving strong evidence of the identity of the cadaver. In case there is no dental anamnesis, a thorough dental profile is being completed. This in turn helps the specialists to sort the existent antemortem material and select the information that most fits to the profile of the cadaver.

The importance of identification of human remains with methods of high accuracy is better understood in cases where the identification of the cadavers is impossible due to deformities caused by a disease that ailed the person and finally led to his/her death or by a natural or an aviation disaster.

DENTAL IDENTIFICATION

KEYS FOR DENTAL IDENTIFICATION

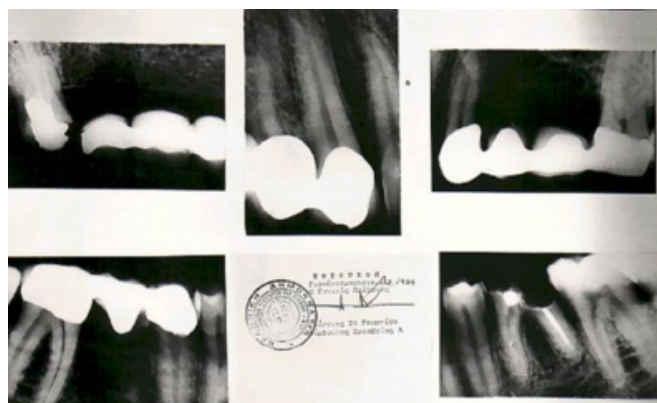
Dental identification is based on the fact that teeth are morphological features like an antemortem fracture or

surgical intervention. That means that they are physical characteristics that endure throughout the decomposition process and are recognizable postmortem ².

Patients that underwent antemortem dental treatments of special difficulty are often thoroughly registered, aiming at a better treatment planning and outcome. That means that dental x-rays (Figure 1) made for the diagnosis and treatment planning or study casts for the analysis of the articulation or a more or less complex prosthetic treatment plan provide information that can be compared with the cadaver's dental status ¹. During this procedure the features that are compared are: presence or absence of teeth, the shape, size and bone peculiarities ³.

Figure 1

Figure 1: Antemortem periapical x-rays



HUMAN TEETH

Human teeth remain unchanged through time unlike other human tissues ⁴.

Features that are registered during the identification process are ₁ :

- Teeth present
- Missing teeth
- Tooth type
- Tooth position
- Crown/Root morphology
- Crown/Root pathology
- Pulp chamber/Root canal morphology
- Pulp chamber/Root canal pathology
- Periapical pathology
- Dental restorations
- Gingival morphology and pathology
- Periodontal ligament morphology
- Alveolar process and lamina dura
- Maxillary sinus
- Anterior nasal spine
- Mandibular canal
- Condylar and coronoid processes
- Temporomandibular joint
- Other pathologies

POSTMORTEM DENTAL PROFILING

When the comparison between the antemortem and postmortem information doesn't reveal common features, or the antemortem information is unavailable or the condition of the remains do not allow the identification, a postmortem dental profiling gives a solution ₁ . Features like age, ancestry, sex, socio-economic status and sometimes occupation, diet, habits and diseases can be acknowledged.

Sex and ancestry. Ancestry can be assessed by studying the facial skeleton and comparing the features with the main characteristics of the three racial groups: Mongoloid, Negroid, and Caucasoid. Gender can be assessed via the results of the study of the skeleton or the teeth. That means

that differences in the shape, the contour and size of the teeth can provide conclusive evidence of the gender of the victim ₅ .

New approaches that involve the tools of molecular biology like DNA analysis can help ascertaining the gender of the cadaver. According to Adachi ₆ and his study on the rate of appearance of the Y chromosome in the dental pulp of extracted teeth related to the time passed after extraction, Y chromatin was assessed at a rate of 42,2% immediately after extraction. The rate fall down to 11,4% two years after extraction. In addition the low rate of the appearance of pseudo-Y chromosome in samples from women, allow the assumption that the DNA analysis can help gender assessment. However details about the lapse of time after death cannot be gained with this method. The analysis of the DNA code is based on the polymerase chain reaction, with which a pre-selected part of the DNA can be amplified, thus providing high concentration of DNA material for analysis in cases where only small samples exist.

Modern forensics can obtain information about the gender of the cadaver, with the analysis of specific genes in the DNA. In particular, genes located on different chromosomes for males and females, can help distinguishing between males and females. The amelogenin gene(AMEL) is located on the X chromosome in females and on the X and Y chromosome in males. The length of the gene on the X chromosome is 106 base pairs and on the Y chromosome 112 base pairs. Thus on a bar-code type display of the DNA the difference in the length of the two genes is visible ₅ .

Sweet et al ₇ in their published case report, used genotype analysis of tooth smear gained after cryogenic grinding of cadaver's teeth in order to compare the results with the antemortem PAP smears from the putative medical record of the individual.

TOOTH AND SKELETAL CHARACTERISTICS IN AGE DETERMINATION

It is stated that special tooth characteristics like the Carabelli cusp are diagnostic markers for the racial categorization of the individual ₁₈ . In particular, the Carabelli cusp, formed by a folding of the inner enamel epithelium, seems to be greater in males than in females ₈₉ . Its formation is mostly related to large crowns ₉ and heigh cusps ₈ and a genetical predisposition may be present. Guo et al ₈ reported that the rate of the appearance of the Carabelli cusp is higher in the Japanese than in the Chinese population ₈ , thus this feature may be more characteristic in some populations.

Feature's variability may cause problems when trying to estimate the age of the cadaver. In particular, in cases where there is no other information and the third molars are the only teeth that can contribute to age estimation, this process becomes difficult because there is a high variance in the development of third molars. Mincer et al¹⁰ advocate that maxillary third molars slightly precede the completion of the development of the mandibular third molars and that root formation of the third molars in males occurs earlier than in females. Thus their developmental status can contribute to age estimation¹⁰.

Skeletal characteristics visible on panoramic radiographs but mainly on lateral skull radiographs provide enough information when ante- and postmortem films are compared. In this manner, Kullman et al¹¹ advocate that radiographs of the frontal sinuses can serve as a medium of identification. The process isn't influenced by the beam angulation or the experience of the observer³¹¹. The characteristics to which the experts focus on are aplasia, symmetry, left or right asymmetry and the number of lobulations³. Other morphological characteristics that are used as a marker for postmortem identification are nutrient canals mainly of the mandibular alveolar process, visible on the postmortem panoramic radiograph¹². Their number and location is compared with those on antemortem radiographs.

Panoramic radiography can also be applied in forensic medicine with the utilization of portable units. This approach is less time-consuming and allows the extraoral examination of the dental status¹³.

The value of tooth and facial skeleton characteristics in human identification is better understood when other morphological features, like antemortem fractures or surgical interventions are taken into account. However, although the aforementioned features seem to be individualizing, some of them, like fractures, are very common in specific regions, so that their value for the identification process is very small².

BLOOD ANTIGENS

Whittaker and Rawle¹⁴ advocate that the antigenicity of powdered dentine and cementum of extracted human teeth remains unaltered without regard to the environmental conditions for a period of 1 to 6 months after extraction¹⁴. This supports the idea to use precipitin reaction, i.e. the reaction of an antigen with a fixed amount of serum containing antibody, in order to assess the origin of tooth fragments found for example at the area of a natural disaster.

Sources of blood antigens are the red blood cells of the dental pulp and the endothelium of the pulp vessels. Many hypotheses have been expressed according to the antigenicity of other components of the pulp that may contribute to identification, like antigens on odontoblasts or dentinal fluid¹⁵. Nakayama and Aoki¹⁵ found out that the ABH antigens in tooth fragments gained after the preparation of extracted teeth, weren't localized into the vascular network, that was according to the results of the SEM absent, but on the odontoblasts and their prolongations at the periphery of the pulp¹⁵. It is of high importance to ensure that the epitopes are being preserved, that means that the decalcification process should be avoided.

The pattern of the repetitive nucleic acid sequences of the DNA of an individual can also serve as a medium of identification. In this manner polymorphisms of the ABO system were evaluated by Minaguchi et al¹⁶, in order to identify a skeletonized female body. The two fragments of a tooth kept for serological analysis, were washed with physiological saline and crashed into powder. Then the powder was decalcified in EDTA and the centrifuged remains were further prepared in order to obtain three samples: DNA sample from tooth powder, from the Tris-EDTA solution and from the EDTA solution. These samples were analysed for ABO system polymorphisms and mitochondrial DNA polymorphisms¹⁶. Mitochondrial DNA has maternal inheritance, lack of recombination, high mutation rate and a high number of copies in each cell. In cases where this type of DNA is analyzed, the first comparison is being made between the specific mutations present in the haplotype of this DNA and that of worldwide database. This process very often helps to identify the ancestry of the victim, as some mutations appear more often in specific regions¹⁶.

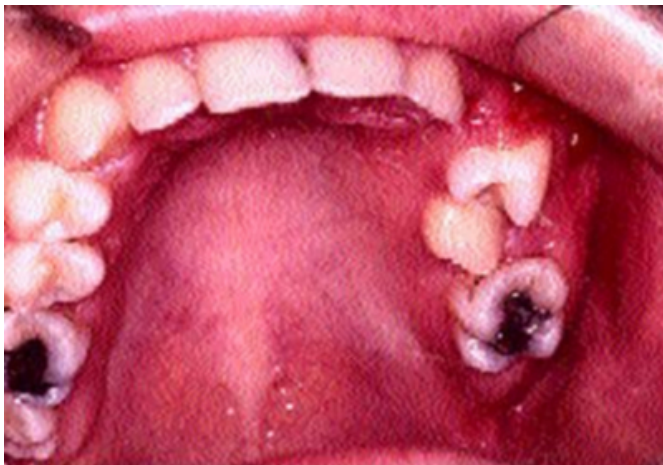TOOTH RESTORATION MATERIALS

In cases where the dental status cannot be evaluated due to a damage of the dentition of the victim, the recognition of the brand name of the used resin for restorative purposes may provide help in the collection of putative antemortem dental records of the victim¹⁷. Amalgam fillings may give important details (Figure 2). Bush et al¹⁷ in this survey mention the role of x-ray spectrum analysis of different resins in coupling each spectrum to a specific brand name. This is feasible due to the rarely altered inorganic composition of resins. The technique applied was SEM/EDS (scanning electron microscope/energy dispersive X-ray spectroscopy). The data was then archived using a software

designed under the auspice of the FBI. It must be stated that a great number of databases exist, that aid in determining the identity of materials according to a specific method. In particular, different types of spectroscopy are utilized in order to identify materials. The interesting point according to Bush et al ¹⁷, is the knowledge of the time frame the product was on the market, thus giving the chance for a chronological window in which the remain can be placed ¹⁷.

Figure 2

Figure 2: The amalgam fillings in the posterior upper jaw are important assessment features on victim identification.



In cases where the restorations were lost because of the circumstances of the death of the victim, these can be reconstructed with the use of amalgam/calcium hydroxide powder ¹⁸. The radiograph that is being obtained after this restoration can be compared with the putative antemortem radiograph of the victim.

Previous dental restorations on incinerated teeth can be visualized with SEM analysis. This procedure can reveal striations that are related to antemortem dental restorations. These findings can be compared with putative antemortem dental records of the victim ¹⁹.

A case report of Suzuki et al ¹⁰, emphasizes on the role of dental material analysis with the utilization of SEM and EPMA (electron probe x-ray microanalysis) in identification. In their publication, the identification of the murder was carried out with the analysis of a small fragment of porcelain recovered beside the cadaver of a woman killed in her apartment. This fragment showed similarities in structure and in the distribution of air-bubbles produced during the baking process with a porcelain restoration of the suspected murderer ²⁰.

DIGITAL TECHNOLOGY

In burn victims where only skeletal remains are available for the identification process, the application of computer technology by means of a morphometric reconstruction of the facial characteristics seems to be very useful. This method suggests that superimposition of a virtual picture, that a special software designs according to the coordinates of special anatomic points of the victim (in case there is severe damage of the facial structures), and a life-time picture can serve as a medium of identification ²¹.

The identification process can also start at the crime or death scene. Funayama et al ²² present a computer network that connects a specialist at the crime or death scene and a server at the laboratory/university where the data is being collected. The specialist takes digital images that may contribute to a quick comparison with putative digital images of the restorations of the victim ²². The software that is being utilized in such approaches can be very common like Adobe Photoshop 5.0 ²³.

PROBLEMS OCCURRING IN THE IDENTIFICATION PROCESS

EDENTULOUSNESS

Patients that do not have physical teeth anymore, represent a problem for the identification process of human remains. Even if there are antemortem radiographs, there are morphological changes in the jaw bone due to the resorption of the alveolar ridges, that render the identification difficult

²⁴.

Panoramic radiographs that exist antemortem as mentioned above can provide useful information only when the time space between the acquisition of the radiographs and the circumstances of the death of the victim is short. Without reference to the rate of absorption an intrinsic problem exists that may influence the ability to obtain postmortem radiographs, that is the tomographic process. Lateral skull radiography is the solution in these cases, because of the reproductability of the method. Goodman and Himmelberger ²⁵ presented a case of an unsolved homicide, where postmortem casts of the victim were obtained for the acquisition of a cephalometric radiograph for the superimposition with a putative antemortem radiograph ²⁵.

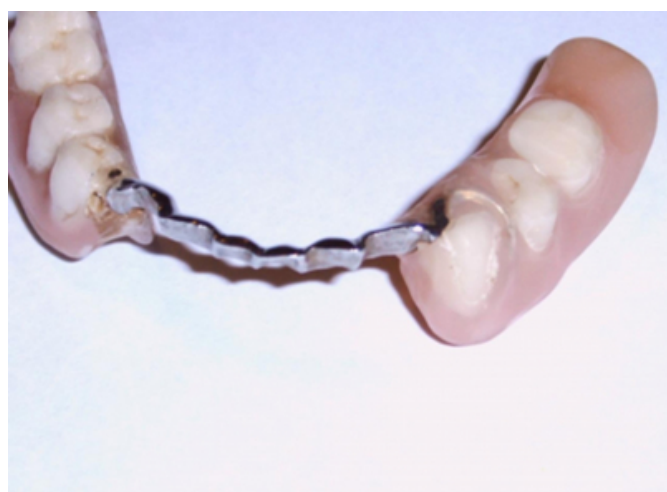Palatal rugae impressions can also serve as a medium for identification in edentulous patients. Limson and Julian ²⁶ presented a computerized method of comparing details of antemortem dental records and postmortem details of the

palatal rugae ²⁶. It must be noted that the condition of the human remains is of high importance for the acquisition of impressions that can serve for human identification. That means that this approach cannot be followed in cases of skeletal remains.

In order to ensure an easier identification process for edentulous victims it is suggested to introduce a denture marking system either with the form of a surface marker (engraving the casts, scribing the denture) or with an inclusion method (metallic labels, microchips) ²⁷. The typical partial denture (Figure 3) may not give information regarding the victim if there is no inclusion method.

Figure 3

Figure 3: A partial denture without metallic labels or microchips.



ANALYSIS OF THE RESTORATIVE MATERIALS

As mentioned above the analysis of the spectrum of a resin recovered from a cadaver can contribute to the identification ¹⁷. Some problems occurring during this process are the following.

It is of high importance to choose the right method for the analysis of the resins especially when they have similar concentrations of the inorganic fillers. In this case the use of X-ray fluorescence (XRF) can contribute to the separation of the resins according to their concentration of Sr

XRF has a major disadvantage that is the inability to detect silicon, when portable x-ray units are used. This is due to the absorption of low energy x-rays

The quantity of the materials archived in the databases should include as many samples as possible in order to enable the pairing

It comes as a conclusion that the analysis of material of unknown origin in cases of disasters with the use of spectroscopy as mentioned above, can help the experts to distinguish between dental and biological materials like teeth or bones ¹⁷.

REDUCED NUMBER OF RESTORATIONS AND MISSING TEETH

Due to the reduction of the number of restorations in the population during the years, it becomes gradually difficult to identify human remains according to their dental status. Additionally, when teeth get lost during the time space between the acquisition of the last panoramic radiograph and the death, postmortem identification becomes difficult (Figure 4,5).


Figure 4

Figure 4: The process of identification is difficult due to excessive loss of tissues.

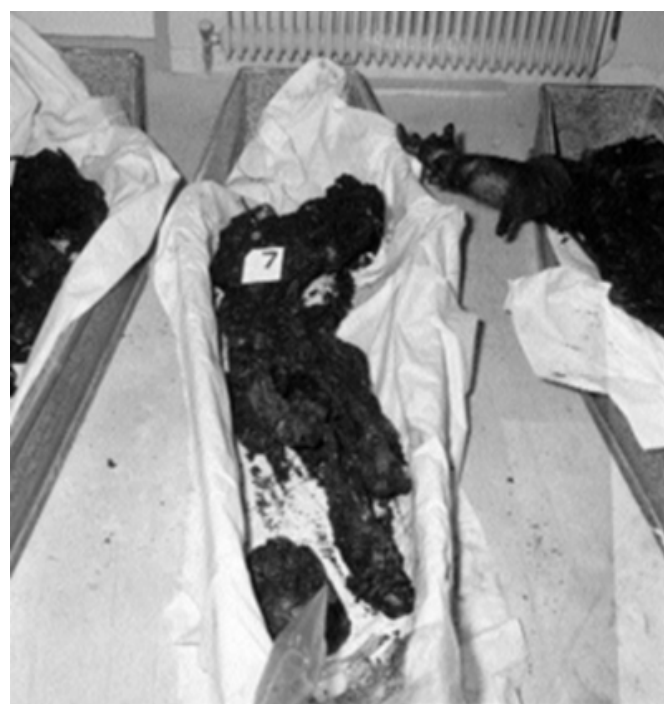

Figure 5

Figure 5a,b: Carbonized victim of an air-accident. The identification process is almost impossible



In this instances, the digitalization of putative ante- and postmortem radiographs, contribute to a computer-aided identification. In particular, the root morphology and the spatial relationship of teeth roots and their supportive structures in ante- and postmortem radiographs are being assessed with the utilization of a computer software and compared ²⁸ .

DISCUSSION

According to the aforementioned, dental identification depends on the condition of the victim and the availability of antemortem dental records. Thus, the circumstances of the accident, the nationality, the country of origin, the antemortem dental treatment, the presence of antemortem dental records and the degree of dental injury ²⁹ can influence the identification process.

The organization of a system for the registration of the odontological status of individuals, that will be part of the health system of every country, can contribute to the minimization of the expenses of the policing agencies and to a more rapid and accurate identification process ³⁰ .

According to the above presented methods of human identification in forensic dentistry, it is noteworthy that new approaches are being made in this field. The tools of molecular biology, like DNA typing of genomic or mitochondrial DNA for the detection of gene polymorphisms and a specific repetitive sequence of the DNA in order to match these results with putative antemortem findings, become very popular.

CONCLUSION

A standardized system for the record of the dental status of individuals is necessary in order to help the process of

human identification after an accident or a mass disaster.

Additionally the training of specific groups, the organization of multidisciplinary groups and the international cooperation are of high importance in forensic medicine.

References

1. PRETTY IA, SWEET D. A look at forensic dentistry-- Part 1: The role of teeth in the determination of human identity. *Br Dent J*. 2001 Apr 14; 190(7):359-66.
2. KOMAR D, LATHROP S. Frequencies of morphological characteristics in two contemporary forensic collections: implications for identification. *J Forensic Sci*. 2006 Sep;51(5):974-8.
3. CAMPOBASSO CP, DELL'ERBA AS, BELVISOM, DI VELLA G. Craniofacial identification by comparison of antemortem and postmortem radiographs: two case reports dealing with burnt bodies. *Am J Forensic Med Pathol*. 2007 Jun; 28(2):182-6.
4. SWEET D, DIZINNO JA. Personal identification through dental evidence--tooth fragments to DNA. *J Calif Dent Assoc*. 1996 May; 24(5):35-42.
5. SLAVKIN HC. Sex, enamel and forensic dentistry: a search for identity. *J Am Dent Assoc*. 1997 Jul; 128(7):1021-5.
6. ADACHI H. Studies on sex determination using human dental pulp. II. Sex determination of teeth left in a room. *Nihon Hoigaku Zasshi*. 1989 Feb; 43(1):27-39.
7. SWEET D, HILDEBRAND D, PHILLIPS D. Identification of a skeleton using DNA from teeth and a PAP smear. *J Forensic Sci*. 1999 May;44(3):630-3.
8. GUO L, SUN DL, REN L, SHEN J, PAN KF, SHEN J ET AL. A comparative morphologic study of Carabelli cusp between Chinese and Japanese students. *Shanghai Kou Qiang Yi Xue*. 1995 Jun;42(2):66-7.
9. KONDO S, TOWNSEND GC. Associations between Carabelli trait and cusp areas in human permanent maxillary first molars. *Am J Phys Anthropol*. 2006 Feb; 129(2):196-203.
10. MINCER HH, HARRIS EF, BERRYMAN HE. The A.B.F.O. study of third molar development and its use as an estimator of chronological age. *J Forensic Sci*. 1993 Mar; 38(2):379-90.
11. KULLMAN L, EKLUND B, GRUNDIN R. Value of the frontal sinus in identification of unknown persons. *J Forensic Odontostomatol*. 1990 Jun;8(1):3-10.
12. FIELDING CG. Nutrient canals of the alveolar process as an anatomic feature for dental identifications. *J Forensic Sci*. 2002 Mar;47(2):381-3.
13. YAMAGUCHI T, YAMADA Y, YAMAMOTO I, OHIRA H, WATANABE A, OHTANI S. Usefulness of postmortem dental panoramic X-ray photographs taken using a portable radiography apparatus for dental identification. *Nihon Hoigaku Zasshi*. 2002 Sep; 56(2-3):254-7.
14. WHITTAKER DK, RAWLE LW. The effect of conditions of putrefaction on species determination in human and animal teeth. *Forensic Sci Int*. 1987 Oct-Nov; 35(2-3):209-12.
15. NAKAYAMA Y, AOKI Y. Distribution of ABH blood group epitopes on inner surface of dental hard tissue: serological, immunohistochemical and ultrastructural study on odontoblasts. *Tohoku J Exp Med*. 1998 Apr; 184(4):267-76.
16. MINAGUCHI K, MARUYAMA S, KASAHARA I, NOHIRA C, HANAOKA Y, TSAI T ET AL. Identification of unknown body using DNA analysis and dental

- characteristics in chest X-ray photograph. Bull Tokyo Dent Coll. 2005 Nov; 46(4):145-53.
17. BUSH MA, MILLER RG, NORRLANDER AL, BUSH PJ. Analytical Survey of Restorative Resins by SEM/EDS and XRF : Databases for Forensic Purposes. J Forensic Sci. 2008; 53(2):419-425.
18. CHIROMA CY. The use of amalgam powder and calcium hydroxide to recreate a radiopaque image of a lost dental restoration. J Forensic Sci. 2002 May; 47(3):609-13.
19. FAIRGRIEVE SI. SEM analysis of incinerated teeth as an aid to positive identification. J Forensic Sci. 1994 Mar; 39(2):557-65.
20. SUZUKI K, HANAOKA Y, MANAGUCHI K, INOUE M, SUZUKI H. Positive identification of dental porcelain in a case of murder. Nihon Hoigaku Zasshi. 1991 Aug; 45(4):330-40.
21. ZVIAGIN VN, IVANOV NV, NARINA NV. Computer-aided personality identification by skull and life-time photography by POSKID 1.1 method. Sud Med Ekspert. 2000 Sep-Oct; 43(5):22-9.
22. FUNAYAMA M, KANETAKE J, OHARA H, NAKAYAMA Y, AOKI Y. Dental Identification Using Digital Images via Computer Network. Am J Forensic Med Pathol. 2000 Jun; 21(2):178-83.
23. BOWERS CM, JOHANSEN RJ. Digital imaging methods as an aid in dental identification of human remains. J Forensic Sci. 2002 Mar;47(2):354-9.
24. RICHMOND R, PRETTY IA. Antemortem records of forensic significance among edentulous individuals. J Forensic Sci. 2007 Mar; 52(2):423-7.
25. GOODMAN NR, HIMMELBERGER LK. Identifying skeletal remains found in a sewer. J Am Dent Assoc. 2002 Nov; 133 (11): 1508-13.
26. LIMSON KS, JULIAN R. Computerized recording of the palatal rugae pattern and an evaluation of its application in forensic identification. J Forensic Odontostomatol. 2004 Jun;22(1):1-4.
27. STAVRIANOS CH, STAVRIANOI I, KAFAS P. Denture identification system based on Swedish guidelines: A Forensic Aspect. The Internet Journal of Forensic Science. 2008; 3(1).
28. WOOD RE, TAI CC, BLENKINSOP B, JOHNSTON D. Digitized slice interposition in forensic dental radiographic identification. An in vitro study. Am J Forensic Med Pathol. 1994 Mar; 15(1):70-8.
29. VALENZUELA A, MARQUES T, EXPOSITO N, MARTIN-DE LAS HERAS S, GARCIA G. Comparative study of efficiency of dental methods for identification of burn victims in two bus accidents in Spain. Am J Forensic Med Pathol. 2002 Dec; 23(4):390-3.
30. BLAU S, HILL A, BRIGGS CA, CORDNER SM. Missing persons-missing data: the need to collect antemortem dental records of missing persons. J Forensic Sci. 2006 Mar; 51(2):386-9.

Author Information

Christos Stavrianos

Department of Endodontology (Forensic Dentistry) School of Dentistry Aristotle University Thessalonica, Greece

Irene Stavrianou

Department of Endodontology (Forensic Dentistry) School of Dentistry Aristotle University Thessalonica, Greece

Eva-Maria Dietrich

Department of Endodontology (Forensic Dentistry) School of Dentistry Aristotle University Thessalonica, Greece

Panagiotis Kafas

Department of Oral Surgery and Radiology School of Dentistry Aristotle University Thessalonica, Greece