

Three-Level Anterior Cervical Discectomy and Fusion with Plate Fixation: Radiographic Results of 127 Patients

D Bullard, J Souza

Citation

D Bullard, J Souza. *Three-Level Anterior Cervical Discectomy and Fusion with Plate Fixation: Radiographic Results of 127 Patients*. The Internet Journal of Neurosurgery. 2008 Volume 6 Number 1.

Abstract

Study Design. A retrospective radiographic review of all patients treated by a single surgeon with a three-level anterior cervical discectomy and fusion with plate fixation. **Objectives.** To compare fusion success rates and pseudoarthrosis results with published data for three-level anterior cervical constructs including; anterior cervical discectomy and fusion with plating (ACDFP) and anterior cervical corpectomy with and without plating (ACCP, ACC). **Methods.** In this study, authors have reviewed a series of 1416 patients done by a single surgeon between May 2001 and February 2008. Of these, 127 patients met standard criteria including a minimum of six months follow up, no previous cervical surgeries, and flexion/extension lateral radiographs. Pseudoarthrosis was defined as abnormal movement between the spinous processes, lucency at the graft vertebral body interface or absence of trabecular bone spanning the complete fused space. Fusion was identified by the absence of abnormal motion of the fused segments on flexion/extension lateral radiographs and the presence of continuous trabecular bone formation at the graft/endplate junction. **Results.** Of the 127 patients, 124 had successful fusions and 3 had pseudoarthrosis. Three hundred seventy-six out of three-hundred eighty-one (98.7%) levels fused while only five (1.3%) levels developed pseudoarthrosis. **Conclusions.** This study presents the largest reported series of patients undergoing a three-level ACDFP by a single surgeon with close follow up, and suggests that three-level ACDFP utilizing a standardized modified Smith-Robinson technique has an acceptably high level of fusion in comparison to other modalities.

Disclosure:

Dr. Bullard and Mr. Souza received grant support from the Synthes Research Foundation. Dr. Bullard is a consultant to DePuy Spine.

INTRODUCTION

Since the anterior approach to the cervical spine was first described by Robinson and Smith¹ in 1955, and then later refined by Cloward² in 1958 and Bailey and Badgley³ in 1960, uniformly high success rates have been reported for single level approaches. The anterior technique described by Smith and Robinson⁴ has essentially become the standard since that time and has largely replaced the posterior approaches.^{5,6,7} Many variations on this anterior surgical approach including; anterior cervical discectomy with fusion (ACDF), anterior cervical discectomy with fusion and plating (ACDFP), anterior cervical corpectomy (ACC), and anterior cervical corpectomy with plating (ACCP) have become widely utilized in the treatment of cervical disease.⁸ One-level and two-level procedures utilizing ACDF, or

ACDFP are generally successful in the range of 95 to 100%.⁹ However, most reports on multilevel procedures have demonstrated relatively high rates of pseudoarthrosis.^{10,11,12,13} Attempts to improve the fusion rate have included; modification in technique, corpectomy and strut grafting or the use of combined anterior/posterior approaches.^{14,15} However, some reports have shown success with ACDF or ACDFP and there are numerous theoretical advantages for this approach compared to the other approaches.¹⁶ A recent paper attempted to address this issue by utilizing a meta-analysis of published literature for the period from 1990 to 2005 with cervical disease. The authors in that study noted that the limitations of the study prevented the application of their findings with three-level disease to general practice because of the relatively small size of the studies reviewed and the heterogeneity of the techniques employed.^{8,17} We report on the radiographic results in the largest series of patients in the literature in which a standardized ACDFP surgical technique was done by a single surgeon. We believe that this data shows that successful three-level ACDFP can be performed when certain techniques are utilized. We have

also reviewed, in detail, the failed cases in this study in the hopes of identifying any common factors which lead to pseudoarthrosis.

MATERIALS AND METHODS

Since May 2000, the senior author has kept a data base of all ACDF, ACDFP, ACC, and ACCP performed at one hospital. This study is a retrospective review of all patients that underwent a three-level ACDFP between May 2001 and February 2008 utilizing a relatively standard surgical technique. A data base of 1416 ACDF and ACDFP done during that time was reviewed and specific data evaluated in comparison to previously published articles on multilevel ACDF, ACDFP, ACC and ACCF.⁸⁹¹⁶¹⁷ It was found that the literature does not prescribe a uniform patient population for studying anterior procedures. Therefore, we chose a conservative criterion that was generally accepted among the studies and authors. The inclusion and exclusion criteria are detailed in Table 1.

Figure 1

Table 1

Inclusion and exclusion criteria for three-level ACDFP study	
Inclusion Criteria	Exclusion Criteria
radiographic evidence of spine fusion	trauma as reason for surgery
single plate (dynamic or static) spanning all three levels	neoplastic disease
	posterior surgery
	previous cervical spine surgery
	rheumatoid arthritis
	corpectomy

A total of 127 patients meeting the criteria were identified and followed for an average of 17.3 months (range 6-73 mo.). The average age at time of surgery was 51.4 years (range 31-75), with 63 (49.6%) being male. The most common diagnoses were; cervical spondylosis, cervical radiculopathy, and/or myelopathy. Surgical candidates included those who had had symptomatic cervical radiculopathy, which had persisted after conservative therapies including combinations of the following; muscle relaxers, non-steroidal agents, steroids, narcotic analgesics, and physical therapy. Those patients with cervical myelopathy were treated under general guidelines for surgical candidates.

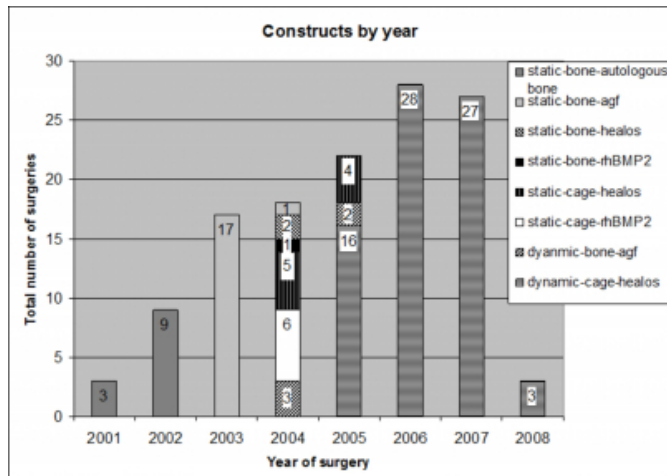
The modified Stand-alone Smith-Robinson¹⁴¹⁵¹⁸ technique for ACDFP was used on all patients. Discectomy was performed utilizing the surgical microscope. Resections were always extended back to the level of the uncovertebral joints which were partially resected if abnormal and the posterior longitudinal ligament which was virtually always excised. The endplates were aggressively decorticated, thus facilitating the removal of posterior osteophytes and

providing a highly vascular fusion bed. The nerve roots were decompressed with meticulous microscopic foraminotomies. The surgical technique for hardware placement was felt to be essentially the same; the longest possible unicortical screws were used, restoration of cervical lordosis was attempted whenever possible, abnormal adjacent levels were incorporated and the placement of hardware was always done utilizing intraoperative imaging with fluoroscopy. Patients were administered 10 mg dexamethasone via intravenous access preoperatively and every 6 hours times three and an antibiotic preoperatively and every eight hours times three over the first 24 hours postoperatively. Most non-diabetics were discharged with a tapering methylprednisolone prescription

There were 23 (18.1%) surgeries that incorporated the cervical levels C3-C6, 100 (78.7%) that incorporated C4-C7, and 4 (3.2%) that incorporated C5-T1. Various cages, plates, and aspirates were used over the span of this study as we felt superior products became available. The grafts used included: (260) Bengal carbon fiber reinforced polymer cage (DePuy Spine Inc., Raynham, MA), (105) LifeNet structural allograft (DePuy Spine, Inc. Raynham, MA), (9) Cornerstone structural allograft (Medtronic Inc., Minneapolis, MN), and (7) Cornerstone PEEK (Medtronic Inc., Minneapolis, MN). These were divided into two groups, Bone (structural allografts) 114 (29.9%) and Cages 267 (70.1%). The three-level plates used included: (79) Swift anterior dynamic plate system (DePuy Spine, Inc. Raynham, MA), (37) Atlantis anterior cervical plate system (Medtronic Inc., Minneapolis, MN), (6) Slim Loc anterior cervical plate system (DePuy Spine, Inc. Raynham, MA), (4) Zephir anterior cervical plate system (Medtronic Inc., Minneapolis, MN), and (1) EBI Vuelock anterior cervical plate system (EBI Spine Systems, Parsippany, NJ). These plates were also divided into two groups, Static 48 (37.8%) and Dynamic 79 (62.2%). Autologous growth factors (agf) using the Symphony system (DePuy Spine, Inc. Raynham, MA) was used on 23 (18.1%), bone marrow aspirate with Healos sponges (DePuy Spine, Inc. Raynham, MA) was used on 85 (66.9%), recombinant human bone morphogenetic protein-2 (rhBMP-2), Infuse (Medtronic Inc., Minneapolis, MN) was used on 7 (5.5%), while 12 (9.5%) had autologous bone harvested from the operative site added. The types of constructs utilized as a combination of the above materials changed throughout the period of this study. The construct type versus the year the surgery was performed is represented in Figure 1.

Figure 2

Figure 1: Construct types by year of surgery



Current protocol includes follow-up visits at 2 weeks, 1, 2, 3, 6, and 12 months with yearly visits. Intraoperative images are saved and lateral neutral, flexion and extension X-rays are obtained on the day after surgery and on each subsequent office visit. CT scans are obtained at six months and one year. Unfortunately, during the early portion of this study all of these criteria were not utilized. For consistency in this study, only patients who had radiographs obtained at least six month post operative follow up were reviewed by both authors and at least one independent radiologist. Where a disagreement existed, two independent neuro-radiologists reviewed the films blindly. Fusion was identified by similar criteria to the published data¹²¹³¹⁹ as the absence of abnormal motion of the fused segments on flexion-extension lateral radiographs; absence of a radiolucent gap between the graft and the endplate; and the presence of continuous trabecular bone formation at the graft and endplate junction.

RESULTS

In total, 127 patients had a cervical three-level ACDFP surgery done by the senior author in the surgical method described and met the inclusion criteria. Table 2 shows the demographic information and outcomes for all 127 patients in this study as a breakdown by their construct types.

Figure 3

Table 2: Materials and demographics of all patients

Construct Type			tot. #	Fused	Male	Smoker	Levels Operated		
Plate	Graft	Aspirate					C3-C6	C4-C7	C5-T1
static	bone	autologous bone	12	11	9	2	1	10	1
static	bone	agf*	18	18	6	3	4	14	0
static	bone	healos	2	2	1	0	1	1	0
static	bone	rhBMP-2†	1	0	0	1	0	1	0
static	cage	healos	9	9	5	3	0	9	0
static	cage	rhBMP-2†	6	6	3	0	2	4	0
dyn.	bone	agf*	5	4	2	0	2	2	1
dyn.	cage	healos	74	74	37	14	13	59	2
Totals			127	124	63	24	23	100	4

* (agf) autologous growth factors using the Symphony system, (DePuy Spine, Inc. Raynham, MA)
† (rhBMP-2) recombinant human bone morphogenetic protein-2, Infuse (Medtronic Inc., Minneapolis, MN)

In all, three (2.4%) of the patients developed pseudoarthrosis, one developed a single-level pseudoarthrosis at the most inferior level and two had pseudoarthrosis at the two most inferior levels. Of all 381 levels operated on, five (1.3%) had pseudoarthrosis, and the remaining 376 (98.7%) levels had stable fusions. Reoperation was performed on two of the three patients with pseudoarthrosis. The only inclusive similarities worthy of mentioning between the three patients that developed pseudoarthrosis were the use of structural allografts (composite bone dowels) and failure at the most inferior levels. The demographics and constructs utilized on the three patients that developed pseudoarthrosis can be seen in Table 3.

Figure 4

Table 3: Materials and demographics of patients with pseudoarthrosis

Age	Levels	Gender	Plate	Graft	Aspirate	Risk Factors	Outcome
35	C3-C6	f	dyn.	bone	agf*	none	treated conservatively
42	C4-C7	f	static	bone	rhBMP-2†	smoking, obesity	reoperation (37mo)
44	C4-C7	m	static	bone	autologous bone	DM, smoking	reoperation (73mo)

* (agf) autologous growth factors using the Symphony system, (DePuy Spine, Inc. Raynham, MA)
† (rhBMP-2) recombinant human bone morphogenetic protein-2, Infuse (Medtronic Inc., Minneapolis, MN)

In order to understand the mechanisms of failed fusions, we must look at each of the three cases of pseudoarthrosis. The cases will be described as pseudoarthrosis patients 1, 2, and 3.

Pseudoarthrosis patient 1 is a 35 year-old female that underwent a C3-C6 ACDFP surgery with a Swift translationally dynamic plate and LifeNet structural allograft in December 2004 for a diagnosis of spondylosis and mechanical neck pain with kyphosis and radicular pain. There were no co-morbidities. The patient symptomatically did well other than the development of shoulder pain at six months after surgery. She was seen in consultation by an orthopaedic surgeon who specialized in shoulder problems and was diagnosed as having a thoraco-scapular dysfunction,

which responded to physical therapy. She had stable X-rays and a normal neurologic examination until June 2008, 42 months after her initial surgery. She acutely developed neck and shoulder pain. Plain X-rays were obtained, which the senior author felt reflected a degree of lucency and pseudoarthrosis at the C5-6 level. A CT scan was performed documenting this. The patient was treated conservatively with physical therapy and within two months had clinically responded. She is currently being followed clinically and radiographically every three months and has a normal neurologic examination.

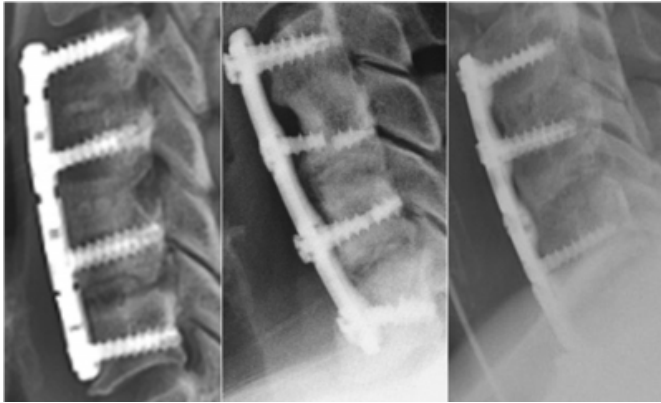
Pseudoarthrosis patient 2 is a 42 year-old female that underwent a C4-C7 ACDFP surgery utilizing an Atlantis static plate, Cornerstone structural allograft, and infused rhBMP-2 in April 2004 for severe cervical spondylosis, refractory mechanical neck pain, and radiculopathy. Co-morbidities included morbid obesity, a smoking history, and clinical diagnoses of fibromyalgia and depression. Initial clinical results were excellent at one month and at two months. At three months she developed a subdeltoid bursitis, which responded to conservative treatment. At six months she had an excellent level of functioning and cervical X-rays showed no evidence of pseudoarthrosis. Clinical follow-up at one year revealed an excellent level of functioning and her X-rays were interpreted by the senior author as well as an independent radiologist as showing a solid fusion at C4-C7 with no abnormal movement. Three years after surgery, she developed acute left upper extremity pain and numbness. Clinical examination, which had been normal at one-year, showed the development of weakness in the left shoulder abductors, biceps, and triceps. X-rays done three years after the initial surgery showed a fracture of a screw at the C5 level, a probable fracture of one of the screws at the C6 and C7 levels, and anterior displacement of the upper portion of the plate with probable lucency through the lowest level at C6-C7. There appeared to be radiographic fusion at the C4-C5 level, but a suggestion of pseudoarthrosis with a degree of lucency at the superior aspect of the graft of C5-C6 and a clear pseudoarthrosis at C6-C7. The patient underwent a second surgery with removal of hardware, takedown of the pseudoarthroses at C5-C6 and C6-C7 and re-instrumentation utilizing a vertebral body replacement (VBR) (DePuy Spine, Inc. Raynham, MA) device spanning the inferior aspect of C6 to the prepared endplate of T1. This was supplemented with Healos sponge saturated with autologous bone marrow aspirate and anterior dynamic plating utilizing a Swift translationally dynamic plate. The patient had continued

smoking one to one and one-half packs per day in the period between the two surgeries. Postoperative imaging at six months with plain X-rays and CT scan showed stable constructs with no evidence of hardware failure. The patient has been able to return to work full time, intermittently takes narcotic analgesics and has fair level of functioning with some pseudoradicular pain in the arm.

Pseudoarthrosis patient 3 is a 44 year-old male who underwent a C4-C7 ACDFP surgery utilizing an Atlantis static plate with LifeNet structural allograft filled with autologous bone harvested from the opposite side for severe spondylosis with radicular and myelopathic clinical features in July 2002. Co-morbidities included non-Insulin-dependent diabetes mellitus and smoking. He had an excellent level of functioning at one month postoperatively. He was able to return to work as a truck driver at two months. The patient was lost to follow up, but apparently underwent a traumatic event two and one half years after the initial surgery. X-rays were performed at another institution and demonstrated fracture of the screws at C7, but the fusion was felt to be radiographically solid. The patient then presented to our practice with a history of left hand numbness of relatively acute onset six years after his initial surgery. X-rays done at that time showed no change in the fracture of the screws, but with the interval development of pseudoarthrosis at the lowest C6-C7 level. The patient had continued to smoke during the interval. He underwent a second operation 73 months after his initial surgery. At the time of operation, the screw fractures were found in both the C4 and C7 vertebral bodies. A pseudoarthrosis was noted at the lowest level. He underwent re-instrumentation utilizing a Mini PEEK cage (Blackstone Medical, Inc., Springfield, MA) filled with Trinity stem cell allograft preparation (Blackstone Medical, Inc., Springfield, MA) and a Swift translationally dynamic single-level plate. Clinically, his neurologic examination has returned to normal at one month. He has had complete resolution of his radicular pain and was able to return to work as a truck driver at one month following surgery.

Figure 5

Figure 2: Radiographic image of pseudoarthrosis patient 1 with lucency at C5-6. Radiographic image of pseudoarthrosis patient 2 with hardware failure and lucency at C5-C6 and C6-C7. Radiographic image of pseudoarthrosis patient 3 with lucency at C6-C7 and hardware failure at C7, partially hidden by the patient's shoulder.



DISCUSSION

There is no single procedure that is appropriate for the treatment of all multilevel degenerative cervical disease. Currently, there is no Class I data to guide surgical decision making in cases of multilevel degenerative cervical disc disease. Many, but not all, published reports on multilevel ACDF have shown unacceptably high pseudoarthrosis rates. Emery et al²⁰ and Wang et al¹² reported the pseudoarthrosis rate for non-plated three-level discectomies as 44% and 37%, respectively. Brodke and Zdeblick⁵ reported a lower but clinically significant pseudoarthrosis rate of 17%. Many explanations for the increased pseudoarthrosis have been given including not only the increased number of graft-bone interfaces, but also altered biomechanics, increasing contact stress at graft-bone interfaces and variations in technique.²⁰²¹

Theoretically, ACDF with cervical plating has the potential to lower the rate of non-union in multilevel ACDF, by providing immediate stability as well as the ability to restore cervical lordosis but reported results have varied widely. Geisler et al²² reported a 100% fusion rate in 35 multilevel (3- and 4-level) ACDFPs. However, Wang et al¹² found that 18% (7 of 40) of the patients had pseudoarthrosis after three-level plated ACDF and that there was not a statistically significant difference in fusion rates between plated and nonplated subgroups. Bolesta et al¹⁰ reported the highest non-union rate of plated ACDF in the literature, 8 of 15 patients (53%).

For three-level disease cases, several reports have suggested

that ACC using fibular strut grafting with or without anterior cervical plates is a better alternative treatment for multilevel cervical spondylosis than ACDF or ACDFP.¹¹²³ However, our data for ACDFP with either bone allografts or cages has a very high fusion rate and we believe is an acceptable option to ACCP. We believe that the biomechanical stability of segmental fixation achieved in multilevel ACDFP is theoretically greater than that achieved in multilevel corpectomy and strut grafting.²⁴ We also believe that cervical lordosis can be best restored with multilevel ACDFP. Finally, fibular autograft harvesting is associated with significant morbidity. Nonetheless, we are not aware of any prospective studies comparing multilevel plated ACDF with corpectomy and strut grafting. We reserve corpectomy for cases with retrovertebral disease, such as extensive ossification of the posterior longitudinal ligament.

Fraser JF and Härtl R⁸ attempted to use meta-analysis to resolve some of the clinical issues. They evaluated 21 papers. Each study included data on at least 25 patients with an average clinical follow up more than 12 months. The results were evaluated according to radiographic evidence of fusion and delineated by the number of levels fused. For one and two level procedures, the data was relatively straight forward but the data for three-level procedures was limited by sample size and surgical variation. For three-level disc disease, fusion rates were 65.0% for ACDF, 82.5% for ACDFP, 89.8% for corpectomy, and 96.2% for corpectomy with plate placement ($p = 0.0001$). They expressed the hope that spine surgeons would use these data primarily as benchmarks for their own outcomes. This was the impetus for the current analysis.

We have a large series of patients who underwent ACDFP done by a single surgeon utilizing essentially the same surgical techniques and a limited variation in types of hardware. We felt that utilizing the criteria employed by other studies as benchmarks would allow us to evaluate how successful our surgical approach was in comparison to those reported in the literature. In addition, we have reviewed the literature to see if certain technical or clinical aspects we utilized and found to be successful had been beneficial in optimizing surgical results for other surgeons but had been obscured by the small sample sizes and multiple techniques utilized.

In this large volume study of 127 patients, a high fusion rate of 376 out of 381 (98.7%) levels fused. Only five (1.3%) levels developed pseudoarthrosis. In fact, these three patients

with pseudoarthrosis initially had successful, asymptomatic fusion; however, they all developed pseudoarthrosis at the most inferior levels at a delayed point in time. Interestingly, all three patients had structural allografts inserted, and the deterioration of these composite bone dowels at the highest stress levels of the construct appears to be the culprit of pseudoarthrosis. Additionally, the two patients that had static plates required reoperation for the symptomatic pseudoarthrosis, while the patient with a dynamic plate was successfully treated with conservative methods.

This data suggests that the possibility of pseudoarthrosis developing in patients with structural allografts later at the most inferior levels after apparent successful fusion is a real phenomenon when hardware failure occurs. It also agrees with the literature that suggests that stress shielding with static plates play a large roll in the relative strength of bone growth regardless of the aspirate used.^{25,26} Our data does not allow statistical evaluation, but we believe that there is a strong suggestion that multilevel constructs using non-deteriorating synthetic cages and dynamic plates is currently the best treatment choice for multilevel cervical degenerative disease.

ACKNOWLEDGEMENTS

The authors wish to thank Ms. Celeste Abjornson Director of the Synthes Research Foundation, Ms. Tracy Veniez, and Ms. Julie Roeser.

References

1. Robinson RA, Smith GW. Anterolateral cervical disc removal and interbody fusion for cervical disc syndrome. *Bull Johns Hopkins Hosp* 1955;96:223–4.
2. Cloward RB: The anterior approach for removal of ruptured cervical disks. *J Neurosurg* 1958;15:602–17.
3. Bailey RW, Badgley CE. Stabilization of the cervical spine by anterior fusion. *J Bone Joint Surg [Am]* 1960;42:565–94.
4. Smith G, Robinson R. The treatment of certain cervical spinal disorders by anterior removal of the intervertebral disc and interbody fusion. *J Bone Joint Surg [Am]* 1958;40:607–23.
5. Brodke DS, Zdeblick TA. Modified Smith–Robinson procedure for anterior cervical discectomy and fusion. *Spine* 1992;17:S427–30.
6. Lowery GL, McDonough RF. The significance of hardware failure in anterior cervical plate fixation: patients with 2– to 7–year follow–up. *Spine* 1998;15:181–7.
7. Phillips FM, Carlson GC, Emery SE, et al. Anterior cervical pseudarthrosis: natural history and treatment. *Spine* 1997;22:1585–9.
8. Fraser JF, Härtl R. Anterior approaches to fusion of the cervical spine: a metaanalysis of fusion rates. *J Neurosurg Spine* 2007;6:298–303.
9. Wang JC, McDonough PW, Endow KK, et al. Increased fusion rates with cervical plating for two–level ACDF. *Spine* 2000;25:41–5.
10. Bolesta MJ, Rechtine GR 2nd, Chrin AM. Three– and four–level anterior cervical discectomy and fusion with plate fixation: a prospective study. *Spine* 2000;25:2040–6.
11. Emery SE, Fisher JR, Bohlman HH. Three–level anterior cervical discectomy and fusion: Radiographic and clinical results. *Spine* 1997;22:2622–4.
12. Wang JC, McDonough PW, Kanim LE, et al. Increased fusion rates with cervical plating for 3–level anterior cervical discectomy and fusion. *Spine* 2001;26:643–6; discussion 646–7.
13. Yue WM, Brodner W, Highland TR. Long–term results after anterior cervical discectomy and fusion with allograft and plating, a 5– to 11–year radiologic and clinical follow–up study. *Spine* 2005;30:2138–44.
14. Emery SE, Bolesta MJ, Banks MA, et al. Robinson anterior cervical fusion: comparison of the standard and modified techniques. *Spine* 1994;19:660–3.
15. Hillard VH, Apfelbaum RI. Surgical management of cervical myelopathy: indications and techniques for multilevel cervical discectomy. *Spine* 2006;6:242S–51S.
16. Papadopoulos EC, Huang RC, Girardi FP, et al. Three–level anterior cervical discectomy and fusion with plate fixation: radiographic and clinical results. *Spine* 2006;31:897–902.
17. DeLong WB, Polissar N, Neradilek B. Letters to the editor. *J Neurosurg Spine* 2008;5:494–5; author reply 495–6.
18. Bohlman HH, Emery SE, Goodfellow DB, et al. Robinson anterior cervical discectomy and arthrodesis for cervical radiculopathy: long–term follow–up of one hundred and twenty–two patients. *J Bone Joint Surg [Am]* 1993;75:1298–307.
19. Cannada LK, Scherping SC, Yoo JU, et al. Pseudoarthrosis of the cervical spine: a comparison of radiographic diagnostic measures. *Spine* 2003;28:46–51.
20. Emery SE, Fisher JRS, Bohlman HH. Higher incidence of pseudarthrosis and poor outcomes for three–level anterior cervical discectomy and fusion. Presented at the annual meeting of the Cervical Spine Research Society, Palm Beach, Florida, December 6, 1996.
21. Hilibrand AS, Yoo JU, Carlson GD, et al. The success of anterior cervical arthrodesis adjacent to a previous fusion. *Spine* 1997;22:1574–9.
22. Geisler FH, Caspar W, Pitzen T, et al. Reoperation in patients after anterior cervical plate stabilization in degenerative disease. *Spine* 1998;23:911–20.
23. Cheng NS, Lau PY, Sun LK, et al. Fusion rat of anterior cervical plating after corpectomy. *J Ortho Surg* 2005;13:223–7.
24. Kawakami M, Tamaki T, Iwasaki H, et al. A comparative study of surgical approaches for cervical compressive myelopathy. *Clin Orthop* 2000;381:129–36.
25. Epstein NE. Anterior dynamic plates in complex cervical reconstructive surgeries. *J Spinal Disord* 2000;13:324–8.
26. Gonugunta V, Krishnaney AA, Benzel EC. Anterior cervical plating. *Neurol India* 2005;53:424–32.

Author Information

Dennis E. Bullard, MD, FACS

Triangle Neurosurgery, PA

John J. Souza, MSME

Triangle Neurosurgery, PA