

# Primary Malignant Melanoma Of The Nasal Cavity And Paranasal Sinuses: A Rare Cause Of Epistaxis In The Elderly

R Dwivedi, N Samanta, S Agarwal

## Citation

R Dwivedi, N Samanta, S Agarwal. *Primary Malignant Melanoma Of The Nasal Cavity And Paranasal Sinuses: A Rare Cause Of Epistaxis In The Elderly*. The Internet Journal of Head and Neck Surgery. 2006 Volume 2 Number 1.

## Abstract

Malignant melanoma of nasal cavity and paranasal sinuses is a rare tumor encountered by ENT surgeons. It is so rare that the majority of ENT surgeons do not see even a single case in their lifetime. This paper is a presentation of a case of 58 yrs old male who came in emergency with massive epistaxis. The patient's history revealed recurrent episodes of nasal bleeding for past 3 months. He also complained of progressively increasing nasal obstruction from left nose for 2 months. Nasal endoscopy was done which revealed a smooth pinkish mass in the left nasal cavity, filling the whole middle meatus, and extending till, just anterior to the choana. The nasal endoscopy on the right side was within normal limits. The histopathological examination gave a conclusive diagnosis of Malignant Melanoma. CT scan of PNS confirmed the finding of a localized mass in left nasal cavity with limited extension.

## INTRODUCTION

Melanomas are tumors arising from melanocytes which are neuroectodermally derived cells located in the basal layers of skin, skin adnexa and some of the mucosal membrane.

Common sites for melanomas are head, neck and the lower extremities as they are exposed to sunlight, which is one of the predisposing factors. Less common sites of involvement are oral and genital mucosa, nail beds, conjunctiva, orbit, esophagus, nasal mucosa or nasopharynx, vagina and leptomeninges.

Primary melanoma of head neck accounts for 25% to 30% of all melanomas (1). However the incidence of melanomas arising from mucosal surface of aero digestive tract varies from 0.4 to 4% (2), the majority arising in the nasal cavity or Para nasal sinuses (3, 4). The nasal cavity is more commonly affected than the Para nasal sinuses, and the maxillary antrum is more frequently involved than the ethmoid sinuses.

The peak age incidence is between fifth and eighth decade (5), seen slightly more commonly in males than females, although age and sex do not affect the prognosis (6,7).

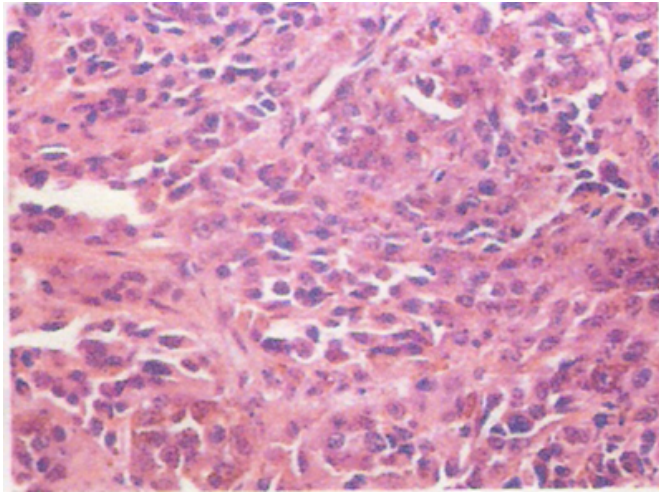
## CASE REPORT

A 58 yrs old male presented in emergency with massive

epistaxis. The patient's history revealed recurrent episodes of off and on nasal bleeding for past 3 months. He also complained of progressively increasing nasal obstruction from left nose since 2 months. A few days after when the patient settled down, diagnostic nasal endoscopy was performed which revealed a pink, smooth mass in the left nasal cavity, filling the whole middle meatus, and extending till choana. The nasal endoscopy on the right side was within normal limits. The biopsy was taken in the same sitting and sent for histopathological examination, which gave a conclusive diagnosis of Malignant Melanoma (Fig.1). CT scan of PNS confirmed the finding of a localized mass in right nasal cavity involving the left anterior and posterior ethmoid sinuses (Fig.2) also blocking the infundibulum of maxillary antrum. There was a mass effect on the left orbit pushing the medial wall. However there was no evidence of direct orbital involvement. Superiorly the mass was extending up to the cribriform plate with possibility of its erosion at some places, however the patient did not have any altered smell or any signs of meningeal irritation. There was no involvement of sphenoid sinuses, regional lymphnodes or any distant organ. The disease was not found eroding nasal septum and was limited to left side only. The Patient did not agree for Surgery and was referred to department of Radiation Oncology for further management.

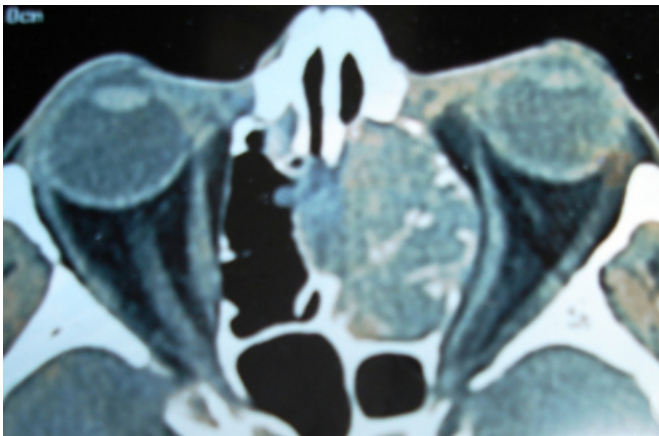
**Figure 1**

Figure 1: Showing histopathology of Tumor



**Figure 2**

Figure 2: CT scan axial cut, showing the extent of the tumor



## DISCUSSION

Malignant melanoma is comparatively rare in comparison to squamous cell carcinomas among the cancers that arise in nasal cavity and Para nasal sinuses. The natural course of malignant melanomas is marked by early local recurrences, extensions and frequent metastasis to lymph nodes and viscera, making it one of the most dangerous forms of nasal and paranasal sinus tumors. The incidence of regional lymph node metastasis on admission is approximately 5% to 15% (8). The submandibular lymphnodes are most commonly involved.

High index of suspicion is required to make an early diagnosis. Generally ENT surgeons do not have any problem in diagnosing and staging this disease but owing to its rarity there remains some disparity in deciding the proper plan of

treatment.

In general, the management of mucosal melanomas has not been uniform. The only definitive prognostic factor is the presence of distant metastasis at the time of diagnosis.

As a rule, the patients with localized disease should undergo surgery followed by postoperative radiotherapy for better local control of the disease unless the patient is not willing to undergo surgery, as in the present case.

Historically, mucosal melanoma was characterized as radioresistant disease, but recent observations have suggested that radiotherapy has a significant role in their treatment. Literature shows overall response rate of 50% to 75%, if radiotherapy alone is used for treating localized mucosal melanomas. These are more radiosensitive than their cutaneous counterparts.

Surgery along with adjuvant radiotherapy should be used for patients with either regional metastases or large bulky primary disease.

Patients with unresectable local disease or those who do not agree for surgery, should be considered for radiotherapy alone as a definitive management, where as Chemotherapy should be reserved for patients with systemic disease.

## CONCLUSION

Most of malignant melanomas arise in the nasal cavity. Those that arise in the paranasal sinuses tend to be relatively advanced at diagnosis. It typically presents with nasal obstructive symptoms and epistaxis. Treatment of malignant melanoma is the same, stage for stage (i.e. surgery and post op radiotherapy).

Mucosal melanomas tend to be more aggressive and have a poorer prognosis than cutaneous counterparts, having 10% to 15% 5-year survival rates (9, 10). The poor prognosis may be attributed to local recurrence, distant metastasis and/or second primary. Hence the importance of life time surveillance, patient's education and monthly self examination of skin and regional lymph nodes for A (Asymmetry), B (Border), C (Color), D (Diameter) of melanoma surveillance should not be overlooked.

Several new biologic and immunomodulatory treatments are currently being investigated for use in patients with mucosal melanoma: the results of such treatment approaches are eagerly awaited.

## **CORRESPONDENCE TO**

Dr. Raghav C Dwivedi Dept. of Otolaryngology & Head-Neck Surgery King George's Medical University, Lucknow, India- 226007 +91-0522-2361604, +91-0522-23655539, +91-9415181078 E-mail: raghav\_dwivedi@rediffmail.com

## **References**

1. Goldsmith HS. Melanoma: An overview. *CA Cancer J Clin* 179; 29:194-215.
2. Berthelsen A, Andersen AP, Jensen S, Hansen HS. Melanomas of the mucosa in the oral cavity and the upper respiratory passages. *Cancer* 1984; 54:907-912.
3. McKinnon JG, Kokal WA, Neifeld JP, et al. Natural history and treatment of mucosal melanoma. *J Surg Oncol* 1989; 41:222-225.
4. Stern SJ, Guillaumondegui OM. Mucosal melanoma of the head and neck. *Head Neck Surg* 1991; 13:22-27.
5. Batsakis JG, Suarez P, Naggar AK. Pathology consultation, mucosal melanomas of the head and neck. *Ann Otol. Rhinol Laryngol* 1998; 107:626-30.
6. Batsakis JG, Regezi JA, Soloman AR, Rice DH. The pathology of head and neck tumors; mucosal melanomas, Part B. In: *Head and Neck Surgery* 1982; 4:404-418.
7. Snow GB, van der Waal I. Mucosal melanomas of the head and neck. *Otolaryngol Clin North Am* 1988; 19:549-564.
8. Batsakis JG. Pathology of tumors of the nasal cavity and paranasal sinuses and neck cancer. Philadelphia: WB Saunders Company; 1999; 522-539.
9. Conley JJ (1989) Melanomas of the mucous membrane of the head and neck. *Laryngoscope* 1999; 1248-1254.
10. Hoyt DJ, Jordan T, Fisher SR. Mucosal melanoma of the head and neck. *Arch Otolaryngol Head Neck Surg* 1989; 115:1096-1109.

**Author Information**

**Raghav Dwivedi**

Senior Resident, Department of Otolaryngology and Head Neck Surgery, King George's Medical University

**Nirmalya Samanta**

Resident, Department of Otolaryngology and Head Neck Surgery, King George's Medical University

**Satya Agarwal**

Professor, Department of Otolaryngology and Head Neck Surgery, King George's Medical University