

Trigger Finger: Comparative Study between Corticosteroid Injection and Percutaneous Release

V Singh, S Chong, S Marriapan

Citation

V Singh, S Chong, S Marriapan. *Trigger Finger: Comparative Study between Corticosteroid Injection and Percutaneous Release*. The Internet Journal of Orthopedic Surgery. 2005 Volume 3 Number 2.

Abstract

Background: Trigger finger (stenosing tenosynovitis) is a common problem encountered in orthopaedic practice. There are various methods of treatment ranging from conservative management to surgical release.

Aim: To determine effectiveness of corticosteroid injection and percutaneous release; in terms of symptomatic relieve, patient satisfaction and complications.

Material & Methods: Prospective study. All patients who presented with trigger finger Grade 2 and 3 were randomized into 2 groups. One group received corticosteroid injection and in the other group, percutaneous release was done. These patients were then assessed weekly over a period of one month and their progress noted.

Results: We studied a total of 26 patients. Majority (65.4%) were females. The commonest age group is 50-60 years olds (45.6%). Thirty eight and a half percent were manual workers, 30.8% semi-professionals followed by 26.9% housewives. There was almost equal involvement of dominant (53.8%) and non-dominant hand (46.2%). The most common presenting symptom was pain with triggering (42.3%). The middle and ring were most commonly affected (42.2% each). The little finger was not involved at all. There was significant improvement in pain in the first two weeks in both groups but there was better improvement of pain in the corticosteroid group especially on the 1st and the 4th week. As for the triggering, there was significant improvement noted in 1st week but there was no difference in degree of improvement between both the groups. There was no significant difference was noted in the progress of swelling during the course of the treatment in either group. As for patient satisfaction, the percutaneous release group reached maximum satisfaction by 2 weeks as oppose to the corticosteroid group, which achieve maximum satisfaction 1 week later. The corticosteroid group had a complication rate of 10% whereas the percutaneous release group complication rate was 20%. The recurrence rate was 15%. There were 2 cases in each group. Occurring 2 to 9 months after the primary procedure.

Conclusion: Trigger finger is a common condition amongst blue-collar workers. The commonly affected fingers are the centrally located on the palm. The group of patients treated with corticosteroid had better relieve of pain but took longer to achieve maximum satisfaction as compared to the group that underwent percutaneous release. Both method of treatment eventually gave similar results after 3 weeks but the percutaneous release group had a higher complication rate. Recurrence was equal in both groups.

INTRODUCTION

Trigger finger is a common problem encountered in orthopaedic clinics. It is characterised by inability to flex or extend the digit smoothly. It is also known as stenosing tenosynovitis. All the digits can be involved but the ring, thumb, long, index and small fingers are the most commonly involved, in that order of frequency ^{1 2}.

Primary trigger finger is usually idiopathic and occurs more frequently in middle-aged women, but can be seen even in

infancy. Secondary trigger finger of the digits can occur in patients with rheumatoid arthritis, diabetes mellitus, gout and other disease entities that cause connective tissue disorder.

Pathogenesis of trigger finger is due to pathological disproportion between the volume of the retinacular sheath and its contents. This disproportion inhibits gliding of the tendon through A1 pulley. Two types of pathological involvement are seen, nodular and diffuse types ³. These

finding is based on palpation of swelling of the tendon sheath. Nodular type is commonly seen in idiopathic trigger fingers and diffuse type is seen in conjunction with connective tissue diseases. Trigger fingers are graded according to severity. Commonly used classification is by Quinell₄ (figure 1).

Figure 1

Figure 1: Grading of trigger finger.

| | |
|---------|--|
| Grade 0 | Mild crepitus in the non-triggering finger |
| Grade 1 | No triggering, but uneven finger movements |
| Grade 2 | Triggering is actively correctable |
| Grade 3 | Usually correctable by the other hand |
| Grade 4 | The digit is locked |

Various method of treatment has been advocated ranging from conservative treatment (consisting of massage, ice, NSAIDS and splinting), corticosteroid injection, percutaneous release and open release. Surgical release is recommended if non-operative treatment fails. It is postulated that 85% of trigger fingers respond well to conservative treatment. The success of the treatment is dependant on duration of complaint, severity of triggering and type of triggering₅.

MATERIALS AND METHOD

This is prospective randomized study, conducted in Orthopaedic Department at Penang General Hospital from 1st January 2005 till 30th June 2005. We compared the effectiveness of corticosteroid injection and percutaneous release, in terms of symptomatic relieve, patient satisfaction and complications.

Patients who presented with Grade 2 and Grade 3 trigger finger were randomized into 2 groups. Randomization was done by adding together the birth year of the patient and dividing it by 2. Those with even numbers were allocated to the corticosteroid group and odd numbers to the percutaneous group. All the patients were explained the nature of the study and a written consent was taken. Thumbs were excluded from the study because in our center, they are usually treated by open release. This is due to the proximity of radial digital nerve to the A1 pulley making it susceptible to damage in a percutaneous release. These patients were followed up weekly for a month and 3 monthly for a year.

OPERATIVE PROCEDURE

PERCUTANEOUS RELEASE

A 3 cm³ syringe is used to infiltrate 1% lignocaine around the A1 pulley area. Patient is asked to actively wiggle the affected digit to ascertain the position of the thickened A1 pulley. A 20-gauge needle is then inserted with the sharp bevel parallel to the tendon. The needle is inserted one third the distance from the distal palmar crease to the base of the middle, ring, or small finger. In the case of the index finger, the needle is inserted one third the distance from the distal thenar crease and the base of the finger. These positions correlate with the middle of the A1 pulley. The needle is then stroked longitudinally proximally and distally to transect the pulley₆.

CORTICOSTEROID INJECTION

The distal palm in the area of the A1 pulley is cleansed with povidone iodine solution. A 30-gauge 0.5-inch needle is used to anesthetize the area around the A1 pulley as well as the tendon sheath with 1 mL of 1% lignocaine without epinephrine. Then 1 mL of the triamcinolone is mixed with 1 mL of 1% lignocaine injected into the tendon sheath and around the nodule. The position of the needle is ascertained by asking the patient to wiggle the finger. If the needle is in the tendon proper, there is a paradoxical movement of the needle. A small sterile dressing was applied for a day and patient was allowed to return to normal routine activity. Analgesia is given for 3 days. These patients are advised to return immediately if there were any signs to indicate infection.

These patients were assessed weekly in the clinic for a month, to observe the improvement in the grade of triggering, swelling, pain and patients' satisfaction. Pain was assessed with the visual analog scale.

STATISTICAL METHODS

The statistical analysis was performed with Stats View. Descriptive statistical analysis was used to analyse demographic data. Paired t-test was used to measure the weekly progress in the corticosteroid and percutaneous group respectively, in terms of symptom relieve, patient's satisfaction and complications. Unpaired t-test was used to comparing the effectiveness of treatment between both the groups. A p-value of < 0.01 was considered to be significant.

RESULTS

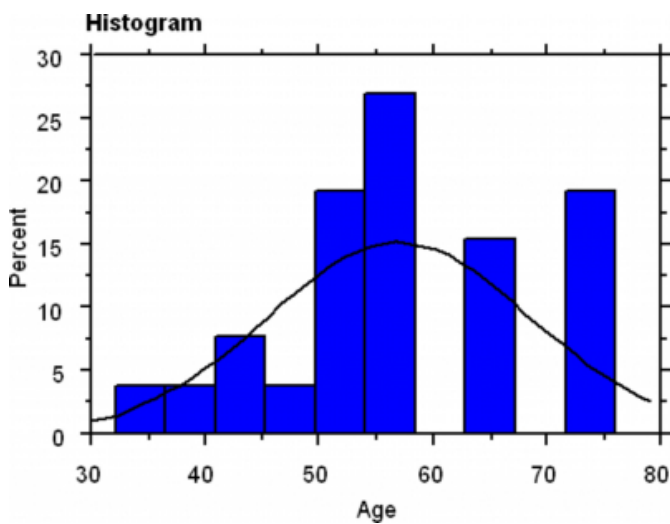
Twenty-six patients presented to us with trigger fingers. They were randomized to 2 groups, corticosteroid group and

percutaneous release group. A total of 12 patients received corticosteroid injections and 14 patients underwent percutaneous release. There were 4 index fingers, 11 middle fingers and 11 ring fingers. The patients presented with symptoms of triggering, pain, palpable nodule, swelling or a combination of these. All of them had the nodular type of trigger finger.

Majority of the patients (45.6%) were 50 to 60 years old with a mean age of 57 years old (figure 2). Occupation wise, 38.5% were manual workers, 30.8% were semi-professionals and 26.9% were housewives. Professionals were rarely involved.

Figure 2

Figure 2: Age distribution of patients.



More females (65.4%) were affected with trigger finger compared to males (34.6%). Dominance of the hand had no bearing on the incidence of triggering (Dominant 53.8% and non-dominant 46.2%). In 61.5% of patients, this was the first episode of triggering with 26.9 % and 11.5% presenting with second and third recurrence. Thumb was excluded from this study for reasons noted earlier. Amongst the four fingers, the most commonly involved finger was the middle and ring finger (42.2% each). There was no involvement of the little finger. The most common presenting complaint in our patients was pain with triggering in 42.3%, followed by triggering alone in 23.1% and pain alone in 15.4% of patients.

There was significant improvement in pain in the first two weeks in both the groups. Better improvement in pain was observed in the corticosteroid group of patients as compared to the percutaneous release group, in the first and fourth week.

Triggering was assessed according to the grading described above. There was significant improvement noted in the 1st week in both the groups. However, there was no statistically significant difference between both the groups. In terms of swelling of the digits, no difference was noted during the course of the treatment in the corticosteroid group. Slight improvement was noted in the percutaneous group after 3rd week. As for patients' satisfaction, the percutaneous release group reached maximum satisfaction by 2nd week as appose to the corticosteroid group, which achieve maximum satisfaction one week later.

The corticosteroid group of patients had a complication rate of 10% (1 patient claimed numbness over distal phalanx after corticosteroid injection) and the percutaneous group had 20% complication rate (2 patients developed stiffness of digit which responded to aggressive physiotherapy and 1 patient developed bowstringing of tendon).

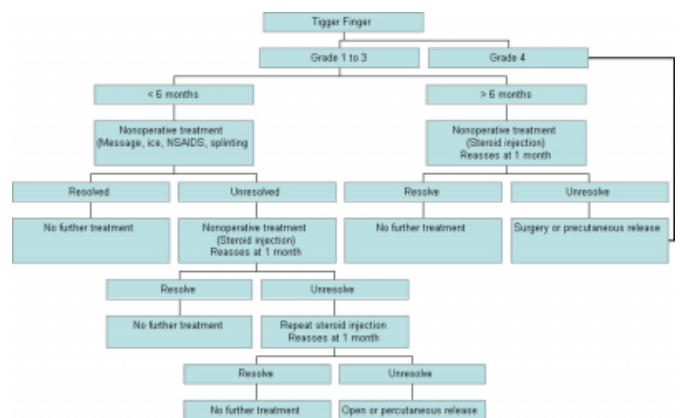
There were a total of 4 patients that had recurrence (recurrence rate 15%). Two cases each in both groups. This, occur at 2 to 9 months after the primary procedure. They were treated successfully with open release.

DISCUSSION

Trigger finger is a common problem encountered in the orthopaedic practice. Eighty five percent responds favourably to conservative treatment such as corticosteroids and nonsteroidal anti-inflammatory. Surgical release (percutaneous or open) is resorted if conservative treatment failed. The decision of mode of treatment depends on grade of the trigger finger and duration of symptoms. Miguel J. Saldana⁸ outlined treatment of trigger fingers according to grades of severity as shown in figure 3.

Figure 3

Figure 3: Flow chart for treatment of various grades of trigger finger.



It is generally agreed that grade 0 and grade 1 trigger fingers requires no more than gentle physiotherapy and NSAIDs, failure of which is treatable with corticosteroid injection. Meanwhile grade 4 triggering is usually resistant to conservative treatment and requires surgical release. However, the management of grade 2 and grade 3 trigger finger is a still subject of debate.

First introduced by Howard et al⁹, in 1953, the use of steroid injections has been amply reported with varying degrees of success. Many authors have demonstrated good results, as high as 92%,⁷⁻⁹ in all grades of trigger fingers treated with corticosteroid injections with as many as three injections. This offers us an interesting proposition to treat this mild condition non-surgically and avoid complications of surgical release, which includes digital nerve injury, A2 pulley injury with subsequent bowstringing of the tendons, stiffness and sympathetic dystrophy¹⁰⁻¹².

Lothoir¹⁰ first reported percutaneous release of a trigger digit, in 1958. He reported good results in 52 digits with no complications with the use of a fine tenotome. This encouraging result paved way for many new techniques and modified instruments to reduce the possible complications associated with percutaneous release.

For example, K.I. Ha¹¹ described a percutaneous technique using a specially designed knife where 185 patients with grade 3 and 4 triggering were included in this study. Majority (173 patients) achieved satisfactory results. Eleven patients had persistent triggering and one had persistent pain at the release site. No significant complications were noted. Similar result, were also obtained by Shaw-Ruey Lyu¹². He used a specially designed pulley hook and curved-blade knife.

Regardless the technique used for the percutaneous release, there are some precautions that need to be taken when carrying out such procedures in order to avoid damaging the digital nerves. These are best described by Charles Sorbie¹³, which include; stay in the midline of the digit, extend the finger at the metacarpophalangeal joint, keep the needle perpendicular to the sagittal plane and be accurate with the position of the needle tip. He also suggested than percutaneous release could induce painful tenosynovitis with resultant painful finger flexion for several months if corticosteroid is not used with initial local anaesthesia.

Our study supports the use of corticosteroid injection in treating grade 2 and grade 3 trigger fingers. Both the use of corticosteroid and percutaneous release yield almost similar results, but the corticosteroid group is associated with fewer complications. We did not find any difference in the recurrence rate in both methods of treatment.

CORRESPONDENCE TO

Mr Vivek Ajit Singh 107-2-5 Desa Acacia. Medan York.
10450 Penang. E mail: drvivek69@gmail.com Tel:
0060124940600

References

1. Freiberg A, Mulholland RS, Levine R: Nonoperative treatment of trigger fingers and thumbs. *J Hand Surg [Am]* 1989; 14:553-558.
2. Manske PR, Lesker PA: Flexor tendon nutrition. *Hand Clinic* 1985; 1:13-24
3. Quinnell RC: Conservative management of trigger finger. *Practitioner* 1980; 224:187-190.
4. Saldana MJ: Percutaneous trigger finger release. *Atlas Hand Clin* 1999; 4:23-37
5. Miguel J, Saldana, MD: Trigger Digits: Diagnosis and Treatment. *J Am Acad Orthop Surg* 2001; 9:246-252
6. Howard LD Jr, Pratt DR, Bunnell S: The use of compound F (hydrocortone) in operative and non-operative conditions of the hand. *J Bone Joint Surg Am* 1953; 35:994-1002.
7. Patel MR, Bassini L: Trigger fingers and thumb: When to splint, inject, or operate. *J Hand Surg [Am]* 1992; 17:110-113
8. Kolind-Sørensen V: Treatment of trigger fingers. *Acta Orthop Scand* 1970; 41:428-432
9. Rhoades CE, Gelberman RH, Manjarris JF: Stenosing tenosynovitis of the fingers and thumb: Results of a prospective trial of steroid injection and splinting. *Clin Orthop* 1984; 190:236-238.
10. Carozzella J, Stern PJ, Von Kuster LC: Transection of radial digital nerve of the thumb during trigger release. *J Hand Surg [Am]* 1989; 14:198-200.
11. Heithoff SJ, Millender LH, Helman J: Bowstringing as a complication of trigger finger release. *J Hand Surg [Am]* 1988; 13:567-570.
12. Thorpe AP: Results of surgery for trigger finger. *J Hand Surg [Br]* 1988; 13: 199-201.
13. Lorthloir J. Surgical treatment of trigger-finger by a subcutaneous method. *J Bone Joint Surg [Am]* 1958; 40-A : 793-5.
14. K.I Ha, M. J Park, C.W Ho. Percutaneous release of trigger digit, A technique and results using a specially designed knife. *J Bone Joint Surg [UK]* 2001; 83; 75-3.
15. Shaw-Ruey Lyu. Closed division of the flexor tendon sheath for trigger finger. *J Bone Joint Surg [Am]* 1992; 74-B: 418-20.
16. Charles Sorbie. Percutaneous release of trigger finger. *Orthopedics Thoroface* Apr 2001:328-1.

Author Information

Vivek Ajit Singh

Orthopaedic Department, Penang General Hospital

Se To Boon Chong

Consultant Orthopaedic Surgeon, Orthopaedic Department, Penang General Hospital

Sureisen Marriapan

Orthopaedic Department, Penang General Hospital