

# Hepaticocystic Duct: A Case Report

R Kaushik, A Attri

## Citation

R Kaushik, A Attri. *Hepaticocystic Duct: A Case Report*. The Internet Journal of Surgery. 2004 Volume 6 Number 1.

## Abstract

The case of a 26-year-old female patient who was found during cholecystectomy to have drainage of both, the right and left hepatic ducts directly into the gallbladder neck with absence of the common bile duct is reported. Further drainage of the bile away from the gallbladder and into the duodenum was provided by the cystic duct. This rare biliary tract anomaly is reported and the relevant surgical options discussed.

## INTRODUCTION

The biliary tract is notorious for its variable anatomy. The classical textbook anatomy of the biliary tract is seen in less than 50 % of cases, and the extrahepatic biliary system is said to have more anomalies in one cubic centimeter of the space around the region of the cystic duct than any other part of the body. <sup>1</sup>. This variable anatomy adds to the operative difficulties, especially in the presence of significant changes occurring as a result of the disease process itself.

Although the reported incidence of congenital anomalies of the extrahepatic biliary tract lies between 0.58 % to 47.2 %, <sup>2</sup> the exact incidence of all the anomalies of the biliary system is not known for sure - vascular anomalies are said to be more frequent than those of the ductal system. <sup>1, 3</sup>.

Anomalies of the extrahepatic biliary tree may arise from the gallbladder, cystic duct, hepatic ducts or the common bile duct as a result of aberrations of the normal embryological development, and it is necessary to be familiar with them in order to avoid the disastrous consequences that may follow misrecognition at the time of surgery.

One such rare anomaly is the hepaticocystic duct, wherein the right and left hepatic ducts drain directly into the gallbladder, with agenesis of the common hepatic and common bile ductal systems. It has also been referred to differently as cholecystohepatic duct, congenital absence of the common bile duct, transverse lie of the gallbladder, or, gallbladder interposition by various authors. Such a case that was identified during cholecystectomy is briefly reported below.

## CASE REPORT

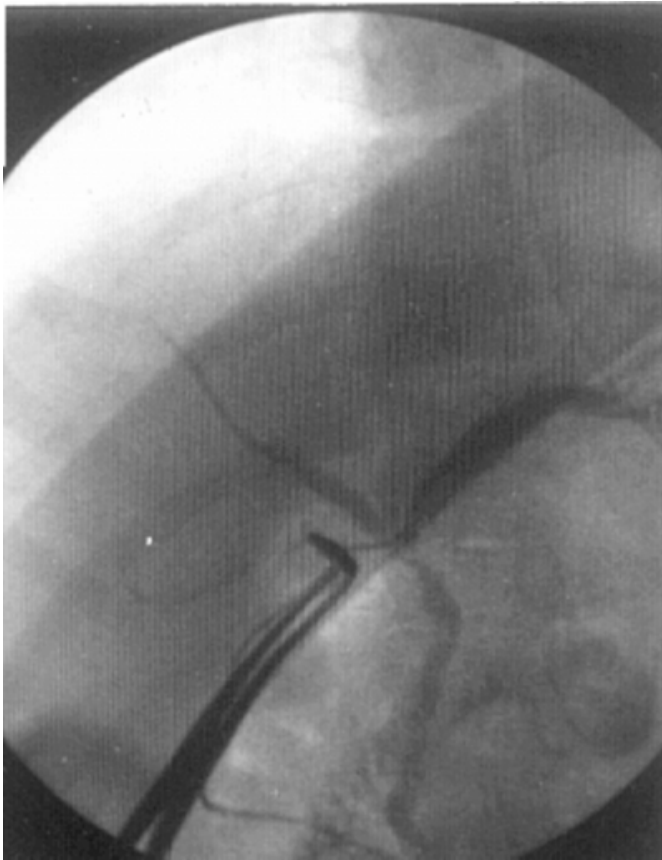A 26-year-old female patient having symptomatic

cholelithiasis for a period of 2 years was admitted to our hospital for elective laparoscopic cholecystectomy. There was no history of jaundice or cholangitis, and her abdominal sonogram had revealed multiple gallbladder calculi, with a normal common bile duct diameter. The routine hematological and biochemical investigations (including liver functions) were within normal limits.

Laparoscopic cholecystectomy proceeded via the standard four port technique after induction of general anaesthesia, the first trocar being inserted by an open method of placement. There were minimal adhesions in the Calot's triangle, and on separation, it was visualized that the common hepatic duct was absent, with two separate duct like structures entering the gallbladder at its neck. Conversion to open cholecystectomy was performed, and it was confirmed that the common hepatic duct was absent. The two ductal structures seen to enter the gallbladder superiorly at the neck were presumed to be the right and left hepatic ducts, with the cystic duct continuing from the gallbladder downwards towards the duodenum. An intra-operative cholangiogram was performed using the gallbladder (Figure 1).

**Figure 1**

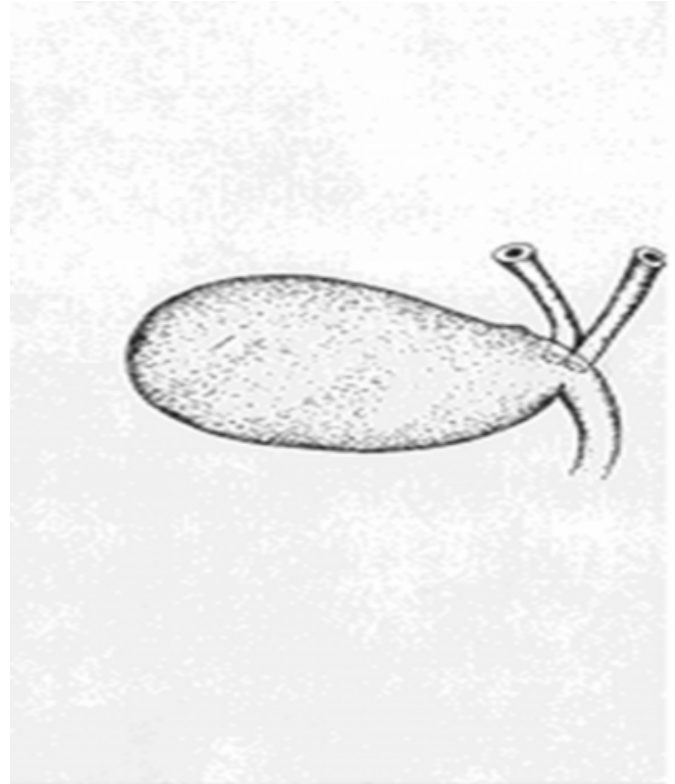
Figure 1: Intra-operative cholangiogram showing absence of the common hepatic duct. Note that both the right and left hepatic ducts are draining independently.



It revealed an absent common hepatic duct, with the right and left ducts draining directly into the gallbladder (Figure 2).

**Figure 2**

Figure 2: Diagrammatic representation of the operative findings. Both, the right and left hepatic ducts were found to be draining independently at the neck of the gallbladder.



The cystic duct coursed downwards from the gallbladder and drained the dye into the duodenum. After confirming these findings, a partial cholecystectomy was performed, leaving behind a cuff of the gallbladder near the point of drainage of the right and left hepatic ducts. Abdominal closure was performed after instituting drainage of the sub-hepatic space.

The patient had an uneventful post-operative period, and was discharged on the fourth day after removal of the drain. She is presently well on a follow up of slightly more than 2 years, with absence of jaundice, normal liver functions and normal ductal system on ultrasound.

The histopathology of the resected gallbladder revealed chronic cholecystitis with cholelithiasis.

### DISCUSSION

Normally, the liver, gallbladder and the extrahepatic biliary tree arise from the hepatic diverticulum of the foregut in the beginning of the fourth week of development. This diverticulum rapidly proliferates into the septum transversum and divides into two parts – the distal pars hepatica / hepatic diverticulum (that forms the liver and hepatic ducts), and the proximal pars cystica / cystic

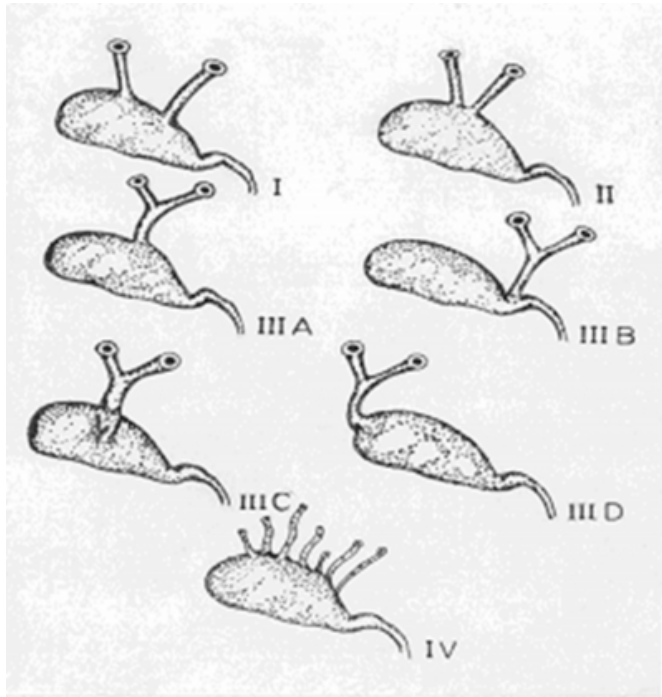
diverticulum (that develops into the gallbladder and the cystic duct). At the time of appearance of the cystic diverticulum, there occurs proliferation of the cells at the junction of the cystic and hepatic ducts to form the common bile duct, which is initially a cylindrical mass that undergoes vacuolation to canalize and form a single, continuous, epithelium lined lumen.<sup>4, 5</sup>

Failure of this normal pattern of development results into various anomalies, the rarest amongst which is the hepaticocystic duct, wherein the right and left hepatic ducts drain directly into the gallbladder, with agenesis of the common hepatic and common bile ductal systems. The final pathway of drainage of bile into the duodenum remains the cystic duct, which functions as the common bile duct. Although the exact etiology of this rare anomaly is unknown, it is hypothesized to occur as a result of failure of recanalization, with persistence of the fetal communications between the gallbladder and liver,<sup>6</sup> or from delayed division of the hepatic antrum into the cystic and hepatic diverticuli.<sup>1</sup>

There are various patterns of hepaticocystic ducts that have been recognized (see Figure 3).

### Figure 3

Figure 3: Previously documented types of "cholecystohepatic ducts"



(Losanoff JE, Jones JW, Richman BW, Rangnekar NJ. Hepaticocystic duct: A Rare Anomaly of the Extrahepatic

Biliary System. Clin Anat 2002; 15: 314 – 5. Reprinted by permission of Wiley-Liss, Inc., a subsidiary of John Wiley & Sons, Inc.)

Type I refers to the absence of the common hepatic duct and the right and left ducts drain separately into the gallbladder; Type II is said to be present when the right and left hepatic ducts unite upon entering the gallbladder; Type III refers to a common hepatic duct that enters the gallbladder, and in Type IV multiple small bile ducts connect the intrahepatic biliary system with the gallbladder. Type III is further subdivided into the common hepatic duct entering the superior wall of the gallbladder (III A), neck (III B), posterior gallbladder wall (III C), and, the fundus (III D).<sup>7</sup> In our patient, the right and left ducts entered into the gallbladder at the neck and could be described as a variation of the Type I, as discussed above (Figure 2).

As can be appreciated, the potential for iatrogenic injury and the disastrous consequences that follow is high if the condition remains undiagnosed with either inadvertent division, or, ligation of the ducts. The diagnosis is usually made intra-operatively, and needs some form of biliary reconstruction to ensure bilio-enteric continuity. Drainage of both the ducts into a roux loop of the jejunum (as roux-en-y hepaticojejunostomy), partial cholecystectomy and choledochoplasty using a cuff of the gallbladder, or, direct suturing of the common hepatic duct to the cystic duct are the available options.<sup>1, 4, 6</sup> If discovered before removal of the gallbladder, partial cholecystectomy and choledochoplasty may be considered the procedure of choice.<sup>6</sup>

### CORRESPONDENCE TO

Dr. Robin Kaushik House No. 132, Sector 6, Panchkula 134 109 Haryana, India Tel - 0172-2570944 Email: robinkaushik@yahoo.com

### References

1. Walia HS, Abraham TK, Baraka A. Gallbladder Interposition: A Rare Anomaly of the Extrahepatic Ducts. Int Surg 1986; 71: 117 - 21.
2. Lamah M, Dickson GH. Congenital anatomical abnormalities of the extrahepatic biliary duct: a personal audit. Surg Radiol Anat 1999; 21: 325 - 7.
3. Lamah M, Karanjia ND, Dickson GH. Anatomical variations of the Extrahepatic Biliary Tree; Review of the World Literature. Clin Anat 2001; 14: 167 - 72.
4. Losanoff JE, Kjossev KT, Katrov E. Hepaticocystic duct - A Case Report. Surg Radiol Anat 1996; 18: 339 - 41.
5. Adkins RB Jr, Chapman WC, Reddy VS. Embryology, Anatomy, and Surgical Applications of the Extrahepatic Biliary System. Surg Clin N Am 2000; 80: 363 - 79.
6. Olsha O, Steiner A, Rivkin LA, Sheinfeld A. Congenital

absence of the anatomic bile duct. Acta Chir Scand 1987; 153: 387 - 90.

7. Losanoff JE, Jones JW, Richman BW, Rangnekar NJ. Hepaticocystic duct: A Rare Anomaly of the Extrahepatic Biliary System. Clin Anat 2002; 15: 314 - 5.

**Author Information**

**Robin Kaushik, M.S.**

Department of Surgery, Government Medical College and Hospital

**A.K. Attri, M.S.**

Department of Surgery, Government Medical College and Hospital