

Anesthetic Management of Retrosternal Goiter Complicated by Superior Vena Cava Syndrome and Obstructive Sleep Apnea: A Case Report

K Wong, Q Hao, M H Entrup

Citation

K Wong, Q Hao, M H Entrup. *Anesthetic Management of Retrosternal Goiter Complicated by Superior Vena Cava Syndrome and Obstructive Sleep Apnea: A Case Report*. The Internet Journal of Anesthesiology. 2019 Volume 38 Number 1.

DOI: [10.5580/IJA.52477](https://doi.org/10.5580/IJA.52477)

Abstract

The anesthetic management of patients with anterior mediastinal mass is challenging. Surgical resection of anterior mediastinal mass under general anesthesia is associated with increased morbidity and mortality due to the risk of complete airway obstruction and cardiovascular collapse. We report the successful anesthetic management of a woman with a large thyroid goiter extending into the anterior mediastinum and causing obstructive sleep apnea (OSA) and superior vena cava (SVC) syndrome.

INTRODUCTION

Perioperative management of patients with anterior mediastinal mass poses significant challenges to anesthesiologists [1-4]. Anesthetic planning and perioperative assessment must be carefully considered for all patients with anterior mediastinal mass undergoing surgical and non-surgical procedures because of their susceptibility for developing cardiorespiratory complications [1-4].

Anterior mediastinal mass may be benign or malignant [2,3]. Common etiologies include lymphoma, thymoma, germ cell tumors, metastatic lesions, bronchogenic masses, and, rarely, thyroid goiter [2,3,5]. Enlargement of mass can compress the heart, lung, tracheobronchial tree, esophagus, and major vessels in the mediastinum, resulting in superior vena cava (SVC) syndrome [2,3]. The majority of these patients presents with dyspnea, chest pain, facial and neck swelling, cough, venous engorgement of chest, dysphagia, dizziness, hoarseness from vocal cord paralysis, jugular venous distention, stridor, cyanosis, and orthopnea [2,4]. Interestingly, a few case reports suggested that obstructive sleep apnea (OSA) may be associated with thyroid goiter [5,6]. Although OSA is associated with obesity, nasal obstruction, and adenotonsillar hypertrophy, the relationship between thyroid goiter and OSA was not well-elucidated in the literature [5].

In most cases, resection of retrosternal goiter is the only effective treatment to resolve SVC syndrome and OSA [6]. However, it is associated with high risk of airway obstruction and cardiovascular collapse upon induction of general anesthesia with an incidence of 7-20% [1,3]. We present the successful anesthetic management of an elderly woman with retrosternal goiter complicated by new onset of OSA and SVC syndrome who underwent total thyroidectomy with partial sternotomy.

CASE REPORT

A 71-year-old obese female with American Society of Anesthesiologists physical status III, body mass index of 35.6 kg/m², height of 165 cm, and weight of 97 kg presented for total thyroidectomy with partial sternotomy. She initially visited the Otolaryngology Clinic for evaluation of bilateral upper extremities edema for the past 8 months. The patient had complaints of intermittent episodes of dyspnea, dysphagia of dry solid food, and malaise. She denied any facial swelling and plethora, muscle weakness, ptosis, and diplopia. She was recently diagnosed with OSA by nocturnal polysomnography but failed to tolerate continuous positive airway pressure (CPAP) device during sleep. Her past medical history was significant for pulmonary hypertension, Sjogrens syndrome, chronic atrial fibrillation, portal hypertension in the setting of primary biliary cirrhosis, and hypertension secondary to hyperaldosteronism. Physical

exam revealed diffuse non-pitting edema of bilateral upper extremities, palpable enlarged neck mass, and venous engorgement of chest and arm vessels. Airway examination showed Mallampati classification III and thyromental distance was more than three finger breadths with full range motion of the neck. Auscultation of the heart revealed an irregularly irregular rhythm and a grade 2/6 systolic ejection murmur. Pulmonary and abdominal examinations were otherwise unremarkable. Preoperative basic metabolic panel, complete blood count, and thyroid function test were normal. Coagulation panel showed prolonged prothrombin time and international normalized ratio from chronic anticoagulation therapy, which was subsequently withheld 7 days prior to surgery. Transthoracic echocardiography (TTE) revealed pulmonary hypertension with an estimated pulmonary artery systolic pressure of 43 mmHg. Computerized tomography (CT) scan of the thorax revealed a massive nodular goiter measuring 8.36 x 5.37 x 8.08 cm with retrosternal extension into the anterior mediastinum (Fig. 1). The mass caused left tracheal deviation with mild narrowing and compression of both brachiocephalic veins at the level of thoracic inlet (Fig. 2). The patient was diagnosed with massive nodular goiter complicated by SVC syndrome. Total thyroidectomy with median partial sternotomy was planned.

Figure 1

Computed tomography scan of the thorax with contrast showed the giant retrosternal goiter.

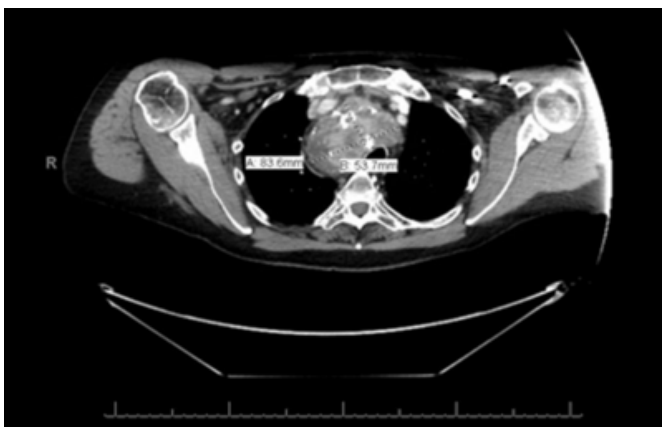
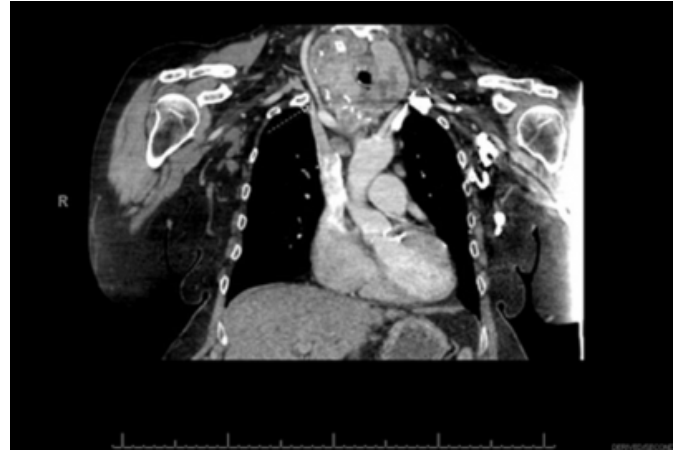


Figure 2

Computed tomography scan of the thorax with contrast showed the extension of thyroid goiter from the neck into the anterior mediastinum, compressing the trachea and major vessels.



A multidisciplinary discussion was held between the anesthesiologist and surgeon to formulate an anesthetic plan that minimized the risks of cardiorespiratory complications. Sedation was initiated with 2.5 mg of midazolam and 75 µg of fentanyl, and 0.2 mg of glycopyrrolate was administered intravenously as an antisialagogue. Following placement of a radial arterial catheter and a second large-bore peripheral intravenous catheter, the oral mucosa was anesthetized topically with 3 mL of 4% lidocaine. Intubation was achieved with the patient maintaining spontaneous ventilation and a flexible bronchoscope. A neural integrity monitor electromyogram tracheal tube was placed to allow continuous auditory feedback to the surgeon to guard against injury to the recurrent laryngeal nerves.

The intraoperative course was uneventful. A conventional transcervical resection with partial sternotomy was performed to surgically remove the retrosternal goiter. The patient was extubated once she was fully awakened and had an uncomplicated post-operative course and was discharged home on post-operative day two. The venous engorgement of her chest and swelling of her upper extremities have gradually subsided over a period of two months, and her daytime somnolence has resolved.

DISCUSSION

Anesthetic management of patients with anterior mediastinal mass and SVC syndrome is complicated. These patients reportedly have increased risks of cardiorespiratory complications due to compression of the airway, great vessels, and heart by local mass effect [1-3]. Obstruction of

the SVC can lead to impaired venous return and result in significantly diminished cardiac output [2,3]. General anesthesia can magnify these changes through vasodilatation in which can produce severe hemodynamic compromise and tissue ischemia [2]. When these patients lose the ability to spontaneously ventilate upon induction of anesthesia, the risk of failed manual ventilation is considerable due to the loss of tracheobronchial smooth muscle tone and compression by the anterior mediastinal mass, decreased functional residual capacity, decreased elastic recoil of alveoli and chest wall, and cephalad displacement of diaphragm by abdominal contents in supine position [2,7]. These cardiorespiratory complications can be difficult to predict solely based on the severity of symptoms caused by anterior mediastinal mass. Careful anesthetic planning must be done properly and thoroughly as the clinical status of these patients can rapidly deteriorate upon induction of anesthesia.

Interestingly, our patient was diagnosed with OSA shortly prior to the diagnosis of retrosternal goiter. OSA is a sleep-related breathing disorder characterized by recurrent episodes of apnea and hypopnea due to partial or complete obstruction of the upper airway during sleep [8]. It is a common comorbidity for surgical patients with an incidence of 5% among the general population [9]. OSA patients overall carry an approximately two-fold increased risk of perioperative complications including hypoxemia, pneumonia, mediastinitis, difficult intubation, myocardial infarction, pulmonary embolism, atelectasis, cardiac arrhythmias, unanticipated admission to the intensive care unit, postoperative sleep-disordered breathing, and increased hospital length of stay [8,10].

To our knowledge, there are only a few case reports about the resolution of OSA with total thyroidectomy [5,6,11]. The pathophysiology of OSA due to thyroid goiter remains poorly understood, and the published evidence for the association between thyroid goiter and OSA remains scarce. Nevertheless, the relief of OSA symptoms of our patient after total thyroidectomy strongly suggests a pathogenic relationship between large goiter and OSA. It is reasonable to speculate that our patient suffered OSA due to pharyngeal edema and tracheal deviation from direct compression of the brachiocephalic veins and trachea by the retrosternal goiter, as evidenced by her chest CT. These anatomical and physiological abnormalities likely reduced the upper airway patency and reflexes of our patient, predisposing her to high

risk of upper airway collapse during anesthesia [9].

Furthermore, our patient failed to comply with the use of CPAP and thereby carried the highest risk of postoperative complications among patients with diagnosed OSA [12]. The noncompliant use of CPAP contributed to the finding of pulmonary hypertension in her recent TTE. Despite normal right atrial pressure and ejection fraction, our patient faced additional risk of right ventricular heart failure, right ventricular myocardial ischemia, and sudden death [13].

Despite adequate preoperative assessment and anesthetic planning, our patient faced markedly high risk of cardiorespiratory collapse due to the combination of SVC syndrome and OSA. Our multidisciplinary team approach between the anesthesiologist and surgeon had effectively coordinated management to address her anterior mediastinal mass, SVC syndrome, OSA, and pulmonary hypertension. A comprehensive anesthetic plan may include multiple therapeutic options, such as repositioning of the patient, placement of a rigid bronchoscope, and initiation of cardiopulmonary bypass, in the event of an emergency cardiorespiratory collapse [2]. As discussed in the literature, awake flexible bronchoscopic intubation should be selected as the technique of choice for patients with anterior mediastinal mass upon induction of anesthesia [3]. The use of benzodiazepine and narcotics should be kept to the minimum to limit respiratory depression [14]. Multimodal analgesia and dexmedetomidine are gaining popularity as opioid-sparing options for sedation and pain control and reduction of post-operative apnea [14]. Such patients should be fully awake and hemodynamically stable prior to extubation as they face high risk of post-extubation complications such as tracheomalacia, laryngospasm, and bronchospasm [3].

References

- [1] Béchar P, Létourneau L, Lacasse Y, Côté D, Bussi res J. Perioperative cardiorespiratory complications in adults with mediastinal mass. *Anesthesiology* 2004;100:826-34.
- [2] Blank RA, de Souza DG. Anesthetic management of patients with anterior mediastinal mass: Continuing Professional Development. *Can J Anesth* 2011;58:853-67.
- [3] Chaudhary K, Gupta A, Wadhawan S, Jain D, Bhadoria P. Anesthetic management of superior vena cava syndrome due to anterior mediastinal mass. *Journal of Anaesthesiology Clinical Pharmacology* 2012;28:242-46.
- [4] Slinger P, Karsli C. Management of the patient with a large anterior mediastinal mass: recurring myths. *Curr Opin Anaesthesiol* 2007;20:1-3.
- [5] Gutierrez T, Leong AC, Pang L, Chevreton E, Jeannon J-P, Simo R. Multinodular thyroid goiter causing obstructive sleep apnoea syndrome. *J Laryngol Otol* 2012;126:190-5.
- [6] Rodrigues J, Furtado R, Ramani A, Mitta N, Kudchadkar

S, Falari S. A rare instance of retrosternal goiter presenting with obstructive sleep apnoea in a middle-aged person. *Int J Surg Case Rep* 2013;4:1064-6.

[7] Gardner JC, Royster RL. Airway collapse with an anterior mediastinal mass despite spontaneous ventilation in an adult. *Anesth Analg* 2011;113:239-42.

[8] Vasu TS, Grewal R, Doghramji K. Obstructive sleep apnea syndrome and perioperative complications: a systematic review of the literature. *J Clin Sleep Med* 2012;8:199-207.

[9] Schneider A, Bourahla K, Petiau C, Velten M, Volkmar PP, Rodier JF. Role of thyroid surgery in the obstructive sleep apnea syndrome. *World J Surg* 2014;38:1990-4.

[10] Mutter T, Chateau D, Moffatt M, Ramsey C, Roos L, Kryger M. A Matched Cohort Study for Postoperative Outcomes in Obstructive Sleep Apnea: Could Preoperative

Diagnosis and Treatment Prevent Complications. *Anesthesiology* 2014;121:707-18.

[11] Schneider A, Bourahla K, Petiau C, Velten M, Volkmar PP, Rodier JF. Role of Thyroid Surgery in the Obstructive Sleep Apnea Syndrome. *World J Surg* 2014;38:1990-4.

[12] Liao P, Luo Q, Elsaid H, Kang W, Shapiro CM, Chung F. Perioperative auto-titrated continuous positive airway pressure treatment in surgical patients with obstructive sleep apnea: a randomized controlled trial. *Anesthesiology* 2013;119:837-47.

[13] Minai O, Yared J, Kaw R, Subramaniam K, Hill N. Postoperative Risk and Management in Patients with Pulmonary Hypertension. *Chest* 2013;144:329-40.

[14] Chung F, Liao P, Elsaid H, Shapiro C, Kang W. Factors associated with postoperative exacerbation of sleep-disordered breathing. *Anesthesiology* 2014;120:299-311.

Author Information

Kevin Wong, DO

Anesthesiology Resident; Division of Anesthesiology, Geisinger Medical Center
Danville, PA

Qingzhong Hao, MD, PhD

Staff Anesthesiologist; Division of Anesthesiology, Geisinger Medical Center
Danville, PA

Michael H. Entrup, MD

Anesthesiology Residency Program Director; Division of Anesthesiology, Geisinger Medical Center
Danville, PA