

# Symptomatic Retrosternal Dislocation Of The Clavicle

K Moholkar, P Tamblyn

## Citation

K Moholkar, P Tamblyn. *Symptomatic Retrosternal Dislocation Of The Clavicle*. The Internet Journal of Rescue and Disaster Medicine. 1999 Volume 2 Number 1.

## Abstract

The authors report a case of a 24-year-old man who injured his right shoulder playing football. After reviewing the plain x-rays of his shoulder, the patient was sent home after explaining that he had a minor sprain of the sternoclavicular joint. The patient returned 72 hours later with pain, severe swelling on the sternoclavicular region, dilated veins on the right upper limb, dysphagia and had difficulty in breathing. A computerized tomogram revealed complete posterior dislocation of the sternoclavicular joint with compression of the right innominate vein. The patient was taken to the theatre and had reduction of the sternoclavicular joint. All the symptoms subsided very shortly after the reduction procedure. The authors discuss the case and the management of the injury.

## INTRODUCTION

Rodriguez, in 1843 was the first to publish a case report of a traumatic posterior dislocation of the sternoclavicular joint. It is a relatively rare injury and may be difficult to diagnose if it is not suspected<sup>1</sup>. Early closed reduction is very important if instituted within twenty-four to forty-eight hours of injury and if reduction can be obtained by closed methods and maintained, the prognosis would seem very good.<sup>2</sup> Attendant complications include trauma to the great vessels, venous congestion, breathing difficulties and decreased circulation to the ipsilateral arm.

Diagnosis by means of conventional radiographs of the sternoclavicular joint is difficult to interpret<sup>1</sup>. Suspicion is the most important single faculty necessary for diagnosis. The rarity of this lesion makes, even an experienced examiner miss the diagnosis unless appropriate radiographs are made<sup>2</sup>.

Urist<sup>3</sup> suggested that two factors are important in the diagnosis of this condition.

## CASE REPORT

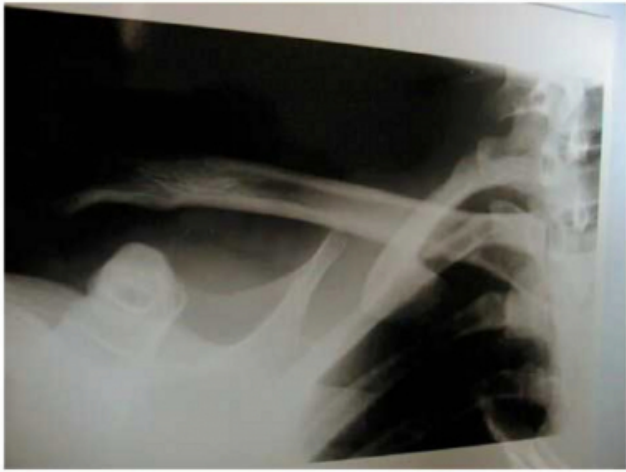A 23 year old male injured his shoulder while playing football and was seen in a district hospital with plain radiographs of the shoulder and sternoclavicular joint (Fig.1). His injury was interpreted as a sprain of the Sternoclavicular joint and he was discharged home. He reported to the Casualty department at the Flinders Medical Centre 72 hours later with pain and swelling at the medial

end of the clavicle, dilated and engorged upper limb veins, dysphagia and difficulty in breathing. Clinical examination suggested posterior dislocation of the medial end of the clavicle with possible encroachment of the great vessels, trachea and the oesophagus. Plain Roentgenograms were suspicious of a posterior dislocation of the medial end of the clavicle. Computerized Tomograms (CT) revealed posterior dislocation of the medial end of the clavicle with a superior mediastinal haematoma and compression of the innominate vein with pressure on the oesophagus and trachea (Fig.2). An urgent arch aortogram was arranged which showed compression of the right innominate vein. He was taken to the theatre for urgent reduction with the vascular and thoracic team standing by. Three attempts at close reduction with the arm abducted to 90° and extended 20° were unsuccessful. With the help of a towel clip gripping the medial end of the clavicle through the skin a further attempt at reduction gave an audible clunk. Clinically it was not possible to palpate the medial end of the clavicle with perfection as there was a significant amount of swelling.

Engorgement of the arm veins decreased dramatically. He was immobilized in a figure of eight bandage. There were no significant postoperative complications.

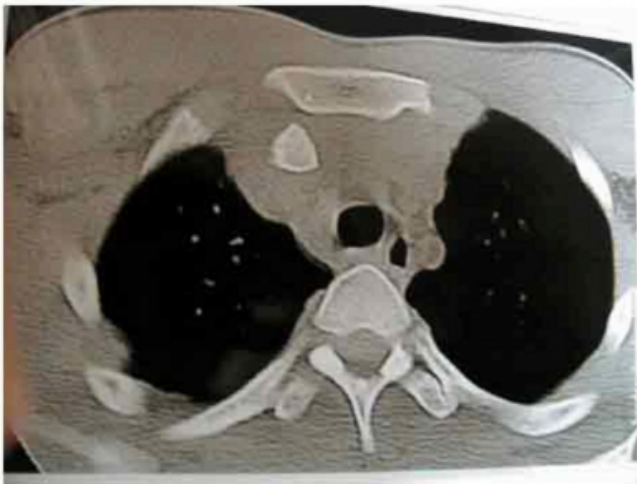**Figure 1**

Fig 1.AP view of the Shoulder



**Figure 2**

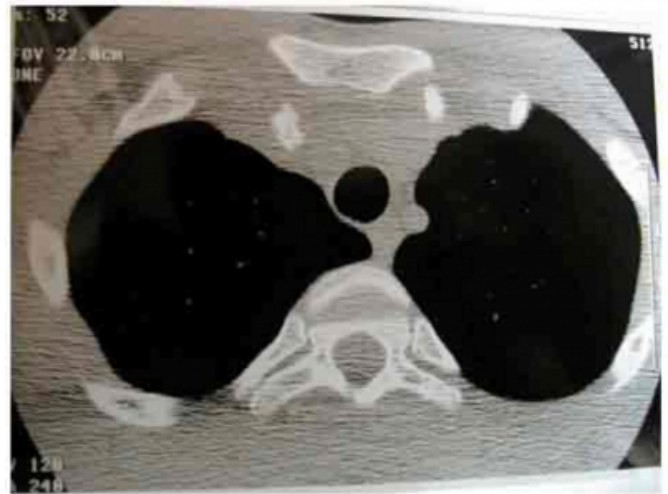
Figure 2.CT scan of the Sternoclavicular Joint revealing the posterior dislocation and the mediastinal oedema



Symptomatically the patient felt relieved and the dysphagia and dyspnoea settled. We assessed him 3 months after the trauma when the patient was completely asymptomatic and the CT scans revealed partial reduction of the medial end of the clavicle (Fig.3).

**Figure 3**

Figure 3. CT scan 6 weeks post reduction shows partial reduction and resolved mediastinal swelling



### DISCUSSION

There must be an early clinical suspicion of retrosternal dislocation of the clavicle if the diagnosis is to be established expeditiously. A history of injury with pain at the sternoclavicular joint aggravated with movements of the shoulder should arouse a vital doubt in the mind of the clinician. This symptom complex with accompanied depression at the medial end of clavicle with signs of compression of the mediastinal structures if left untreated could lead to grave complications.

Routine roentgenograms are not always helpful to diagnose this condition as in our case but CT scans delineate the dislocation with the relation of the surrounding vital mediastinal structures. CT scan should be done if there is suspicion of a posterior dislocation of the medial end of clavicle especially if associated with occult vascular compression. We think our patient had a similar kind of injury and the dislocation was partially reduced which was sufficient to relieve the compressive signs and symptoms.

CT scans taken 1 month postoperatively proved that there was healing with periosteal sleeve calcification. The epiphysial injuries at the medial end of the clavicle can heal satisfactorily even with partial reduction sufficient to relieve the compression on the vital structures and that the healing occurs with a periosteal sleeve formation eventually giving a stable sternoclavicular joint.

### CONCLUSION

Knowledge about the sternoclavicular joint dislocation is extremely important. Plain radiographs are deceptive and

incomplete to investigate a possible sternoclavicular joint dislocation. If one suspects a sternoclavicular joint injury Compuetrised Tomograms are more reliable in diagnosing this lesion.

### **References**

1. Denham RH, Jr., and Dingley AF, Jr.: Epiphyseal Separation of the medial end of the clavicle. J. Bone And Joint Surg., 49-A:1179-1183, Sept. 1967.
2. Allman FL, Jr.: Fractures and Ligamentous Injuries of the clavicle and its articulations. J. Bone and Joint Surg., 49-A: 774-784. June 1967.
3. Urist MR: Complete dislocation of the acromioclavicular joint. The nature of the traumatic lesion and effective methods of treatment with an analysis of forty-one cases. J. Bone And Joint Surg., 28:813-837, 1946.

**Author Information**

**Kirti Moholkar, MS, FRCS**

Fellow in Arthroplasty and Arthroscopy, Department of Orthopaedics, Surgery, Waterford Regional Hospital

**Peter Tamblyn, FRACS**

Consultant Orthopaedic Surgeon, Department of Orthopaedic Surgery, Surgery, Flinders Medical Center