

Meckel's Diverticulitis Secondary To Actinomycosis Case Report And Review Of The Literature

T Soleymani, R Spira, N Parikh, S Mody

Citation

T Soleymani, R Spira, N Parikh, S Mody. *Meckel's Diverticulitis Secondary To Actinomycosis Case Report And Review Of The Literature*. The Internet Journal of Gastroenterology. 2009 Volume 9 Number 2.

Abstract

Meckel's diverticulum has an incidence of 2%. The lifetime risk of complications is 4%. Diverticulitis accounts for 20% of the complications. Multiple organisms have been reported to cause this inflammation: Actinomyces, Schistosoma mansoni, Taenia saginata, and Ascaris lumbricoides. We present a case of Meckel's diverticulitis complicated by Actinomycosis in a young female presenting with peri-umbilical abdominal pain. Meckel's diverticulitis and abdominal Actinomycosis are both rare entities; the combination of the two has only been reported once. We hope that this case report will raise the index of suspicion of our readers to include Meckel's diverticulitis secondary to actinomycosis in their next differential diagnosis of abdominal pain.

CASE REPORT

We report a case of a 37-year-old female with past medical history significant for Diabetes Mellitus Type-II who presented with a 3-day history of peri-umbilical abdominal pain. The pain was described as constant, non-radiating, and was associated with nausea and vomiting. Coughing and sneezing exacerbated the abdominal pain. Abdominal pain was not exacerbated by eating food. The patient denied any fever, diarrhea, constipation, urinary symptoms, or vaginal bleeding. Last bowel movement was on the day of admission, and it was reported as normal. Last menstrual period was 14 days prior to admission. No menstrual cycle abnormalities were reported. No history of intra-uterine device usage. The patient had experienced a similar episode 11 months ago. At that time she underwent a colonoscopy; which was essentially benign and her symptoms subsequently resolved. On admission vitals were stable. Abdominal examination was significant for an obese abdomen and tenderness on palpation of epigastric, right upper quadrant and peri-umbilical region. No rigidity, guarding, or rebound tenderness were appreciated. No mass was palpated. Guaiac was negative. Laboratory work up revealed: white blood cell count (WBC = $21.7 \times 10^3/\text{microL}$), hemoglobin (Hgb = 12.4 gm/dL), total bilirubin (TB = 0.9 mg/dL), alkaline phosphatase (AP = 84 IU/L), aspartate aminotransferase (AST = 19 IU/L), alanine aminotransferase (ALT = 13 IU/L), amylase = 41 IU/L, lipase = 19 U/L, and glucose = 209 mg/dL. The patient received nothing by mouth (NPO) and was started on Ciprofloxacin 400 mg IV

Q12hrs and Metronidazole 500mg IV Q8hrs. Ultrasound of abdomen and pelvis revealed fibroid uterus. There was no evidence of gallstones, common bile duct dilatation or hydronephrosis. CT scan of the abdomen with oral contrast performed on the night of admission revealed no definite radiographic evidence of acute appendicitis although appendix was not visualized, and the repeat of study with proper amount of oral contrast and proper delay was suggested. Repeat CT scan of abdomen after 8 hours of the first study revealed a 5 by 3 cm non-contrast filled loop of bowel in the right mid abdomen surrounded by contrast filled loops of small bowel (Fig. 1). The appendix was again not clearly visualized. The differential diagnosis included Meckel's diverticulum, loop of bowel in the internal hernia, and an abscess. The patient was subsequently taken to the OR and underwent an exploratory laparotomy with Meckel's diverticulum resection, appendectomy, and partial small bowel resection with anastomosis. Pathology report showed a segment of small bowel with attached diverticulum in the center, measuring 7.5 cm in length and 2-3 cm in diameter (Fig. 2). The serosal surface of diverticulum was tan-brown, congested, and covered by purulent material. No ectopic tissues were detected on histology. The longitudinal dissection revealed distended lumen filled with thick, white, cloudy fluid; consistent with an abscess, which grew actinomycosis (Fig. 3). Final diagnosis: acute suppurative Meckel's diverticulitis with actinomycosis. The patient was discharged on post-op day two, with resolution of her symptoms. The patient was treated with Ciprofloxacin

400mg PO Q12 hrs. and Metronidazole 500mg PO Q8 hrs. for a total of 15 days. Seven months post operation patient presented with symptoms of small bowel obstruction secondary to surgical adhesions requiring surgical correction. In one year follow up patient is doing well, and continues to be asymptomatic.

Figure 1

Figure 1. CT of abdomen and pelvis enhanced with oral and intravenous contrast reveals a 5 × 3 cm non-contrast filled loop of bowel in the right mid abdomen.

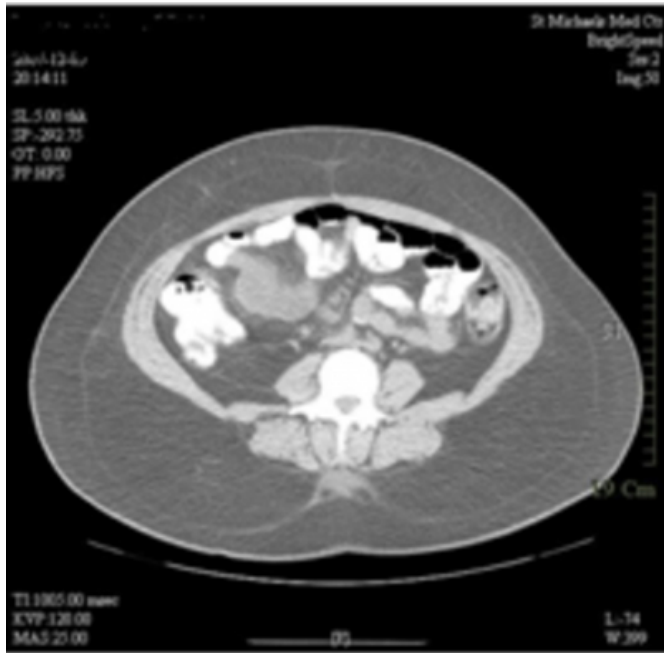

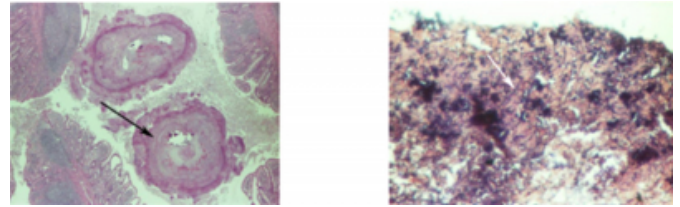
Figure 2

Figure 2. Gross specimen: segment of small bowel (thick arrow) with attached diverticulum (thin arrow) in the center, measuring 7.5 cm in length and 2-3 cm in diameter filled with purulent material.



Figure 3

Figure 3. Histomorphology of Actinomycosis: A. Hematoxylin and Eosin (H & E) stain reveals sulfur granules enveloped by purulent exudate, B. Gram stain reveals filamentous branching gram positive bacteria.



DISCUSSION

Meckel's diverticulum is a true congenital diverticula resulting from an incomplete obliteration of the vitelline duct – connecting the midgut to the yolk sac during the embryonic stage - by the 7th week of gestation. It is present in 2% of the population with a male to female ratio of 3:1. It is located within 40-100 cm of the ileocecal valve; and it measures between 1 to 10 cm in length^{1,2,3}. Fifty percent of the Meckel's diverticulum contain an ectopic tissue, with gastric and pancreatic tissue being the most common². The life time risk of Meckel's diverticulum complication is 4%⁶. Symptomatic complications from most to least common are: painless bleeding per rectum, intestinal obstruction, diverticulitis, perforation, and intussusception^{6,20}.

1. Painless bleeding per rectum: is the most common complication (27%)^{7, 8, 20}. It is secondary to the ectopic gastric tissue residing inside the Meckel's diverticulum; which results in the ulceration of the diverticulum and nearby ileum. This complication generally occurs in the pediatric population, presenting with painless rectal bleeding. The initial diagnostic test of choice in this setting is Meckel's scan, where the intravenous injection of 99mTc-pertechnetate is taken up by the mucus-secreting cells of the gastric epithelium visualizing the location of gastric tissue in the Meckel's diverticulum.
2. Intestinal obstruction: accounts for 24% of the Meckel's diverticulum complications^{7, 8, 20}. It is secondary to intussusception with the diverticulum serving as the lead point. It can also occur secondary to herniation or volvulus of the intestine around the vestigial vitelline duct – a fibrous cord connecting the umbilicus to the ileum. Intestinal obstruction can occur at any age; however volvulus and intussusception most commonly occur in the

neonates and children respectively. Patient would present with obstructive symptoms: projectile bilious vomiting, abdominal pain and distension. Plain abdominal radiography, enteroclysis, and CT scan of the abdomen are the available diagnostic modalities. Ischemia and perforation are the two feared complications.

3. Diverticulitis: accounts for 20% of the Meckel's diverticulum complications^{7, 8, 20}. The pathogenesis of this complication has been compared to appendicitis. The inflammation could result from obstruction of the diverticula's orifice by fecalith material, foreign body, or tumor. This obstruction will lead to increase pressure of the lumen, venous hypertension, ischemia of the wall, necrosis, and perforation². The obstruction can also lead to stasis and subsequent bacterial infection. Peptic ulceration of the Meckel's diverticulum and ileal mucosa secondary to the ectopic gastric tissue is another mechanism by which inflammation can occur.

Patients with Meckel's Diverticulitis usually present with a right lower quadrant or peri-umbilical abdominal pain. Therefore inflammation of Meckel's diverticulum in an acute setting is commonly misdiagnosed as appendicitis. The correct diagnosis of Meckel's diverticulitis is often made intra-operatively. CT of abdomen with intravenous and oral contrast has proven to be a useful tool to making the correct diagnosis pre-operatively. The largest study on CT findings of Meckel's diverticulitis was done by Genevieve L Bennett et al³. This retrospective study reviewed eleven cases of Meckel's diverticulitis and described the characteristic CT findings. The key to correct diagnosis is giving enough time to oral contrast to achieve complete opacification of bowel loops, in specific the ileocecal bowel. This thorough opacification will allow identification of normal appendix and visualization of Meckel's diverticulum; which is important in differentiating appendicitis from Meckel's diverticulitis as a diagnosis. This differentiation becomes difficult in the setting of small bowel obstruction, secondary inflammation of the appendix, and right lower quadrant location of Meckel's diverticulum³. The CT description of Meckel's diverticulum is: a blind end tubular structure that mostly contains fluid, air, or particulate material; therefore the lumen does not contain any oral contrast. The wall of the diverticulum is contrast enhanced like the rest of the bowel; and in its absence one should suspect gangrenous

diverticulum. The majority (67%) of Meckel's diverticulum are located at or near the mid-line³. Symptomatic complications of the Meckel's diverticulum: hemorrhage, intestinal obstruction, diverticulitis, and umbilico-ileal fistula; are absolute indications for resection. In asymptomatic Meckel's diverticulum several factors contribute to increased incidence of complications: male gender, age less than 50 years old, ectopic tissue (suggested by thickened Meckel's diverticulum), diverticuli less than 2 cm in length, height:diameter ratio less than 2, and narrow neck^{4, 18, 20}. In a retrospective study of 29 patients with Meckel's diverticulum McKay found that patients with symptomatic Meckel's diverticulum were more likely to be less than 50 years of age and to have heterotrophic tissue. Resection of asymptomatic Meckel's diverticulum in a patient less than 50 years of age was found to be beneficial in comparison to a patient older than 50 years of age²⁰.

Actinomyces species are gram positive, filamentous, facultative anaerobes. Currently 92 Actinomyces spp. have been identified. The organism is a normal inhabitant of the mucus membrane: mouth, gastrointestinal tract, bronchi, and vagina. Once the integrity of the mucosal barrier has been compromised Actinomyces becomes pathologic and begins an indolent infection-Actinomycosis. The breach of the mucosal barrier can be secondary to: poor oral hygiene and dentition, aspiration, neoplasm, trauma, foreign body penetration, perforated appendicitis, or insertion of IUD. Actinomycosis is most commonly caused by *A. israelii*, *A. naeslundii*, *A. odontolyticus*, *A. viscosus*, *A. meyeri*, and *A. gerencseriae*¹³. The acute phase of the infection is commonly missed. Over time the infection will spread contiguously across tissue planes invading the surrounding tissue and other organs. The indolent chronic infection is characterized by lesions containing necrotic tissue, neutrophils, and sulfur granules walled off by a fibrotic tissue described as "wooden". The tendency to form masses and invade tissues and other organs results in common misdiagnosis of cancer for actinomycosis; hence referred to as "Actinomycosis a great pretender"¹⁶.

Actinomycosis accounts for more than 50% of Cervico-facial infections, 15-20% of thoracic infections, and 10-20% of abdominal and pelvic infections^{15, 14}. Although all abdominal organs can be infected, ileocecal area is the site most commonly affected by actinomycosis, with the appendix predominating¹⁴. Actinomyces resides in areas of stagnation: appendix and cecum. Disruption of the mucosal barrier is required for this organism to become pathologic:

appendicitis, diverticulitis, gastrointestinal perforation, abdominal surgery, foreign bodies, or neoplasia¹⁵. It is a challenge to clinically diagnose abdominal actinomycosis. In the setting of acute inflammation abdominal tenderness and guarding may be present, while in a chronic setting a mass maybe palpated during the abdominal examination. It is this broad and non-specific presentation that leads to misdiagnosis of appendicitis, inflammatory bowel disease, or carcinoma. The only radiographic study that could aid in the diagnosis of abdominal actinomycosis is CT with contrast. CT findings include intra or extra luminal masses that are infiltrative in nature¹⁵. In most cases the masses are solid with focal areas of diminished attenuation; or less commonly the masses are cystic with thickened walls¹⁷. CT guided biopsy or aspiration will also aid in microscopic identification of sulfur granules. Although other organisms such as *Nocardia*, *Streptomyces*, and *Staphylococci* (in botryomycosis) can also contain sulfur granules; specific microbiologic studies differentiate these organisms. *Actinomyces* is a strict anaerobe that partially stains acid-fast, and produces sulfur granules. It grows as filamentous branching gram positive bacteria. The 16sRNA gene amplification and sequencing could also identify the *actinomyces* species¹³.

Treatment of actinomycosis is based on the sensitivity of the organism. However Penicillin has proven to be an effective treatment: 18-24 million units intravenously daily for 2-6 weeks followed by oral therapy for 6-12 months with penicillin or amoxicillin¹³. Tetracycline and erythromycin are appropriate alternatives in Penicillin allergic patients. An intensive and long duration of treatment is required, in order to penetrate the thick wall of the mass and the sulfur granules. The recurrent characteristic of the infection also necessitates prolonged treatment. The success of the treatment can be monitored via CT or MRI. Although controversial, medical management of the infection should always be the first approach before any surgical attempts¹³.

This case is a unique presentation of Meckel's diverticulitis complicated by actinomycosis. Diverticulitis is an uncommon initial presentation of Meckel's diverticulum. Bleeding and obstruction are the more common complications. Diverticulitis of the colon is a complication most commonly seen in older patients, age greater than fifty years. However in Meckel's diverticulum the risk of complications including diverticulitis is most commonly seen in patients less than fifty years of age. Therefore our patient's age of less than 50 years placed her at a greater risk

for Meckel's diverticulum complications. Also, her history of Diabetes Mellitus was a risk factor for infection with Actinomycosis. Our patient remains asymptomatic in one year follow up secondary to surgical removal of the source of infection.

References

1. Khan E, Daum F. Anatomy, Histology, Embryology, and Developmental Anomalies of the Small and Large Intestine. In: Feldman M, Friedman L, Brandt L. Sleisenger and Fordtran's Gastrointestinal and Liver Disease: pathophysiology, diagnosis, management. Philadelphia, PA: SAUNDERS ELSEVIER; 2006: 2061-2091
2. Sarosi GA, Turnage RH. Appendicitis. In: Feldman M, Friedman L, Brandt L. Sleisenger and Fordtran's Gastrointestinal and Liver Disease: pathophysiology, diagnosis, management. Philadelphia, PA: SAUNDERS ELSEVIER; 2006: 2599-2612
3. Genevieve BL, Bernard BA, Emil BJ. CT of Meckel's Diverticulitis in 11 patients. American Journal of Roentgenology. 2004; 182: 625--629.
4. Arnold JF, Pellicane JV. Meckel's Diverticulum: A Ten Year Experience. American Surgeon. 1997; 63:354--355.
5. Nagler J, Clarke JL, Albert SA. Meckel's Diverticulitis in an Elderly Man Diagnosed by Computed Tomography. Journal of Clinical Gastroenterology. 2000; 30: 87--88.
6. Kusomoto H, Yoshida M, Takahashi I, et al. Complications and Diagnosis of Meckel's Diverticulum in 776 patients. The American Journal of Surgery. 1992; 164:382--383.
7. Ymaguchi M, Takeuchi S, Awazu S. Meckel's Diverticulum. Investigation of 600 patients in Japanese literature. The American Journal of Surgery. 1978; 136: 247--249.
8. Turgeon DK, Barnett JL. Meckel's Diverticulum. The American Journal of Gastroenterology. 1990; 85: 777--781.
9. Portnoy O, Gayer G, Onaca N, et al. Abdominal Computerized Tomography in the Diagnosis of Meckel's Diverticulitis in the Adult. Israel Medical Association Journal: Imaj. 2001; 3: 982--983.
10. Arya B, Azarhoush R, Gopalipour MJ. Meckel's Diverticulitis Due To Actinomycosis. Journal of Medical Sciences. 2007; 7: 916--919.
11. Haynes S, Reid HAS. Meckel's Diverticulitis Due to Schistosomiasis Mansoni. The American Journal of Gastroenterology. 1976; 66:559--561.
12. Chirdan LB, Yusufu LMD, Ameh EA, et al. Meckel's Diverticulitis Due To Taenia Saginata: Case Report. East African Medical Journal. 2001; 78:107--108.
13. Russo TA. Actinomycosis. In: Fauci A, Braunwald E, Kasper D, Hauser S, Lango D, Jameson JL, Loscalzo J. Harrison's Principles of Internal Medicine. New York, NY: McGraw Hill Medical; 2008:996-999.
14. Garner JP, Macdonald M, Kumar PK. Abdominal Actinomycosis. International Journal of Surgery. 2007; 5: 441-448.
15. Cintron JR, Alberto DP, Bernardo D, et al. Abdominal Actinomycosis: Reprt of Two Cases and Review of the Literature. Diseases of the colon and Rectum. 1996; 39: 105--108.
16. Francisco A, Baudrand R, Letelier LM, et al. Actinomycosis: A Great Pretender. Case Report of Unusual Presentation and a Review of Literature. International Journal of Infectious Disease. 2008; 12: 358--362.
17. Ha HK, Lee HJ, Kim HJ, et al. Abdomianal actinomycosis: CT findings in 10 patients. American Journal

of Roentgenology. 1993; 161: 791--794.

18. Ludtke FE, Mende V, Kohler H, et al. Incidence and Frequency of Complications and Management of Meckel's Diverticulum. Surgery, Gynecology, Obstetrics. 1989; 169:537--542.

19. Kusomoto H, Yoshida M., Takahashi I, et al. Complications and Diagnosis of Meckel's Diverticulum in 776 Patients. The American Journal of Surgery. 1992; 164:382--383.

20. McKay R. High Incidence of Symptomatic Meckel's Diverticulum in Patients Less Than Fifty Years of Age: An

Indication for Resection. The American Surgeon. 2007; 73: 271--275.

21. Dumper J, Mackenzie S, Mitchell P, et al. Complications of Meckel's diverticula in adults. Canadian Journal of Surgery. 2006; 49: 35--357.

22. Stone PA, Hofeldt MJ, Campbell JE, et al. Meckel Diverticulum: Ten-year Experience in Adults. Southern Medical Journal. 2004; 97: 1038--1041.

23. Lippes J. Pelvic actinomycosis: A review and preliminary look at prevalence. American Journal of Obstetrics and Gynecology. 1999; 180: 265--269.

Author Information

Taraneh Soleymani, MD

Department of Internal Medicine, St. Michael's Medical Center

Robert S. Spira, MD

Department of Gastroenterology, St. Michael's Medical Center

Nalini S. Parikh, MD

Department of Surgical Pathology and Clinical Laboratories, St. Michael's Medical Center

Suresh Mody, MD

Department of Medical Imaging, St. Michael's Medical Center