

# Acute massive lower gastrointestinal bleeding from a rectal Dieulafoy-like lesion in a patient with chronic liver disease

A Aghenta, S Devgun, T Kothari

## Citation

A Aghenta, S Devgun, T Kothari. *Acute massive lower gastrointestinal bleeding from a rectal Dieulafoy-like lesion in a patient with chronic liver disease*. The Internet Journal of Gastroenterology. 2008 Volume 8 Number 1.

## Abstract

Recurrent and life threatening gastrointestinal hemorrhage occur rarely from Dieulafoy's lesions. Initially described in the gastric lesser curvature, these lesions have been described in other parts of the gastrointestinal tract. We report a case of acute massive lower gastrointestinal bleeding from a rectal Dieulafoy-like lesion in a patient with a history of chronic liver disease. An overview of the possible etiology and management of this rare presentation is presented.

## INTRODUCTION

Dieulafoy's lesions are a rare cause of massive and life threatening gastrointestinal (GI) hemorrhage. <sup>1</sup> Initially described in the lesser curvature of the stomach, this lesion has been described in other parts of the gastrointestinal tract, and in the bronchus. <sup>1</sup> We report a rare case of massive lower gastrointestinal bleeding from a rectal Dieulafoy-like lesion in a patient with a history of chronic liver disease (CLD).

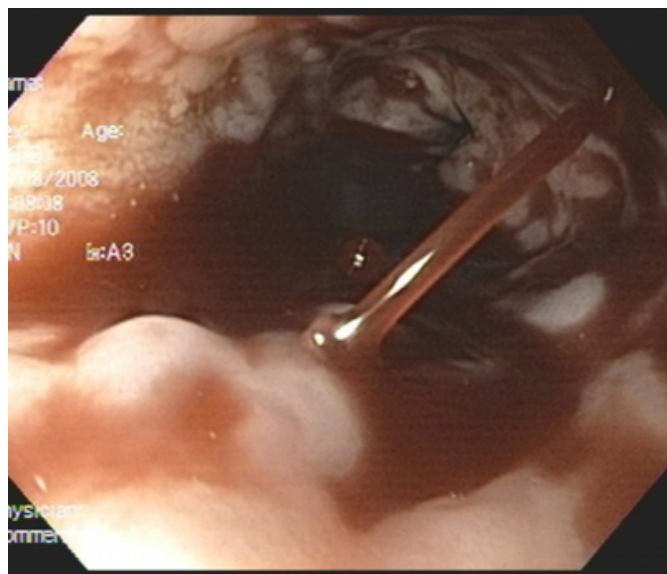
## CASE

A 45 year old male with a history of alcohol abuse, chronic Hepatitis C infection, and liver cirrhosis with known esophageal varices and portal hypertension was seen in the emergency department. He presented with a 3 week history of upper abdominal pain, nausea, coffee ground emesis and passage of melena stools. He had no prior history of GI bleeding. His home medications included omeprazole, and antidepressants. On admission, hemoglobin was 5.9 g/dL, platelet count 99,000 and prothrombin time 19.9 sec. His pulse and blood pressure were 105 and 124/61 mmHg, respectively, without orthostatic changes. He was transferred to the Intensive Care Unit (ICU) due to concern for acute change in mental status, and was transfused with a total of 6 units of packed red blood cells (PRBC). Upper endoscopy done the following morning revealed non bleeding grade 1-2 esophageal varices and portal hypertensive gastropathy. On hospital day 3, he developed acute respiratory distress necessitating endoscopic intubation. The following day, he developed diarrhea and a rectal tube (Flexi-Seal, ConvaTec, Skillman, New Jersey) was inserted for ease of drainage. Diarrhea continued intermittently. He remained critically ill

and was managed for alcohol withdrawal, acute respiratory distress syndrome (ARDS), and aspiration pneumonia. He was on lorazepam, thiamine, multivitamins, haloperidol, vancomycin and piperacillin-tazobactam. On day 14 of admission, he suddenly began passing bright red blood per rectum. The rectal tube was promptly taken off but he continued to bleed massively. Blood pressure was 80/62 mmHg and heart rate 92. Nasogastric aspirate revealed no blood. Physical examination revealed a distended but soft and non-tender abdomen. Examination of the anal region revealed active bleeding with lots of clots. Hemoglobin dropped to 6.7 g/dL from 9.2 g/dL, platelet count was 41,000, and prothrombin time 21.6sec. He was aggressively resuscitated with intravenous fluids, 6 units of PRBC, 6 units of fresh frozen plasma and one unit of platelets. Emergent colonoscopy revealed fresh blood coating the colon with large clots in the rectum. The ileum was clear of blood. Following meticulous lavage and thorough inspection, an area of active spurting of blood was identified in the distal rectum about 4 cm proximal to the anal verge, anteriorly. Hemostasis was secured by injecting a total of 17 mL of 1:10,000 epinephrine interspersed with the application of 3 endoclips. (Figures 1-3) No visible erosion or ulceration was identified. There were no further bleeding episodes and he remained hemodynamically stable but critically ill. Three days after the episode, care was withdrawn in keeping with his family's decision, and he passed peacefully thereafter. The cause of death was unrelated to the massive GI bleed episode.

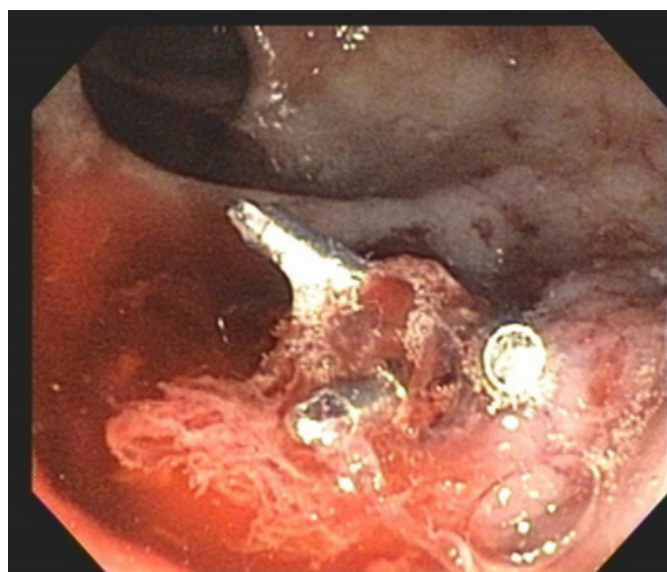
**Figure 1**

Figure 1: Active spurting of blood in the rectum



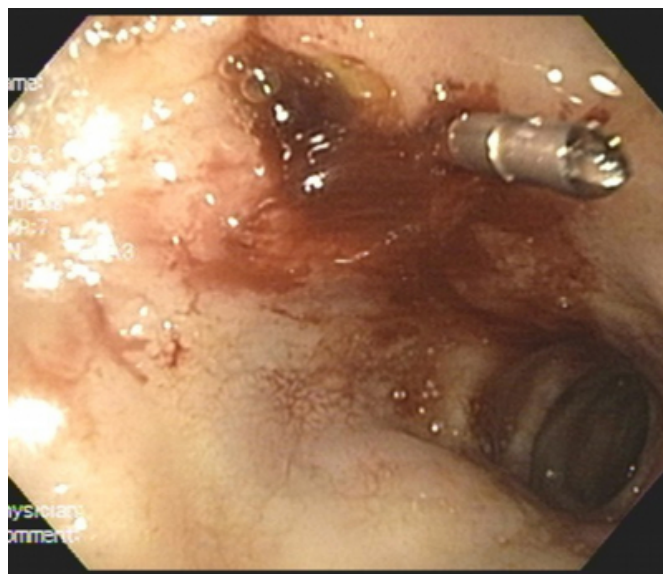
**Figure 2**

Figure 2: Endoclips application



**Figure 3**

Figure 3: Hemostasis secured.



## DISCUSSION

Dieulafoy's lesions are a rare cause of massive, and often recurrent gastrointestinal bleeding first described by the French surgeons Gallard<sup>2</sup> in 1884 and Dieulafoy<sup>3</sup> in 1896. Initially characterized as a lesion in the lesser curvature of the stomach, similar lesions have been found in other parts of the gastrointestinal tract.<sup>14</sup> Histologically, a Dieulafoy's lesion is defined as an unusually large tortuous artery of diameter 1-3 mm, lying submucosally.<sup>5</sup>

Dieulafoy's lesions are estimated to be the cause of upper gastrointestinal hemorrhage in up to 5.8 % of cases.<sup>6</sup> In a retrospective review of 90 cases by Norton et al,<sup>7</sup> about 30% of Dieulafoy's lesions were found to be extragastric, with 10% located in the colon. Lower GI bleeding from rectal Dieulafoy's are rare; the first reported case was published in 1991.<sup>8</sup> The clinical presentation is characterized by the sudden development of profuse, painless and recurrent bleeding resulting in hemodynamic instability, leading to blood transfusions.<sup>9</sup>

The pathogenesis of Dieulafoy's disease is uncertain. Many authors believe Dieulafoy's lesions are congenital and bleeding results from rupture of an abnormal tortuous artery.<sup>110</sup> The exact cause of this rupture is unknown, but several theories exist. Voth in 1962 proposed the theory of "caliber persistent arteriole."<sup>112</sup> This theory suggests that failure of gradual tapering in the muscular caliber of the artery during developmental penetration of the bowel wall results in an abnormally large artery reaching the submucosa in

Dieulafoy's disease.<sup>1112</sup> Potentially, several local factors could cause mucosal ulceration and rupture of the submucosal artery.<sup>13</sup> More widely accepted however is the theory that pulsation of the abnormally large artery generates a mechanical force which causes localized ischemic damage, leading to erosion of the superjacent mucosa. The pulsating artery thereby exposed to gastric or bowel contents starts to erode, and then ruptures.<sup>1415</sup> Other suggested factors include mucosal atrophy and medial degeneration related to aging, mucosal injury resulting from the use of alcohol or nonsteroidal anti-inflammatory drugs, and mucosal stercoral ulceration from compact feces in the colon.<sup>81013</sup>

Correctly identifying and diagnosing Dieulafoy's lesion is often difficult. This may be due to a poor visual field resulting from massive bleeding and/or a poorly prepared bowel, and the tiny size of the Dieulafoy lesion.<sup>13</sup> The characteristic endoscopic appearance of Dieulafoy's lesion includes active blood spurting from a tiny mucosal defect less than 3mm; in the absence of bleeding, a clot without a surrounding ulcer; and, observation of a small vessel with or without bleeding standing out from normal appearing mucosa.<sup>116</sup>

Our case presents certain unique features. We have reported a case of rectal Dieulafoy-like lesion resulting in massive lower GI bleeding in a patient with a history of chronic liver disease. He had prior documented finding of esophageal varices and portal hypertension without a previous history of GI bleeding. It is unclear why he was not on b-blockers. Initially presenting with coffee ground emesis and melena stools, upper endoscopy revealed non bleeding esophageal varices and portal hypertensive gastropathy. Although not actively bleeding, he likely bled from these lesions prior to hospitalization. Two weeks into his admission complicated by other critical medical conditions, he suddenly bled massively per rectum, requiring transfusions, and emergent colonoscopy which detected active spurting of blood in the rectum. Hemostasis was successful. Although no mucosal defect or artery was visible on endoscopy, a confident assessment of a Dieulafoy-like lesion as the cause of bleeding was made based on the active visible spurting of blood. It is possible that a minute break in mucosa may have been missed at endoscopy.

Could the rectal tube have some role to play in this case? It is possible that the rectal tube may have resulted in a mechanical injury to the mucosa. Furthermore, the external mechanical injury from the rectal tube may have been

superimposed on a weakened spot on the rectal wall generated by an underlying pulsating abnormal submucosal artery<sup>1415</sup> resulting in a Dieulafoy's lesion-like bleeding.

The possible clinical association between CLD and Dieulafoy's lesions has been reported. Arkhras et al<sup>17</sup> in a retrospective study of 4569 endoscopy cases found Dieulafoy's lesions as the cause of upper GI bleeding in 6 patients (0.13%). 5 of the 6 patients were found to have CLD, with the Dieulafoy's lesions distributed between the stomach and duodenum. The only prior reported case of rectal Dieulafoy's lesion in a patient with CLD to our knowledge, was reported by Apiratpracha et al.<sup>18</sup>

In patients with CLD, there is a possibility of massive gastrointestinal bleeding arising from other causes. Review of the literature for causes of massive gastrointestinal bleeding in patients with CLD revealed rare disorders including variceal bleeding<sup>1920</sup> and isolated spider nevi of the GI tract.<sup>21</sup> Varices are portosystemic collaterals that evolved from dilated embryonic vascular channels.<sup>22</sup> When visible at conventional endoscopy, rectal varices are characterized by dilated and tortuous submucosal veins, 3-6 mm in diameter. The deeper they lie in the submucosa, the less visible they are.<sup>23</sup> Endoscopic ultrasound compares more favorably than conventional endoscopy in detecting rectal varices.<sup>23</sup>

Spider nevi lesions are characterized by a central arteriole with small tortuous vessels radiating from it.<sup>24</sup> Mucosal erosion over the central arteriole results in arterial spurting. In patients with CLD, this has been theorized as sharing a common pathogenesis with Dieulafoy's lesion.<sup>21</sup> Spider nevi lesions are visible endoscopically as spider like lesions which blanch on pressure.<sup>21</sup> Differentiation of spider nevi from Dieulafoy's lesions would be best approached with biopsy or endoscopic ultrasound.<sup>17</sup>

In summary, we have presented a rare case of acute massive GI bleeding from a rectal Dieulafoy like lesion in a critically ill patient with chronic liver disease. Bleeding was successfully controlled with injection of epinephrine and endoclip application. A possible association exists between chronic liver disease and rectal Dieulafoy's lesion.

## References

1. Chaer RA, Helton WS. Dieulafoy's disease. *Journal of American College of Surgeons* 2003;196(2):290-296
2. Gallard MT. Aneurysme miliaries de l'estomach, donnant lieu a des hematemeses mortelles. *Bull Soc Med Hop Paris*

1884;1:84-91

3. Dieulafoy G. Exulceratio simplex. L'intervention chirurgicale dans les hematemeses foudroyantes consecutives a l'exulceration simple de l'estomac. Bull Acad Med 1898;9:49-84
4. Katsinelos P, Paroutoglou G, Mimidis K, et al. Endoscopic treatment and follow-up of gastrointestinal Dieulafoy's lesions. World J Gastroenterol 2005;11(38):6022-6026
5. Juler GL, Labitzke HG, Lamb R, Allen R. The pathogenesis of Dieulafoy's gastric erosion. Am J Gastroenterol 1984;79:195
6. Baettig B, Haecki W, Lammer F, Jost R. Dieulafoy's disease: endoscopic treatment and follow up. Gut 1993;34(10):1418-1421
7. Norton ID, Petersen BT, Sorbi D, et al. Gastrointestinal Endoscopy 1999;50(6):762-767
8. Franko E, Chardavoyne R, Wise L. Massive rectal bleeding from a Dieulafoy's type ulcer of the rectum. Am J Gastroenterol 1991;86(10) 1545-1547
9. Renz Em. Dieulafoy lesion as a cause of massive gastrointestinal bleeding. South Dakota J Med 1997;50(7):225-227
10. Abdulian JD, Santoro MK, Yang KC, et al. Dieulafoy like lesion of the rectum presenting with exsanguinating hemorrhage: successful endoscopic sclerotherapy. Am J Gastroenterol 1993;88:1939-1941
11. Voth D. Quoted in: Chaer RA, Helton WS. Dieulafoy's disease. Journal of American College of Surgeons 2003;196(2):290-296
12. Voth D. Quoted in: Azimuddin K, Stasik JJ, Rosen L. et al. Dieulafoy's lesion of the anal canal: a new clinical entity- report of 2 cases. Dis. Colon Rectum 2000;43:423-426
13. Azimuddin K, Stasik JJ, Rosen L. et al. Dieulafoy's lesion of the anal canal: a new clinical entity- report of 2 cases. Dis. Colon Rectum 2000;43:423-426
14. Barbier P, Luder P, Trilleer J, et al. Colonic hemorrhage from a solitary minute ulcer. Report of three cases. Gastroenterology 1985;88:1065-1068
15. Ma CK, Padda H, Pace EH, Szilagyi E. Submucosal arterial malformation of the colon with massive hemorrhage: report of a case. Dis Colon Rectum 1989;32:149-152
16. Alis H, Oner OZ, Kalayci MU, et al. Is endoscopic band ligation superior to injection therapy for Dieulafoy lesion? Surg Endosc 2009 [Epub ahead of print]
17. Akhras J, Patel P, Tobi M. Dieulafoy's lesion-like bleeding: an underrecognized cause of upper gastrointestinal hemorrhage in patients with advanced liver disease. Dig Dis Sci 2007;52(3):722-726
18. Apiratpracha W, Ho JK, Powell JJ, Yoshida EM. Acute lower gastrointestinal bleeding from a dieulafoy lesion proximal to the anorectal junction post-orthotopic liver transplant. World J Gastroenterol 2006;12(46):7547-7548
19. Azar C, Khalifeh M, Al-Kutoubi MA, Sharara AI. Recurrent massive hemorrhage from an endoscopically inevident isolated rectal varix. Digestive and Liver Disease 2006;38:851-853
20. Batoon SB, Zoneraich S. Misdiagnosed anorectal varices resulting in a fatal event. American Journal of Gastroenterology 1999;94(10):3076-3077
21. Madhira MS, Tobi M. Isolated Gastrointestinal Spider Nevi: Potential significance. The American Journal of Gastroenterology 2000;95(10):3009-3010
22. Polio J, Groszmann RJ. Hemodynamic factors involved in the development and rupture of esophageal varices: a pathophysiologic approach to treatment. Semin Liver Dis 1986;6:318-331
23. Kobayashi H. Evaluation of rectal varices by endoscopic ultrasonography in patients with portal hypertension. Diagn Ther Endosc. 2001;7(3-4):165-174
24. Khasnis A, Gokula RM. Spider nevus. J Postgrad Med.2002;48(4):307-309

**Author Information**

**Anthony A. Aghenta, MD**

Department of Medicine, Unity Health System, Rochester, New York.

**Surinder Deygun, MD**

Department of Medicine, Unity Health System, Rochester, New York.

**Tarun Kothari, MD, FACP, FACP**

Department of Medicine, Unity Health System, Rochester, New York.