Early Versus Late Weight Bearing In Tibiotalocalcaneal Arthrodesis

M Alttahir, H Al-Ramadani, A Hatfield

Citation

M Alttahir, H Al-Ramadani, A Hatfield. *Early Versus Late Weight Bearing In Tibiotalocalcaneal Arthrodesis*. The Internet Journal of Orthopedic Surgery. 2018 Volume 26 Number 1.

DOI: 10.5580/IJOS.52830

Abstract

Background: The ability to mobilize without assistance is integral to maintaining independence. Patients treated with tibio-talo-calcaneal arthrodesis are often kept non-weightbearing post-operatively. Our hypothesis is that a dynamically locked hindfoot arthrodesis nail and immediate weight-bearing does not compromise union rates or time to union.

Methods: All patients who underwent hindfoot fusion nails from 2009-2017 treated with 2 different intramedullary nails (23 static in 20 patients vs 11 dynamic locking in 11 patients) were retrospectively reviewed. Post-operative radiographs were analyzed for union and time to union, and post-operative notes were reviewed for complications and revision surgery.

Results: 11 patients with a dynamically locked hindfoot nail were allowed to commence full weight-bearing from day 1 post-operatively, whereas 20 patients (23 nails) were treated with a statically locked nail and kept non-weightbearing for 12 weeks. Indications for surgery were grouped into: arthritis, inability to maintain fracture position, and neuro-muscular pathology. 90% of patients in the early weightbearing group progressed uneventfully to union and did not require any further surgery, compared with 83% in the non-weightbearing group.

Conclusion: Primary ankle and subtalar arthritis has a significant impact on weight-bearing. We believe that the use of a dynamically locked hindfoot arthrodesis nail allows immediate and simple mobilization post-operatively in a patient population who is unable to sustain non-weightbearing. This minimizes complications, does not compromise the end goal of union, and potentially reduces hospital stay.

INTRODUCTION

The ability to mobilize without assistance is integral to maintaining autonomy and independence, particularly in the elderly, and allows patients to remain within their community and home environment.1

Any foot and ankle pathology has the potential to significantly compromise this ability. The aim of treatment is to provide patients with a stable, plantigrade, pain-free foot, with minimal period of bed rest and early weightbearing.2 When the pathology is centered on the ankle joint, traditionally the majority of surgical solutions have required an extensive period of non-weight-bearing post-operatively.3-5

This often has a follow-on effect of increasing strain on other joints (shoulders and contra-lateral lower limb), or if mobilizing is not possible, extended periods of either bed rest or hospital admission. This, in turn, increases length of stay, increases the likelihood of complications and removes patients from their normal environment. These factors are compounded by the psychological impact of loss of independence, feelings of isolation and many more.6, 7

The fundamental principles of a successful arthrodesis are compression of broad cancellous surfaces with rigid fixation in a functional position. Patients with painful arthritis of both the ankle and subtalar joints or with severe deformities pose a challenging management dilemma from a fixation point of view. A tibio-talo-calcaneal arthrodesis, using an intramedullary nail, addresses both joints concomitantly by offering a loading sharing device for compression across the two joints with a biomechanically stiff construct that maintains alignment of the hindfoot during union.8, 9

It is well documented that the stability of the fixation

method is often the primary determining factor in obtaining a stable arthrodesis.10 It has also been biomechanically demonstrated that compressed intramedullary nails are significantly superior, in terms of primary stiffness, to uncompressed intramedullary nails.11 It remains unknown, though, if early weightbearing on a dynamized, compressing hindfoot nail compromises the stability of hindfoot nail fixation and alters union rates and time to achieve that union.

The senior author has transitioned from using a statically locked hindfoot nail (fusing the ankle and subtalar joints), with twelve weeks non-weight bearing, to using a dynamic locking, compressing nail and allowing patients to weight bear as tolerated (WBAT) from day 1 to address the above concerns.

The purpose of this study was to determine whether immediate postoperative weight bearing (if a dynamically locked hindfoot nail was used) affected time to union compared to delayed weightbearing in a statically locked nail.

Table 1

Indications for arthrodesis

Statically locked nail: 20 patients (23 nails)

- 11 Primary osteoarthritis
- 2 Rheumatoid arthritis with secondary OA
- 2 Loss of fracture fixation and progressive deformity
- 1 PTTD and progressive valgus deformity
- 1 Ankle fusion non-union
- 6 Neuromuscular (all with fixed varus)
  - 4 CMT
  - 1 Old sciatic nerve palsy
  - 1 Rapid joint destruction after sepsis in neuropathic joint

Dynamically locked nail: 11 patients (11 nails)

- 7 Primary Osteoarthritis
- 1 Rheumatoid arthritis
- 1 Loss of fracture fixation
- 1 PTTD/valgus ankle
- 1 Previous ankle non-union

MATERIAL AND METHODS

All patients treated with a retrograde hindfoot nail under the care of the senior author were identified and retrospectively reviewed. The dates of surgery ranged from 2009 to 2017. The case notes, operative notes, and pre-operative and post-operative radiographs were reviewed for all patients. Pre-operative reasons for surgery, demographic data and relevant comorbidities, and post-operative complication data were recorded. Post-operative radiographs were assessed for union defined by bony bridging across 3 out of 4 cortices on anteroposterior and lateral views.

The indications for fusion was largely grouped into 3 main areas:

Primary osteoarthritis
Deformity due to ankle fracture and inability to maintain joint congruity and stability as the fracture healed

Deformity due initially to soft tissue pathology with secondary rigid deformity (hereditary motor and sensory neuropathy (HMSN) and posterior tibial tendon dysfunction (PTTD))

The senior author used a statically locked nail from 2009 to 2016 and then changed to a dynamically locked nail in 2016 to 17.

A statically locked nail (Synthes Hindfoot Nail, West Chester, PA, USA) was used exclusively for the first 20 patients (23 nails), and then a dynamically locked nail (Integra Panta Nail, Saint Priest, France) was used for the next 11 patients (Figure 1 and 2). This dynamically locked nail allows for compression of up to 12mm during the surgery, and also has the ability for 2 dynamically locked screws at the proximal part of the nail. All patients with the Panta Nail were allowed to weight bear-as-tolerated (WBAT) from day 1 post-operatively. Patients with the statically locked nail were kept non-weightbearing for 12 weeks in a cast, then weightbearing as tolerated in a walking boot until evidence of radiographic union.

Table 2

Complications

Statically locked nail: 20 patients (23 nails)

- 1 Non-union
- 3 Delayed unions
  - 2 Required removal of static locking screw to facilitate union

Dynamically locked nail: 11 patients (11 nails)

- 1 Non-union
- 1 Delayed union
  - 1 Removal of locking screw to facilitate union
- 2 Proximal locking screw stress reaction
  - 2 Resolved / progressed to union

The only outcome measure we reviewed for this initial report was time to radiographic union. Every patient was reviewed post-operatively at 2 weeks, 6 weeks, 12 weeks,

and then at 6 weekly intervals afterwards if union was delayed. Non-union was defined as an arthrodesis that did not unite within 12 months. Delayed union was defined as incomplete fusion with failure of radiographic progression on 3 consecutive radiographs within 6 months.

Statistical analysis was performed in Microsoft ExcelTM (Version 15.0.4963.1000, Microsoft, Redmond, WA, USA) using unpaired t-tests to compare union rates.

Figure 1

Preoperative radiographs of patient with severe primary degenerative osteoarthritis

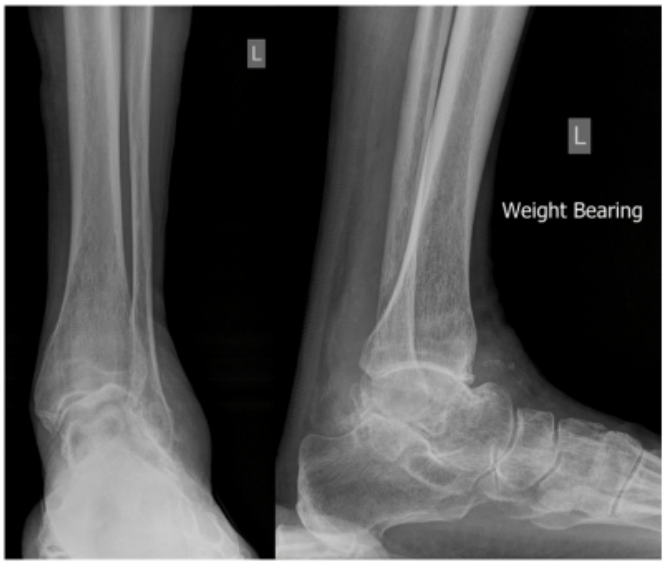

Figure 2

Post-operative radiographs with a dynamically locked nail and bony union

RESULTS

34 ankles in 31 patients (3 bilateral) were assessed, with 23 statically locked nails, and 11 dynamically locked nails. The most common pathology in each group was osteoarthritis (Table 1).

In the statically locked hindfoot nail group, ages ranged from 33-82 with an average of 60.7. Average time to union was 17.7 weeks (range: 12-52 weeks). There was 1 non-union and 3 delayed unions (Table 2). Two of the delayed unions required removal of a static locking screw (thus dynamizing the fusion and allowing progression to union). The other patient elected to continue with non-operative observation, and was lost to follow-up. One patient required an early revision for a rotational deformity.

The non-union rate was 4%, and the delayed union rate was 13% (if we assume the patient lost to follow-up progressed to union eventually). Thus, there was an overall uncomplicated union rate of 83%.

The average age in the dynamically locked group was 64 years of age (43-76). 90% of patients (10/11) progressed uneventfully to union in 14 weeks (range: 12-20 weeks), with one non-union and one delayed union (Table 2), which was not statistically different to the statically locked group ($p = 0.6$). The patient with delayed union required removal of a locking screw to facilitate further compression, and united after 36 weeks. 2 patients did complain of pain at the proximal locking screw site, and there was some increased new bone formation evident on x-ray, however both progressed uneventfully to union and the pain settled with conservative management.

The overall intervention rate post-operatively was 17% in the statically locked nail group, versus 9% in the dynamically locked group.

DISCUSSION

Allowing an elderly person to remain weight-bearing and mobile results in many positive health outcomes.1 It minimizes muscle wasting and balance loss. It reduces the likelihood of pressure areas or chest infections. It is also more likely to enable the patient to return home and achieve independence which is both physically and mentally beneficial.

A significant concern for many patients faced with the prospect of lower limb surgery is restricted mobility. This can often lead to mental stress and emotional distress as they

face the possibility of either being housebound, wheelchair bound or remaining in care for the length of time of recovery.12 Hence early weightbearing in the setting of hindfoot fusion surgery will address the above-mentioned concerns.

Many foot and ankle patients present initially with combined ankle and subtalar pathology, requiring both joints to be addressed at the same time.13 Tibio-talo-calcaneal arthrodesis addresses both in non-braceable neuropathic hindfoot deformities, disabling fixed deformities, failed ankle arthrodesis, failed total ankle arthroplasty, talar osteonecrosis, and severe ankle and subtalar arthritis.10 However, a period of post-operative non-weight-bearing, at least for 6 weeks and often until union, is commonplace in the setting of hindfoot nail surgery.

The use of a dynamized nail in the setting of hindfoot surgery is an attempt to encourage union in arthrodesis sites that often have high non-union rates. The management of a transverse tibial or femoral shaft fracture with the use of a dynamically locked nail to encourage healing is well recognized.14,15,16,17 The “dynamization” of a statically locked nail and the commencement of weight-bearing, has been traditionally used as an attempt to encourage union in a slow-to-heal fracture. Likewise, hindfoot intramedullary nails with compression have been biomechanically shown by Muckley et al to produce large contact surfaces and great primary stiffness.11 Hence, the early weightbearing in the compressed dynamized nail arm of our study utilizes these concepts in an attempt to accelerate union.

Numerous studies have been published to evaluate clinical, functional and radiologic outcomes in patients undergoing tibio-talo-calcaneal arthrodesis using a locked retrograde intramedullary nail, however with the majority of studies managing patients with a period of non-weightbearing post-operatively. In 1995, Moore et al presented data on 19 patients undergoing hindfoot nailing with a union rate of 76%, however, data on weightbearing status post-operatively was not available.18 Hammett et al presented 49 patients with 52 nails non-weightbearing for 6 weeks then partial weightbearing until union, with a union rate of 88.4% (average 17 weeks).19 Rammelt et al had a union rate of 84% in 38 patients, with 18 managing partial weightbearing initially, 2 patients up to 60 pounds weightbearing and 2 patients early weightbearing, the rest non-weightbearing post-operatively.3 In a randomized trial, Mendicino et al presented 20 feet in 19 patients who were kept non-weightbearing until union, with a rate of 95% (average 17 weeks).5 Weight-bearing data was not reported in Caixeta et al who had a union rate of 82% (average 16 weeks) in 29 patients.20 Chou et al published results in 55 patients (56 ankles) who were kept non-weight-bearing for 3 months, followed by partial weight-bearing until union, with 86% union (average of 19 weeks).4 Niinimäki et al kept 34 patients non-weight-bearing for 6-8 weeks, achieving a union rate of 76% (average 16 weeks).21 Richter et al utilised a compressing hindfoot nail and published a 100% union rate in 60 patients, 48 of whom had commenced weight-bearing at 6 weeks post-operatively (52 patients WBAT by 9 weeks, 66 patients by 12 weeks) with 6 patients requiring dynamization at 12 weeks.22 In a Pelton et al paper presenting on a dynamically locked intramedullary nail, the union rate was 88% (mean 15 weeks) in 33 patients whom had been non-weight-bearing for an initial 6 to 8 weeks.23 Budnar et al reported a union rate of 89% (mean 14 weeks) in 42 patients undergoing 45 tibio-talo-calcaneal arthrodesis, immobilized in a below-knee cast for 3 months, who were kept non-weight-bearing for 2 weeks, partially weight-bearing for 6 weeks and subsequently fully weight-bearing.24 In a retrospective study of 58 patients (59 compressing hindfoot nails cases), Thomas et al achieved a union rate of 93% (mean 16.7 weeks) immobilized in a non-weight-bearing cast for 6 weeks, followed by 6 weeks in an air cast boot progressing to full weightbearing as tolerated.25 In a study of 30 patients managed with a tibio-talo-calcaneal arthrodesis nail and 2 months in a non-weight-bearing cast, Gross et al reported a union rate of 86% for the ankle joint and 74% for the subtalar joint.26 Taylor et al published a retrospective review of 198 patients showing a tibiotalar union rate of 57.9% and subtalar union rate of 56.5% in 145 patients receiving non-compressing hindfoot nails, compared with a tibiotalar union rate of 83% and subtalar union rate of 75.5% in 53 compressing hindfoot nails.13 Finally, Brodsky et al published on the compressing intramedullary Integra Panta Nail reporting a union rate of 96.6% in the tibiotalar joint and 100% in the subtalar joint of 29 patients (30 compressing hindfoot nails), however all patients were also kept non-weight-bearing for 8 weeks, followed by a walking cast for 4 weeks.27

Our study utilized the design of a dynamically locked, compressing hindfoot intramedullary ‘second generation nail’, a design which when used with its nail-mounted compression device, maintained significantly more compression at the arthrodesis site.28 We presented a comparative study between a statically locked nail, and dynamically locked, compressing nail with results of union

rate and time to union comparable to previously published data (83% uncomplicated union rate in static locking, 90% in dynamically locked, compressed nail). Our reoperation rates (17% in statically locked IM nail; 9% in dynamically locked, compressed IM nail) were comparable to published results in a systematic review of tibio-talo-calcaneal arthrodesis with intramedullary nailing, which showed a re-operation rate of 22% in 631 patients.29 Our data demonstrated no significant adverse difference in immediate post-operative weight-bearing-as-tolerated protocol in a 'second generation nail', demonstrating that early weight-bearing with the use of a dynamically locked hindfoot nail did not compromise time to union or increase post-operative complications.

In the last 50 years, we have seen significant changes in the health of the general population. Our population is not only aging, but is becoming more obese and more sedentary. These factors all contribute to difficulty non-weight-bearing after injury or surgery. As our population ages, the health care system is constrained to treat increasing numbers of patients with finite resources. The cost of length of stay impacts significantly on this. Our aim is to show that early weight-bearing, and the likely reduction in hospital stay, does not adversely impact the results of tibio-talo-calcaneal arthrodesis surgery.

Several limitations are present in our study, the design being a consecutive retrospective review of a non-randomized patient cohort, and the small number of patients and as such, this study is potentially poorly powered to demonstrate a statistically significant difference in union rates and time to union. However, despite a small cohort, the dynamically locked, early weightbearing group demonstrated no increase in complication rate or time to union, and as such, we conclude that it provides a safe alternative to prolonged periods of non-weightbearing in statically locked hindfoot nails. It provides the scope for further studies to commence early weightbearing which should alleviate the negative consequences of prolonged non-weightbearing in often elderly patients, as well as the cost burden of lengthy hospitalization and community services care.

We plan to undertake a further prospective study and include the following: time to union, length of hospital stay, wear and pain generated in other weight-bearing joints, and pre-operative and post-operative AOFAS scores.

References

1. Georgiannos D, Lampridis V, Bisbinas I. Fragility fractures of the ankle in the elderly: Open reduction and internal fixation versus tibio-talo-calcaneal nailing: Short-term results of a prospective randomized-controlled study. Injury 2017; 48(2):519-24
2. Stone KH, Helal B. A method of ankle stabilization. Clinical orthopaedics and related research 1991; (268):102
3. Rammelt S, Pyrc J, Ågren P-H, et al. Tibiotalocalcaneal Fusion Using the Hindfoot Arthrodesis Nail. Foot & Ankle International 2013; 34(9):1245-55
4. Chou LB, Mann RA, Yaszay B, et al. Tibiotalocalcaneal Arthrodesis. Foot & Ankle International 2000; 21(10):804-8
5. Mendicino RW, Catanzariti AR, Saltrick KR, et al. Tibiotalocalcaneal arthrodesis with retrograde intramedullary nailing. The Journal of Foot and Ankle Surgery 2004; 43(2):82-6
6. Williams LJ, Berk M, Henry MJ, et al. Depression following fracture in women: a study of age-matched cohorts. BMJ Open 2014; 4(2):e004226
7. Bruggemann L, Nixon RDV, Cavenett T. Predicting Acute Anxiety and Depression following Hip Fracture. Journal of Behavioral Medicine 2007; 30(2):97-105
8. Asomugha EU, Den Hartog BD, Junko JT, et al. Tibiotalocalcaneal Fusion for Severe Deformity and Bone Loss. Journal of the American Academy of Orthopaedic Surgeons 2016; 24(3):125-34
9. Berend ME, Glisson RR, Nunley JA. A Biomechanical Comparison of Intramedullary Nail and Crossed Lag Screw Fixation for Tibiotalocalcaneal Arthrodesis. Foot & Ankle International 1997; 18(10):639-43
10. Bennett GL, Cameron B, Njus G, et al. Tibiotalocalcaneal Arthrodesis: A Biomechanical Assessment of Stability. Foot & Ankle International 2005; 26(7):530-6
11. Mückley T, Eichorn S, Hoffmeier K, et al. Biomechanical Evaluation of Primary Stiffness of Tibiotalocalcaneal Fusion with Intramedullary Nails. Foot & Ankle International 2007; 28(2):224-31
12. Fenton P, Bali N, Matheshwari R, et al. Complications of tibio-talar-calcaneal fusion using intramedullary nails. Foot and ankle surgery : official journal of the European Society of Foot and Ankle Surgeons 2014; 20(4):268-71
13. Taylor J, Lucas DE, Riley A, et al. Tibiotalocalcaneal Arthrodesis Nails: A Comparison of Nails With and Without Internal Compression. Foot & Ankle International 2016; 37(3):294-9
14. Richardson JB, Gardner TN, Hardy JR, et al. Dynamisation of tibial fractures. The Journal of bone and joint surgery British volume 1995; 77(3):412
15. Hernández-Vaquero D, Suárez-Vázquez A, Iglesias-Fernández S, et al. Dynamisation and early weight-bearing in tibial reamed intramedullary nailing: its safety and effect on fracture union. Injury 2012; 43 Suppl 2:S63
16. Papakostidis C, Psyllakis I, Vardakas D, et al. Femoral-shaft fractures and nonunions treated with intramedullary nails: The role of dynamisation. Injury 2011; 42(11):1353-61
17. Huang K-C, Tong K-M, Lin Y-M, et al. Evaluation of methods and timing in nail dynamisation for treating delayed healing femoral shaft fractures. Injury 2012; 43(10):1747
18. Moore TJ, Prince R, Pochatko D, et al. Retrograde Intramedullary Nailing for Ankle Arthrodesis. Foot & Ankle International 1995; 16(7):433-6
19. Hammett R, Hepple S, Forster B, et al. Tibiotalocalcaneal (Hindfoot) Arthrodesis by Retrograde Intramedullary Nailing Using a Curved Locking Nail. The Results of 52 Procedures. Foot & Ankle International 2005; 26(10):810-5
20. Caixeta TB, Júnior MOC, de Castro RV, et al. Tibiotalocalcaneal arthrodesis with retrograde intramedullary nailing: 29 patients' clinical and functional

evaluation()(). Revista Brasileira de Ortopedia 2014; 49(1):56-61
21. Niinimäki TT, Klemola T-M, Leppilahti JI. Tibiotalocalcaneal Arthrodesis with a Compressive Retrograde Intramedullary Nail: A Report of 34 Consecutive Patients. Foot & Ankle International 2007; 28(4):431-4
22. Richter M, Zech S. Tibiotalocalcaneal arthrodesis with a triple-bend intramedullary nail (A3)—2-year follow-up in 60 patients. Foot and Ankle Surgery 2016; 22(2):131-8
23. Pelton K, Hofer JK, Thordarson DB. Tibiotalocalcaneal Arthrodesis Using a Dynamically Locked Retrograde Intramedullary Nail. Foot & Ankle International 2006; 27(10):759-63
24. Budnar VM, Hepple S, Harries WG, et al. Tibiotalocalcaneal Arthrodesis With a Curved, Interlocking, Intramedullary Nail. Foot & Ankle International 2010; 31(12):1085-92
25. Thomas AE, Guyver PM, Taylor JM, et al. Tibiotalocalcaneal arthrodesis with a compressive retrograde nail: A retrospective study of 59 nails. Foot and ankle surgery : official journal of the European Society of Foot and Ankle Surgeons 2015; 21(3):202-5
26. Gross J-B, Belleville R, Nespola A, et al. Influencing factors of functional result and bone union in tibiotalocalcaneal arthrodesis with intramedullary locking nail: a retrospective series of 30 cases. European Journal of Orthopaedic Surgery & Traumatology 2014; 24(4):627-33
27. Brodsky JW, Verschae G, Tenenbaum S. Surgical Correction of Severe Deformity of the Ankle and Hindfoot by Arthrodesis Using a Compressing Retrograde Intramedullary Nail. Foot & Ankle International 2014; 35(4):360-7
28. Berson L, McGarvey WC, Clanton TO. Evaluation of Compression in Intramedullary Hindfoot Arthrodesis. Foot & Ankle International 2002; 23(11):992-5
29. Jehan S, Shakeel M, Bing AJF, et al. The success of tibiotalocalcaneal arthrodesis with intramedullary nailing--a systematic review of the literature. Acta orthopaedica Belgica 2011; 77(5):644

Author Information

Mustafa Alttahir
Wagga Wagga Rural Referral Hospital
Wagga Wagga, NSW, Australia

Hussain Al-Ramadani
Wagga Wagga Rural Referral Hospital
Wagga Wagga, NSW, Australia

Angela Hatfield
Riverina Orthopaedics
Wagga Wagga, NSW, Australia