Laparoscopic Cholecystectomy in Situs Inversus: Case Study and Literature Review

J A Petit, K Rajkomar

Citation

J A Petit, K Rajkomar. *Laparoscopic Cholecystectomy in Situs Inversus: Case Study and Literature Review*. The Internet Journal of Surgery. 2018 Volume 35 Number 1.

DOI: 10.5580/IJS.52903

Abstract

Background: Situs inversus is a rare condition which produces perplexities in the diagnosis and therapeutic approaches to symptomatic cholelithiasis. We present a case of laparoscopic cholecystectomy in a patient with situs inversus totalis with a focus on the technical approach to the operation. This review focuses on the issues with diagnosis, the technical difficulties and the overall safety of the operation.

Method and Results: A systematic search was conducted using Medline and Embase databases. All relevant case studies in the English literature reporting laparoscopic cholecystectomy in patients with situs inversus were included for analysis. A total of 77 of 180 articles met the inclusion criteria.

Conclusion: Symptomatic cholecystitis can be difficult to diagnose in patients with situs inversus due to variable symptoms on presentation. Laparoscopic cholecystectomy in these patients is technically more difficult however carefully placed ports allow a safe and ergonomic dissection.

INTRODUCTION:

Laparoscopic cholecystectomy (LC) has rapidly become the standard of treatment for symptomatic cholelithiasis over the last three decades since it was first reported in 1987 by Mouret[1]. This study reports a case of LC performed on a patient with situs inversus (SI) and presents a systematic review of the literature on this subject. The aim is to characterise the difficulties associated with initial diagnosis, describe the relative anatomy, compare the operative techniques used and assess the safety of the procedure in this specific population. While there are notable difficulties in diagnosis and operative management we believe that this is a safe approach in this subset of patients.

STUDY DESIGN AND RESEARCH METHODOLOGY:

A systematic search was conducted using Medline and Embase databases. The terms ‘cholecystectomy’, ‘laparoscopic cholecystectomy’ and ‘situs inversus’ were combined to search the databases. Articles were considered eligible if they were related to cases of LC performed in patients with SI. All relevant studies in the English literature reporting LC in patients with SI were included for analysis. Abstracts and posters that remained unpublished were excluded from analysis. Reference lists from relevant articles were similarly searched for other suitable studies.

RESULTS:

The search found 180 results after removal of duplicates. A total 53 articles were not included since they were not in English and 35 results were excluded because they were limited to abstracts, conference articles and letter only. A further 33 articles were excluded since they involved procedures other than laparoscopic cholecystectomy. The remaining 59 articles met the inclusion criteria and after a complete search of the reference lists a total of 77 articles were included in analysis (Table 1). Data was gathered on the symptoms at presentation, investigations performed, operation room setup and port placements, hand used for dissection, operative time, length of post-operative stay and any post-operative complications.

Table 1a

Included studies

Author / Date	Age	Gender	Journal
Ren / 2017	36	F	J Int. Med. Res., 2017; 45(3):1261-7
Ahmed / 2016	46	F	Int. J Surg. Case Reports, 2016; 29:34-8
Ahmed / 2016	44	F	Int. J Surg. Case Reports, 2016; 29:34-8
Ahmed / 2016	33	F	Int. J Surg. Case Reports, 2016; 29:34-8
Alsabek / 2016	50	F	Int. J Surg. Case Reports, 2016; 28:124-6
Deguchi / 2015	66	M	Asian J of Endoscopic Surgery, 2015; 8(3):347-9
El-Saady / 2015	52	F	Egyptian J Surgery, 2015; 34:293-8
Dahuja / 2015	25	F	SAS J Surg, 2015; 1(3):66-8
Chalkoo / 2015	25	F	JPMS, 2015; 5(1):23-5
Phothong / 2015	39	F	BMC Surgery, 2015; 15(23):1-4
Kumar / 2015	35	F	IAIM, 2015; 2(3):193-6
Fang / 2015	39	F	J Minimal Access Surgery, 2015; 11(3):210-2
Raghuveer / 2014	55	M	J Clinical and Diagnostic Research, 2014; 8(7):3-5
Reddy / 2014	45	F	The Internet J Surgery Case Rep 3, 2014; 821-3
Moirangthem / 2015	50	F	J Med Soc, 2014; 28:60-2
Butt / 2015	42	F	J Coll Phys and Surg Pakistan, 2015; 25(Supp 1):S22-23
Rafie / 2014	72	F	CRSLS MIS, e2014.00018
Rafie / 2014	35	F	CRSLS MIS, e2014.00018
Salama / 2013	10	M	The Internet J Surgery Case Rep, 2013; 4(8):711-5
Stojcev / 2013	47	M	Polski Przeglad Chirurgiczny, 2013; 85(3):141-4
Zhang / 2013	50	F	Chin Med Sci J, 2013; 28(4):245-7
Khiangte / 2013	65	M	J Minimal Access Surgery, 2013; 9(4):180-2
Arya / 2013	35	F	The Internet J Surgery Case Rep, 2013; 727-730
Ali / 2013	43	F	BMJ Case reports, 2013; 1-4
Campos Martins / 2012	59	F	J Medical Case Reports, 2012; 6(96):1-3
Demiryilmaz /2012	55	F	Iranian Red Cres Med J, 2012; 14(12):826-8
Demiryilmaz /2012	51	F	Iranian Red Cres Med J, 2012; 14(12):826-8
Bozkurt / 2012	49	F	JSTCR, 2012; 4(2):129-31
Lochman / 2012	75	F	Videosurgery Miniinv, 2012; 7(3):216-9
Pahwa / 2012	46	F	BMJ Case reports, 2012; 1-3
Iusco / 2012	52	F	G Chir, 2012; 33:10-13
Topuz / 2011	50	M	Pak J Med Sci, 2011; 27(4):929-31
Borgaonkar / 2011	49	F	J Minimal Access Surgery, 2011; 7(4):242-5
Uludag / 2011	49	M	JSLS, 2011; 5:239-43
Ozsoy / 2011	65	F	BMJ Case reports, 2011; 1-4
Han / 2011	45	M	Surg Today, 2011; 41:877-80
Arif / 2010	42	F	WJOLS, 2010; 3(2):63-5
Ozben / 2010	47	F	Firat Tip Dergisi, 2010; 15(1):67-9
Jindal / 2010	55	F	J Laparoendoscopic & Adv Surg Tech, 2010; 20(3):241-3
Jindal / 2010	26	F	J Laparoendoscopic & Adv Surg Tech, 2010; 20(3):241-3
Patle / 2010	36	F	Indian J Surg, 2010; 72(5):391-4
Patle / 2010	43	F	Indian J Surg, 2010; 72(5):391-4
Patle / 2010	27	F	Indian J Surg, 2010; 72(5):391-4

Table 1b

Included studies (Continued)

Patle / 2010	48	M	Indian J Surg, 2010; 72(5):391-4
Patle / 2010	59	F	Indian J Surg, 2010; 72(5):391-4
Patle / 2010	33	F	Indian J Surg, 2010; 72(5):391-4
Velimezis / 2009	66	F	The Internet J Surgery, 2009; 26(1):1-5
Eisenberg / 2009	61	M	Int Med Case Rep, 2009; 2:27-9
Simmons / 2009	18	F	The American Surgeon, 2009; 75(4):353-4
Taskin / 2009	20	F	Obes Surg, 2009; 19:1724-6
Masood / 2009	42	F	J Ayub Med Col Abbottabad, 2009; 21(1):162-4
Ghosh / 2008	27	F	The Internet J Surgery, 2008; 19(2):1-3
Naikoo / 2008	37	F	Internet J of Medical Update, 2008; 3(1):50-2
Pavlides / 2008	34	F	Diagnostic and Therapeutic Endoscopy, 2008;
Fernandes / 2008	43	F	Case Rep in Gastroenterology, 2008; 2:170-4
Hamdi / 2008	41	M	Saudi J Gastroenterology, 2008; 14(1):31-2
Kumar / 2007	57	F	An R Coll Surg Engl, 2007; 89:1-3
Shah / 2006	60	F	J Minimal Access Surgery, 2006; 2(1):27-8
Kirshtein / 2006	51	F	Surg Laparosc Endosc Percutan Tech, 2006; 16:169-71
Aydin / 2006	35	M	World J Gastroenterology, 2006; 12(47):7717-9
Machado / 2006	65	F	JSLS, 2006; 10:386-91
Kamitani / 2005	76	M	World J Gastroenterology, 2005; 11(33):5232-4
Pitiakoudis / 2005	47	F	Acta Chir Belg, 2005; 105:114-7
McKay / 2005	32	F	BMC Surg, 2005; 5(5):1-2
Docimo / 2004	41	F	Hepatogastroenterology, 2004; 51(58):958-60
Kang / 2004	64	F	J Laparoendoscopic & Adv Surg Tech, 2001; 14(2):103-6
Jesudason / 2004	69	M	Indian J of Gastroenterology, 2004; 23:79
Oms / 2003	70	F	Surg Endoscopy, 2003; 17:1859-61
Oms / 2003	65	M	Surg Endoscopy, 2003; 17:1859-61
Polychronidis	68	M	Surg Endoscopy, 2002; 16(7):1110
Honda / 2002	49	M	Digestive Endoscopy, 2002; 14:171-4
Franklin / 2001	25	F	Asociation Mex Cir Endoscopica, 2001; 2(3):150-3
Al-Jumaily / 2001	46	F	J Laparoendoscopic & Adv Surg Tech, 2001; 11(4):229-31
Yaghan / 2001	48	F	J Laparoendoscopic & Adv Surg Tech, 2001; 11(4):233-7
Yaghan / 2001	38	F	J Laparoendoscopic & Adv Surg Tech, 2001; 11(4):233-7
Donthi / 2001	43	F	JSLS, 2001; 5(1):53-6
Donthi / 2001	39	F	JSLS, 2001; 5(1):53-6
Nursal / 2001	42	F	J Laparoendoscopic & Adv Surg Tech, 2001; 11(4):239-41
Komborozos / 2000	61	M	Annals of Gastroenterology, 2000; 13(4):323-4
Djohan / 2000	20	F	JSLS, 2000; 4:251-4
Demetriades / 1999	61	F	Digestive Surgery, 1999; 16(6):519-21
Demetriades / 1999	37	M	Digestive Surgery, 1999; 16(6):519-21
Habib / 1998	45	F	Annals of Saudi Medicine, 1998; 18(3):247-8
Malatani / 1996	25	F	Annals of Saudi Medicine, 1996; 16(4):458-9
McDermot / 1994	66	M	Surg Endoscopy, 1994; 8:1227-9
Huang / 1992	36	M	Endoscopy, 1992; 24(9):802-3
Drover / 1992	29	F	Can J Surg, 1992; 35(1):65-6
Goh / 1992	62	M	Endoscopy, 1992; 24(9):799-800
Lipschutz / 1992	80	M	The American J of Gastroenterology, 1992; 87(2):218-20
Takei / 1992	51	F	J Laparoendoscopic Surg, 1992; 2(4):171-6
Campos / 1991	39	F	J Laparoendoscopic Surg, 1991; 1(2):123-6

CASE PRESENTATION:

A 33-year-old female presented complaining of epigastric pain with no other associated complications. On investigation she had normal liver function tests and an ultrasound confirmed uncomplicated symptomatic cholelithiasis in the setting of SI. An elective laparoscopic cholecystectomy was organised.

For the procedure, the patient was placed in the Lloyd-Davis position. Optical port entry was made via the right upper quadrant (RUQ). Two 5mm ports were placed in the sub-xiphoid and left anterior axillary line. Two further 12mm ports were placed, one midway between the sub-xiphoid port and umbilicus and another at the lateral border of the rectus abdominus midway between the umbilicus and left axillary 5mm port (Figure 1). A reverse Trendelenburg and left side up position was adopted. The surgeon was on the patient's right side while the assistant was placed between the patient's legs with the monitor over the patients left shoulder.

Figure 1
Intraoperative view

At laparoscopy SI was noted with the liver in the left upper quadrant (LUQ) and changes consistent with chronic cholecystitis were encountered (Figure 2). The fundus was pushed cephalad using the left sided 5mm port while Hartmann's pouch was retracted using the sub-xiphoid port. The 12mm midline port was the main dissecting port but can be interchanged with the laparoscope placed in the left 12mm port. The hepatocystic triangle was carefully dissected (Figure 3) and an intraoperative cholangiogram (IOC) performed which showed a biliary tract configuration consistent with SI. The dissection then proceeded with clipping of the hepatocystic triangle structures prior to removal of the of the gall bladder from the cystic plate (Figure 4).

Figure 2
Laparoscopic view

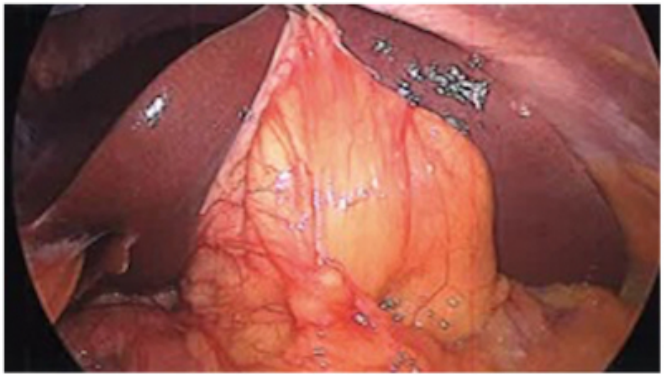

Figure 3
View of the hepatocystic triangle

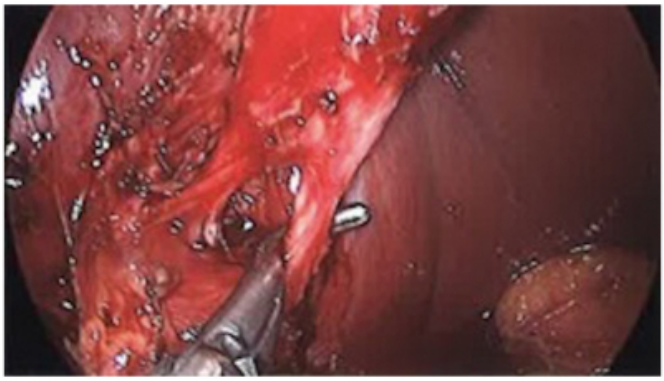

Figure 4
Intraoperative cholangiogram

The operation was completed in 100 minutes. The patient's

recovery was uneventful and she was discharged home the next day. At 6 weeks follow-up the patient had returned to work with a full recovery.

DISCUSSION:

SI is an autosomal recessive condition that has an incidence range of 0.02% to 0.005% [2]. The gene involved is located on the long arm of chromosome 14 and is known to be transmitted with incomplete penetrance [1]. This condition may involve the transposition of the abdominal viscera or the thoracic viscera; situs inversus partialis (SIP), or both; situs inversus totalis (SIT). Total transposition is known to be the more common variant and only two case reports on a patient with SIP were found [3]. The condition may also occur in isolation or may be associated with anomalies of the cardiovascular, respiratory, gastrointestinal, urological, orthopaedic and neurological systems [1]. A number of these anomalies frequently occur together with SI in Kartagener's, Ivemark's and Yoshikawa's syndromes [1].

Due to the risk of these significant co-morbidities it is important for patients with SI to have a complete work-up pre-operatively to determine the exact nature of anomalies and exclude any other undiagnosed abnormalities. This work up should, as a minimum, include routine bloods, CXR, ECG and abdominal imaging. Exactly which modality of abdominal imaging that should be performed is a matter of debate in the literature. The most commonly performed investigations among the reports in this review are abdominal ultrasound, CT, MRI or cholangiogram (Table 2). Ultrasound is the initial investigation of choice in patients with suspected cholelithiasis, cholecystitis or choledocholithiasis and this is reflected in the high use of this investigation. The main reason given for other preoperative investigations was to confirm the diagnosis of SIT or exclude other biliary anomalies.

Table 2

Frequency of investigations performed

Investigation	Ultrasound	CT	MRI	CTC	MRCP	IOC
Performed	93%	33%	7%	4%	4%	10%

CT = Computed Tomography, MRI = Magnetic Resonance Imaging, CTC = Computed Tomography Cholangiography, MRCP = Magnetic Resonance Cholangio-pancreatography

There is no evidence to suggest that there is an increased incidence of symptomatic cholelithiasis in SI [1,4]. Similarly, patients with SIT most commonly have normal but reversed extrahepatic biliary, venous and arterial anatomy [4,5]. Although there is an association between SIP and the polysplenia-biliary atresia syndrome, it is only found in 7% of patients with biliary atresia [6]. This syndrome features biliary atresia, multiple splenunculi, vena cava or portal vein anomalies, malrotation or situs inversus abdominus, visceral hypoplasia and cardiac anomalies [6,7]. Regardless of this it is commonly suggested that either pre-operative cholangiography or IOC would be of benefit in confirming the biliary anatomy in patients with SI. However, cholangiography of any kind (i.e. IOC, MRCP and CTC) was performed in only 14 patients (15%) of all cases reviewed. Although the issue of selective versus routine IOC continues to be controversial we advocate the routine use of IOC in all cases of LC for multiple reasons. IOC can provide a map of the biliary anatomy, identify biliary pathology and exclude iatrogenic injuries. Due to the increased difficulty of the operation on patients with SIT we believe that IOC should be used routinely.

It is recognised that it can be difficult when trying to diagnose patients presenting with abdominal symptoms who are not known to have SI. This can lead to undesirable delays in diagnosis and subsequent definitive therapy. However, even if the diagnosis of SI has already been made this problem still exists since the location of the pain is highly variable. Rao noted in a review of 26 cases of cholelithiasis that the majority of patients present with either LUQ pain or epigastric and LUQ pain combined. However, around 30% of patients present with only pain in the epigastrium [8]. Additionally, it was noted that 10% of patients presented with RUQ pain [8]. The data from this review suggests that the number of patients presenting with RUQ pain is actually closer to 5% (Table 3). Abnormal locations of pain in patients with SI has also been found with appendicitis. Akbulut found in a review of 95 cases that almost 15% of patients with left sided appendicitis presented with right iliac fossa pain [9]. This feature of pain distribution in patients with SIT was noted as far back as the 1940's by King and Cholst [10]. It is hypothesized that this is a consequence of the peripheral nervous system developing independent of the transposed viscera.

Table 3

Site of pain on presentation

Site	LUQ	Epigastric	LUQ & Epigastric	RUQ	Other	Unknown
Percentage	43%	27%	16%	5%	3%	4%

LUQ = Left upper quadrant, RUQ = Right upper quadrant

The mirror image anatomy in SI raises issues with the

technical aspects of the operation. The majority of surgeons are right-handed and this can cause difficulties during dissection since the mirror image port site placement favours a left-handed dissection technique. In the cases reviewed the right hand was used for dissection three times more than the left hand, however the dissection hand was not documented in 30% of cases. The most commonly used setup is with the surgeon on the patient's right side, the video monitor over the left shoulder and the operative port sites in a mirror image of the conventional placement. This arrangement is used in over 60% of the cases described. However, this forces the surgeon to either perform dissection with the left hand through the epigastric port, cross hands to allow for right handed dissection through the epigastric port or use the mid-clavicular port for right handed dissection. Crossing hands is not ergonomic and may cause tiring of the surgeon's arms and subsequent reduction in dexterity and performance. Similarly, there are issues with use of the mid-clavicular port for dissection of Calot's triangle since this causes the tip of the dissector to lose its perpendicular angle to the plane of dissection.

To overcome this issue, we used a unique port placement in this case. The midline placement of the surgeon's ports allows for retraction of the infundibulum with the left hand through the sub-xiphisternal port while the right hand is used for dissection through the supra-umbilical port. The midline port placement allows the use of the surgeon's right hand for operative dissection. This placement maintains a good angle for dissection by eradicating the narrow angle that is encountered through the mid-clavicular port. Furthermore, in this case the laparoscope and dissector could be used interchangeably through either of the 12mm ports with ease. A very similar port placement was used by Aydin, however the camera was placed in the midline in a sub-umbilical position [11]. This position does not allow for interchangeability since it puts the dissector at the extreme of its range and reduces the precision of movements. We also felt that movement of the camera to the left of the umbilicus reduced the incidence of collision with the instrument placed through the supra-umbilical port. In this arrangement, there is good triangulation of the operative field, adequate angles for dissection with the preferred hand and ample space between instruments to prevent their collision.

There are a number of other methods of operative technique that have been described among the cases in this review. Simmons describes a case of performing the operation from the patients left side in which the authors believed that right handed dissection was comfortable [12]. However, their finding would be hard to replicate since the port sites were not a mirror image arrangement and were not explicitly described in their paper. Additionally, it is hard to conceptualise how this arrangement would facilitate a comfortable dissection under normal circumstances. The most commonly used position in patients with SI is with the patient supine. However, we felt that with the unique port placement the Lloyd-Davis position; where the surgeon stands between the legs, would facilitate an ergonomic dissection for the surgeon and assistant. In review of the literature this position was found to be commonly recommended to facilitate dissection [13-15]. Finally, five reports describe using the assistant to retract the infundibulum of the gallbladder which allows the surgeon to concentrate on the right-handed dissection without having to cross the hands [2,16-19].

LC in patients with SI is technically more challenging, although the literature shows that an experienced laparoscopic surgeon can perform the operation safely and without significant complications. The mean operative time from this series was 70 minutes (SD +/- 20 minutes), while a typical LC has an average of around 29 minutes (SD +/- 14 minutes) [20]. This shows a significantly longer operating time, although this information was only available in half the reports. There have been no reported complications of LC in patients with SI. However, there are two plausible reasons why there has been no reported complications in the literature to date. Firstly, the surgeons most likely approach the operation with more caution which results in a thorough pre-operative work-up and a more meticulous dissection intra-operatively. Additionally, surgeons are less likely to publish cases which have resulted in significant complications and this would result in a self-selecting bias of positive outcomes and a falsely low complication rate. Logically the incidence of conversion to open and other complications could be expected to be similar or higher due to the increased difficulty and unfamiliar circumstances of the operation.

Learning Points:

Laparoscopic cholecystectomy in patients with SI is technically more challenging.
Up to 5% of patients with SIT may present with RUQ pain.
An experienced laparoscopic surgeon can perform the operation safely without any increased risks to the patient.

We propose using a unique port site placement rather than a mirror image arrangement to allow for easier and safer dissection for right handed surgeons.

List of Abbreviations:

LC – Laparoscopic Cholecystectomy

CT – Computed Tomography

CTC – Computed Tomography Cholangiography

MRI – Magnetic Resonance Imaging

MRCP – Magnet Resonance Cholangiopancreatography

ERCP – Endoscopic Retrograde Cholangiopancreatography

IOC – Intra-operative Cholangiogram

SIT – Situs inversus totalis

LUQ – Left upper quadrant

RUQ – Right upper quadrant

DECLARATION SECTIONS:

Ethics approval and consent to participate: Ethics approval is not required for a case report by our institutional review board (Hunter New England Health Research Ethics Committee). Consent to participate has been obtained from the patient about which the article is written.

Consent for Publication: Patient consent was sought and obtained with written documentation prior to the patients' initial discharge from the operation. This consent was obtained after clearly explaining that his medical record information would be de-identified and images would be used in a case study publication.

Availability of data for publication: The datasets used during the current study are available from the corresponding author upon reasonable request.

Competing Interests: The authors declare that they have no competing interests.

References

1. Demetriades H, Botsios D, Dervenis C, et al. Laparoscopic cholecystectomy in two patients with symptomatic cholelithiasis and situs inversus totalis. Dig Surg, 1999;16:519-21
2. Lochman P, Hoffmann P, Koci J. Elective laparoscopic cholecystectomy in a 75-year old woman with situs viscerum inversus totalis. Videosurgery and other miniinvasive techniques, 2012;7(3):216-9
3. Drover J, Nguyen K, Pace R. Laparoscopic cholecystectomy in a patient with situs inversus viscerum: a case report. Can J Surg, 1992;35(1):65-6
4. Yaghan R, Gharaibeh K, Hammori S. Feasibility of laparoscopic cholecystectomy in situs inversus. J Laparoendosc Adv Sur Tech A, 2001;11(4):233-7
5. Machado N, Chopra P. Laparoscopic cholecystectomy in a patient with situs inversus totalis: Feasibility and technical difficulties. JSLS, 2006;10:386-91
6. Watson C, Rasmussen A, Jamieson N, et al. Liver transplantation in patients with situs inversus. BJS, 1995;82(2):242-45
7. Mirza B, Iqbal S, Sheikh A. Biliary atresia associated with polysplenia syndrome, situs inversus abdominus, and reverse rotation of intestine. APSP J Case Rep, 2012;3:14
8. Rao P, Katariya R, Sood S. Situs inversus totalis with calculus cholecystitis and mucinous cystadenomas of ovaries. J Postgrad Med, 1977;23(2):89-90
9. Akbulut S, Ulku A, Senol A, et al. Left-sided appendicitis: review of 95 published cases and a case report. WJG, 2010;16(44):5598-5602
10. Cholst L. Discrepancies in pain and symptom distribution: Position of the testicles as a diagnostic sign in situs inversus totalis. The American J Surgery, 1947;73(1):104-7
11. Aydin U, Unalp O, Yazici P, et al. Laparoscopic cholecystectomy in a patient with situs inversus totalis. WJG, 2006;12(47):7717-9
12. Simmons J, Maxwell E, Kenneth V. Laparoscopic cholecystectomy in the presence of abdominal situs inversus: Does surgeon position matter?. Am Surg, 2009;75(4):353
13. Iusco D, Sacco S, Ismail I, et al. Three-trocar laparoscopic cholecystectomy in patient with situs viscerum inversus totalis: Case report and review of the literature. G Chir, 2012;33:10-3
14. Ghosh N, Roy A, Bhattacharya S, et al. Laparoscopic cholecystectomy in situs inversus, a modified approach. IJS, 2008;19(2):1-3
15. Jesudason S, Vyas F, Jesudason R, et al. Laparoscopic cholecystectomy in a patient with situs inversus. Indian J Gastroenterol, 2004;23:79
16. Rafie B, AbuHamdan O. Laparoscopic cholecystectomy in patients with situs inversus totalis. Case Rep Soc Laparoscopic Surg Minimally Invasive Surg, e2014.00018
17. McKay D, Blake G. Laparoscopic cholecystectomy in situs inversus totalis: a case report. BMC Surg, 2005;5(5):1-2
18. Arya S, Das A, Singh S, et al. Technical difficulties and its remedies in laparoscopic cholecystectomy in situs inversus totalis: A rare case report. Int J Surg Case Rep, 2013:727-30
19. Borgaonkar V, Deshpande S, Kulkarni V. Laparoscopic cholecystectomy and appendicectomy in situs inversus totalis: A case report and review of literature. J Minim Access Surg, 2011;7(4):242-5
20. Voyles C, Boyd K. Criteria and benchmarks for laparoscopic cholecystectomy in a free-standing ambulatory center. JSLS, 1999;3:315-8

Author Information

Joel A Petit
Nepean Hospital
Kingswood, Australia

Kheman Rajkomar
Nepean Hospital
Kingswood, Australia