

Surgical Treatment Of Major Gynecomastia: A Report Of 2 Cases

A Ndiaye, A Sankalé, L Ndiaye, M Foba

Citation

A Ndiaye, A Sankalé, L Ndiaye, M Foba. *Surgical Treatment Of Major Gynecomastia: A Report Of 2 Cases*. The Internet Journal of Plastic Surgery. 2018 Volume 13 Number 1.

DOI: [10.5580/IJPS.52973](https://doi.org/10.5580/IJPS.52973)

Abstract

Introduction: Gynecomastia is an increase in breast volume in men. The surgical treatment consists of a glandular resection via the lower hemi-periareolar pathway, with or without liposuction. In case of moderate cutaneous excess, this gesture is completed by a skin lift by the technique of round-block. However, cases of major gynecomastia with significant ptosis generally require a mastectomy with reimplantation of the areola-nipple plate.

Observations: We report the cases of 2 young adults with severe bilateral gynecomastia treated by a mastectomy with the repositioning of the areolar-nipple plate in the plastic surgery department of Aristide Le Dantec Hospital.

Results: In postoperative period, one patient presented with unilateral hematoma and the other had a unilateral seroma, both of which were emptied. The aesthetic result was good and the patients were satisfied.

Conclusion: Mastectomy followed by reimplantation of the areolar plate is the best option in the treatment of major gynecomastia.

INTRODUCTION

Gynecomastia is an increase in breast volume in men. In the case most often encountered, it is a peripubertal gynecomastia without cutaneous excess in young adults. The surgeon performs a glandular resection via the lower hemi-periareolar pathway, whether or not initially associated with liposuction. In case of moderate cutaneous excess, this procedure is completed by a skin lift. A periareolar circular zone is desepidermised, then sutured according to the technique of round-block. However, cases of major gynecomastia with significant ptosis generally require a total mastectomy with reimplantation of the nipple-areola complex (NAC). The aim of our work was to evaluate the management of these cases of major gynecomastia in the aesthetic and reconstructive plastic surgery department of the Aristide Le Dantec Hospital in Dakar.

PATIENTS AND METHODS

This is a retrospective study over 2 years conducted in the aesthetic and reconstructive plastic surgery department of the Aristide Le Dantec Hospital in Dakar. Only patients with major gynecomastia surgery were retained and 2 patients

were selected. The criteria studied were: the age, the period of appearance of gynecomastia, the stage of gynecomastia, the associated pathology, the operative technique, the postoperative complications, the aesthetic result, and the satisfaction of the patient.

RESULTS

Patient 1

An 18-year-old, obese patient presented with a bilateral gynecomastia stage III (Simon's classification) (figures 1 and 2), which appeared during the pubertal period. In addition to the aesthetic discomfort, gynecomastia had caused the patient a state of malaise and a fear to undress in public. The rest of the clinical examination was without particularities. Hormonal balance was normal.

Our patient underwent a total bilateral mastectomy with reimplantation of the NAC. Positioning on the operating table was supine with arms crossed and the reimplantation of the recalibrated NAC at 3 cm of diameter was made in the breast axis, 3 cm above the inframammary groove. The resulting surgical scar was transverse at the level of the inframammary groove.

The operative course was marked by the constitution of a

seroma at the level of the right breast, resolving with a puncture using a catheter and a partial bilateral epidermolysis of the NAC.

With a follow-up of 5 months, the aesthetic result was good with exception of a partial depigmentation of the areolas due to the aforementioned epidermolysis (Figures 3 and 4). The patient is very satisfied with the final result.

Figure 1

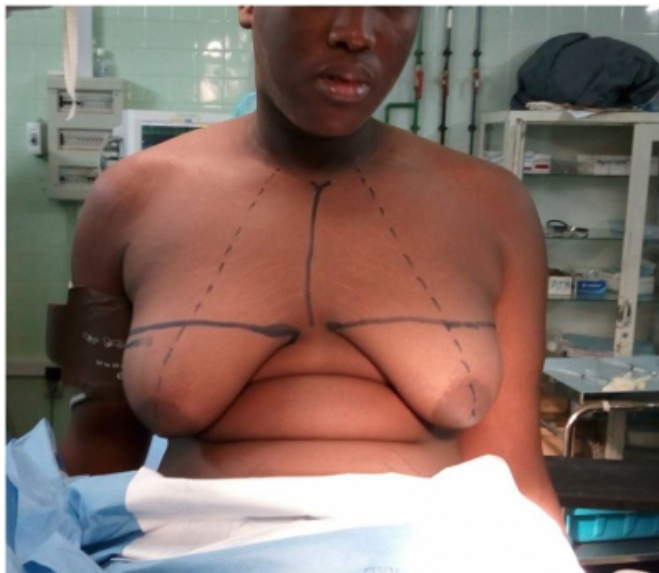


Figure 2

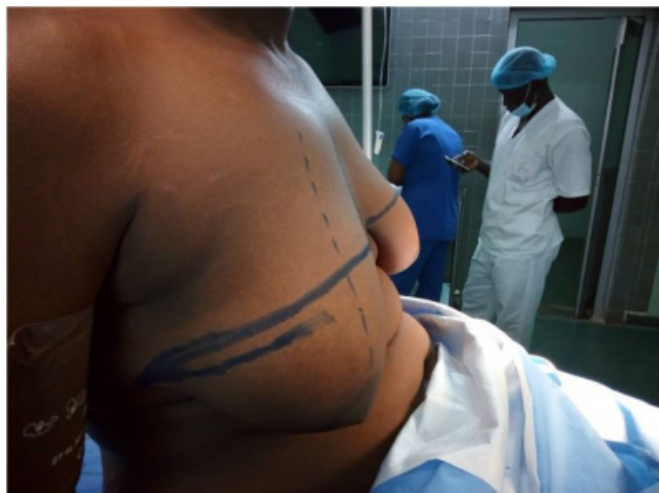


Figure 3

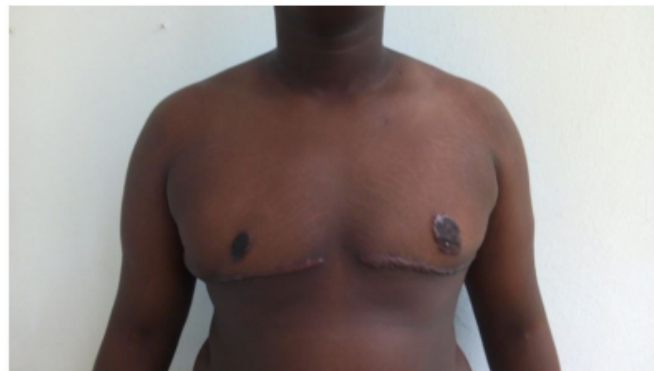
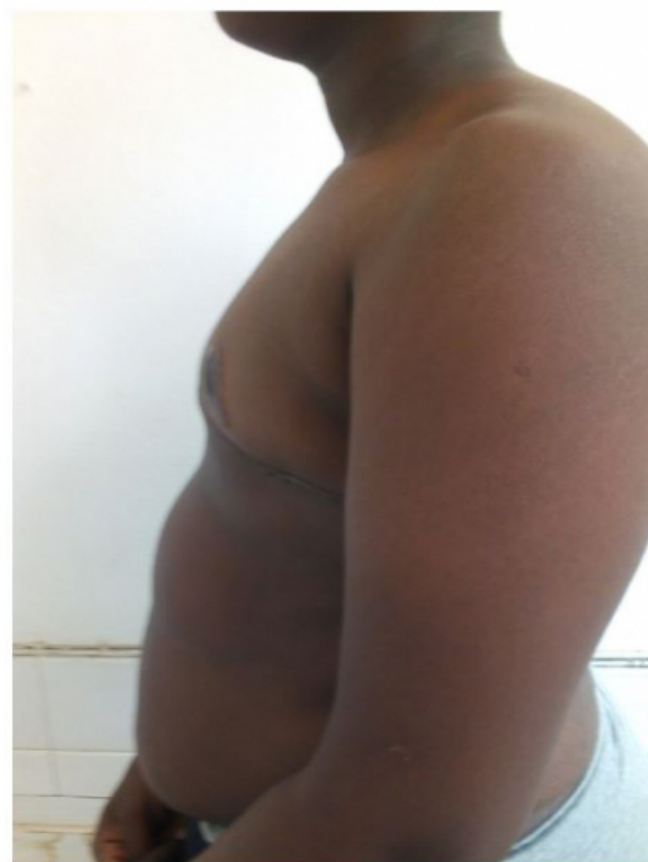
Figure 4



Patient 2

A 30 year-old patient from a country bordering Senegal, Mali, presented in our clinic. The obese patient was 30 years old and presented with a bilateral gynecomastia stage III of Simon's classification (figures 5 and 6). The rest of the examination as well as the hormonal assessment was normal. The patient was more psychologically tolerant of his gynecomastia.

Patient 2 benefited from the same operative technique as patient 1, namely a mastectomy with a re-implantation of the

NAC.

The postoperative follow-up was marked by a hematoma in the right breast which was emptied by transcutaneous puncture.

After 7 months, the aesthetic result was good (figures 7 and 8). The patient is very satisfied with the final result.

Figure 5

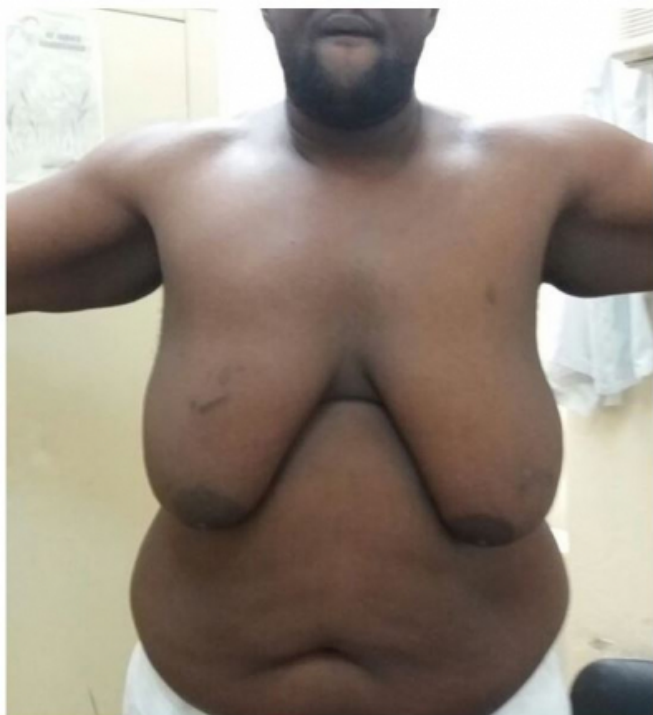

Figure 6

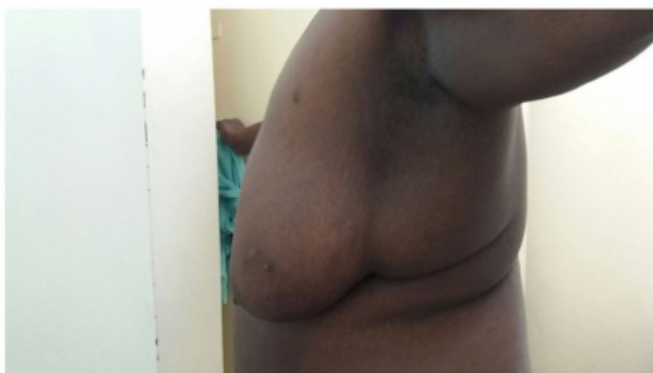


Figure 7

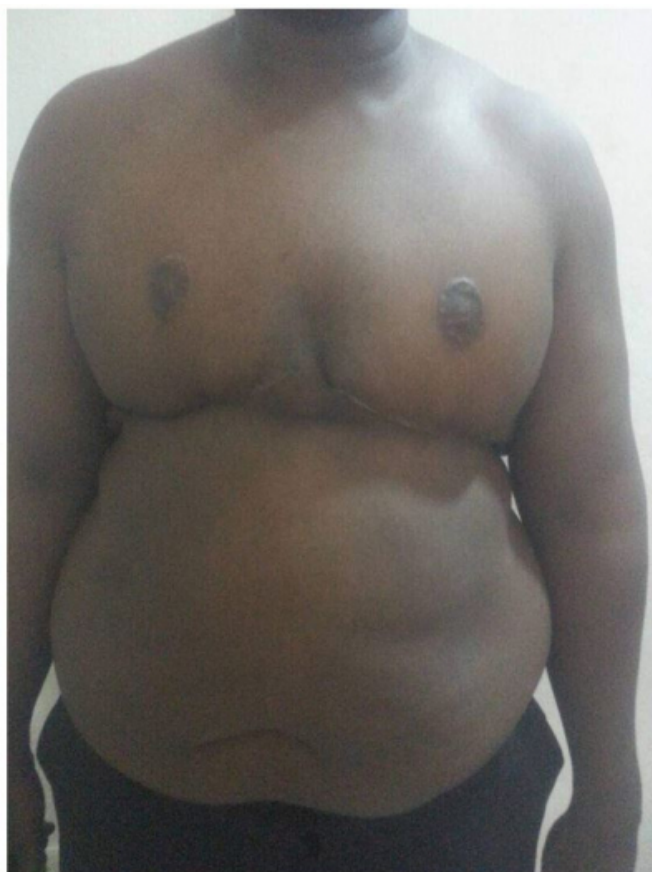
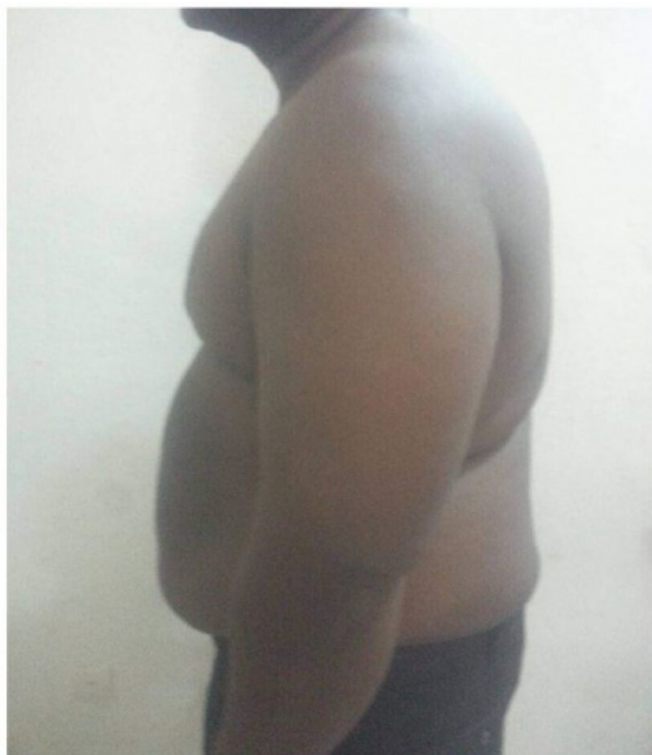
Figure 8



DISCUSSION

In both our patients, gynecomastia appeared at puberty. It was bilateral and of idiopathic origin. This presentation is valid for most gynecomastia based on literature data. In their series, Longheu [1] and Vasseur [2] reported 76% and 75% of the cases to be bilateral, and found an idiopathic cause in 82% and 63% of the cases. Vasseur mentions that 63% of cases that appeared at puberty. The main reason for consultation was aesthetic discomfort, but one must appreciate the psychological impact, particularly fear of exposure and a feeling of malaise, and loss of masculinity, especially in adolescents. A good psychological approach is necessary to communicate with these patients.

From the surgical point of view, considering the important glandular ptosis, the choice of a total mastectomy with NAC reimplantation was essential. It allows for better skin remodeling at the price of a long scar under breast. Other techniques, such as that of the lower pedicle reported by Thienot [3], or that of the superior pedicle reported by Stoff [4], make it possible to transpose the NAC instead of the graft. However, they require the preservation of glandular tissue that can give a curved appearance to the chest. The place of reimplantation of the PAM and the size of NAC are important for a good aesthetic result. Like Maetz [5], we calibrated a NAC of 3 cm in diameter, placed 3 cm above the inframammary groove in the breast axis. This is fairly easy to implement. However, there are more complex algorithms based on anatomical studies to determine the appearance and ideal position of the patient's NAC according to its morphotype. With the development of obesity surgery these techniques correcting major pseudo-gynecomastia experienced now popularity, whether in the Occident [6], Middle Orient [7] or Far Orient [8].

Post-operative complications such as hematoma or seroma (1 in 2 cases) and epidermolysis of NAC have affected our patients. They also affect other patients in various reports in different proportions: the percentage of post-operative hematoma is 11% for Colombo-Benkman [9], 8% for Maetz [5] and 6% for Varma and Henderson [10]. Maetz [5] also reports the occurrence of epidermolysis in 12.5% of his patients. We did not have any major complications such as NAC necrosis or surgical site infection.

The aesthetic result was good with high satisfaction in our two patients. However, the management of gynecomastia in general can be improved by the acquisition of a liposuction

machine. In the West, liposuction is used alone or combined with surgery for the treatment of gynecomastia. It allows to suck the greasy part while ensuring uniform skin retraction. In addition, the infiltration of adrenaline serum by the liposuction machine achieves a good glandular detachment at the same time as it reduces the risk of postoperative hematomas [10]; surgery becomes thereby easier and safer.

CONCLUSION

Total mastectomy followed by reimplantation of the nipple-areola complex is the best option for the treatment of major gynecomastia in our setting. For an optimum result, this technique must be preceded by a liposuction and a recovery of the technical plateau. Because of the racial particularities, it is our responsibility to study the anatomical structures of NAC for a good calibration and a good relocation of the nipple-areola complex.

References

1. Longheu A, Medas F, Corrias F, Farris S, Tatti A, Pisano G, Erdas E, Calò PG. Surgical management of gynecomastia: experience of a general surgery center. *G Chir.* 2016 Jul-Aug;37(4):150-154.
2. Vasseur C, Martinot V, Hodin E, Patenotre P, Pellerin P. Gynécomastie. Prise en charge diagnostique et thérapeutique: A propos de 52 cas. *Ann Chir.* 1998;52(2):146-57.
3. Thiénot S, Bertheuil N, Carloni R, Méal C, Aillet S, Herlin C, Watier E. Postero-Inferior Pedicle Surgical Technique for the Treatment of Grade III Gynecomastia. *Aesthetic Plast Surg.* 2017 Jun;41(3):531-541.
4. Stoff A, Velasco-Laguardia FJ, Richter DF. Central pedicled breast reduction technique in male patients after massive weight loss. *Obes Surg* 2012;22(3):44-51.
5. Maetz B, Bodin F, Abbou R, Wilk A, Bruant-Rodier C. Management of weight loss consequences in the male chest: The amputation grafting technique with a L scar. *Ann Chir Plast Esthet.* 2013 Dec;58(6):650-7.
6. Beer GM, Budi S, Seifert B, Morgenthaler W, Infanger M, Meyer VE. Configuration and localization of the nipple-areola complex in men. *Plast Reconstr Surg.* 2001 Dec;108(7):1947-53.
7. Shulman OI, Badani E, Wolf Y, Hauben DJ. Appropriate location of the nipple-areola complex in males. *Plast Reconstr Surg.* 2001 Aug;108(2):348-51.
8. Kasai S, Shimizu Y, Nagasao T, Ohnishi F, Minabe T, Momosawa A, Kishi K. An anatomic study of nipple position and areola size in Asian men. *Aesthet Surg J.* 2015 Feb;35(2):NP20-7.
9. Colombo-Benkman M, Buse B, Stern J, Herfarth C. Indications for and results of surgical therapy for male gynecomastia. *Am J Surg* 1999;178:60-3.
10. Varma SK, Henderson HP. A prospective trial of adrenaline infiltration for controlling bleeding during surgery for gynaecomastia. *Br J Plast Surg.* 1990 Sep;43(5):590-3.

Author Information

Aï Ndiaye

Plastic Surgery Department, UHC Aristide Le Dantec
Dakar, Sénégal
aninandiaye@yahoo.fr

AA Sankalé

Plastic Surgery Department, UHC Aristide Le Dantec
Dakar, Sénégal

L Ndiaye

Plastic Surgery Department, UHC Aristide Le Dantec
Dakar, Sénégal

ML Foba

Plastic Surgery Department, UHC Aristide Le Dantec
Dakar, Sénégal