

Right Atrial Myxoma with Atrial Septal Defect: A Case Report and Review of Literature

K Modi, J Pullen, P Reddy

Citation

K Modi, J Pullen, P Reddy. *Right Atrial Myxoma with Atrial Septal Defect: A Case Report and Review of Literature*. The Internet Journal of Cardiology. 2008 Volume 6 Number 2.

Abstract

The coexistence of right atrial myxoma and atrial septal defect is very rare. We report here a case of atrial septal defect associated with a right atrial myxoma with pulmonary embolization and cyanosis mimicking pulmonary thromboembolism.

CASE REPORT

A 25- year -old white female with a history of smoking presented with dyspnea, chest pain, and cyanosis. On physical examination, she had a temperature of 96.4, blood pressure of 132/90mm Hg with a heart rate of 132beats/min, and a respiratory rate of 32. Cardiac exam revealed tachycardia, a systolic murmur at the right upper sternal border and left upper sternal border, a diastolic murmur at the left upper sternal border and left lower sternal border without radiation to the neck or axillary area. Patient was found to have pulse oximetry of 80% on room air and no improvement with 100% oxygenation. Patient was intubated and pulmonary arteriogram was done which revealed a massive pulmonary embolism with almost 100% occlusion of the left main pulmonary artery with a filling defect as well as a right middle lobe filling defect (Figure 1) and atrial level defect is visualized as catheter passed from right atrium to left atrium and pulmonary vein. (Figure 2)

Figure 1

Figure 1: Digital Subtraction Pulmonary Angiography showing left main pulmonary artery filling defect with an arrow.

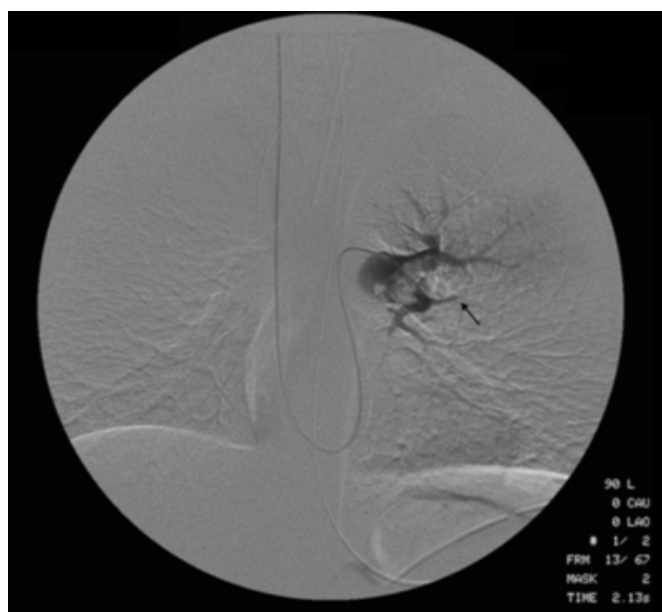


Figure 2

Figure 2: Digital Subtraction Pulmonary Venography showing catheter passing through atrial septal defect and opacification of left ventricle (thick arrow) and aorta (thin arrow) on venogram.

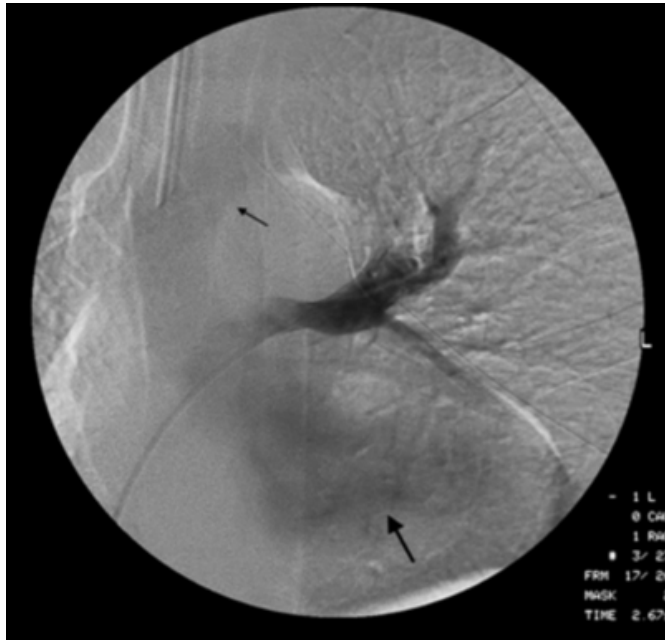
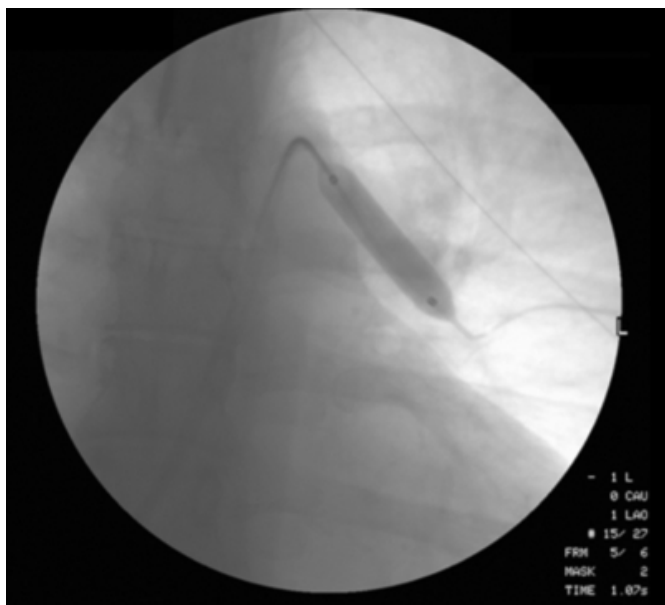


Figure 3

Figure 3: Attempted mechanical thrombectomy with balloon inflation of left pulmonary embolus.



Patient underwent thrombectomy and infusion of tissue plasminogen activator for 12 hours without much improvement on repeat pulmonary arteriogram. A transthoracic echocardiogram revealed an enlarged right ventricle and paradoxical septal wall motion. The patient

underwent surgery to remove the pulmonary embolus.

During surgery, a myxomatous tumor embolus was found in the main pulmonary artery. Also found were a right atrial myxoma attached to the lateral wall, and an atrial septal defect. The right atrial myxoma was removed and the septal defect was repaired. On third post-operative day the patient developed anisocoria and an inability to move the right extremities. CT scan of the head was not obtained because of the unstable condition of patient with ventilator dependency and continuous vasopressors use. Swan-Ganz catheter was placed and showed mean pulmonary artery pressure of 67 mmHg, Cardiac index of 2.6 l/m², and pulmonary capillary wedge pressure of 20 mmHg. Patient was put on nitric oxide treatment for pulmonary hypertension. On post operative day seven patient's neurological status as well as her overall condition failed to improve and the family decided to withdraw care leading to death.

DISCUSSION

Primary cardiac tumors of the heart are rare with a reported incidence of 0.0017 to 0.19 % in various autopsy series ¹. Approximately 75% of these primary cardiac tumors are benign. ² Of the benign cardiac tumors, myxomas are the most common, accounting for 50% of all primary cardiac tumors. ³ They occur most commonly in the left atrium (75 to 85%), but can also arise in the right atrium (15-20%) or the ventricles (5 to 10%). ⁴ An association of right atrial myxoma and atrial septal defect is very rare. To date, seven cases of this combination of lesions have been reported in the English literature. (Table 1, Ref ^{5,6,7,8,9,10,11}) The coexistence of right atrial myxoma and atrial septal defect results in unusual pathophysiology and a clinical presentation that is different from isolated right atrial myxoma. Most reported cases of right atrial myxoma present with symptoms and signs of right heart failure which were absent in our patient. In the present case of right atrial myxoma, the patient presented with sudden onset of dyspnea and was found to be cyanotic and hypoxic. Pulmonary embolism was suspected and pulmonary angiogram revealed a saddle pulmonary embolus. Atrial septal defect was suspected preoperatively secondary to right to left shunt on pulmonary angiogram. However, atrial myxoma was not suspected preoperatively. The reversal of the shunt resulting from acute right ventricular pressure overload from pulmonary embolus explains the cyanosis in our patient.

Before the advent of echocardiography, only 37% of patients were correctly diagnosed with myxoma preoperatively. This has now increased to 90% with the use of transthoracic and

transesophageal echocardiogram. In only one of the previously reported seven cases of right atrial myxoma with ASD, intravenous digital subtraction angiogram detected a shunt preoperatively.¹¹ In all other reported cases cardiac catheterization and angiography were employed to confirm the existence of a myxoma and an interatrial right to left shunt. In none of the previously reported cases echocardiogram was able to detect the intracardiac shunt preoperatively. Cardiac catheterization is potentially hazardous with known myxoma due to risk of embolization. Echocardiogram was of limited value in our patient because of her obesity. The treatment of choice for right atrial myxomas is surgical removal with a reported operative mortality of 0-3% in multiple series. Two deaths have been reported with right atrial myxoma complicated by pulmonary embolism in the absence of atrial septal defect in 1964 and 1970.¹² None of the previously reported cases had a triad of pulmonary embolism, atrial septal defect, and right atrial myxoma associated with an adverse outcome. Death in our patient could have been secondary to intracranial hemorrhage from prolonged thrombolytic therapy. This case illustrates the importance of high clinical suspicion of right atrial myxoma with atrial septal defect in the differential diagnosis of patient presenting with pulmonary embolism and cyanosis when transthoracic echocardiographic exam is limited.

Figure 4

Table 1: Cases of right atrial myxoma associated with atrial septal defect from 1960 to 2001

Author	Age	Gender	Diagnostic method	Post op outcome
Murayam	31	F	Digital Subtraction Angiography, Echo	Uneventful
Taber	51	F	Cardiac Cath	Uneventful
Willman	61	F	Cardiac Cath	Uneventful
Marpole	73	M	Cardiac Cath	Cerebral embolism
Talley	49	F	Cardiac Cath	Cerebral embolism
Powers	48	M	Cardiac Cath	Uneventful
Natarajan	63	F	Cardiac Cath	Uneventful

Echo, Echocardiography, Cath, Cardiac Catheterization,

CORRESPONDENCE TO

Dr. Kalgi Modi Address: LSU Health Science Center,
Department of cardiology P.O. Box 33932 Shreveport, LA
71130 Phone: 318 675 5941 Email kmodi@lsuhsc.edu

References

1. Reynen, K, M.D. Cardiac Myxoma NEJM Dec 14 1995 pp 1610 -16176.
2. Burke A, Jeudy J, Virmani R, Cardiac Tumors: an update Heart 2008; 94: 117-123
3. Braunwald E. Heart Disease. A Textbook of Cardiovascular Medicine, 6th ed. Philadelphia: WB Saunders Co; 2005.
4. Mittle S, Makaryus AN, Right sided myxoma, J Am Soc Echocardiogr 2005;18 e 14-7
5. Talley RC, Baldwin BJ, Symbas PN, Nutter DO. Right atrial myxoma. Unusual presentation with cyanosis and clubbing. Case Reports. Journal Article American Journal of Medicine. 48(2):256-60, 1970 Feb.
6. Powers JC, Falkoff M, Heinle RA, Nanda NC, Ong LS, Weiner RS, Barold SS. Familial cardiac myxoma: emphasis on unusual clinical manifestations. [Case Reports. Journal Article] Journal of Thoracic & Cardiovascular Surgery. 77(5):782-8, 1979 May.
7. Natarajan P, Vijayanagar RR, Eckstein PF, Bognolo DA, Toole JC. Right atrial myxoma with atrial septal defect: a case report and review of the literature. [Case Reports. Journal Article] Catheterization & Cardiovascular Diagnosis. 8(3):267-72, 1982.
8. Taber RE, Lam CR Diagnosis and surgical treatment of intracardiac myxoma and rhabdomyoma. J thorac and cardiovascular surgery 1960; 40: 337-54
9. William VL, Symbas PN, Mamiya RT, Cooper T, Unusual aspect of intracavitary tumors of the heart. Dig Chest. 1965; 47: 669-71
10. Marpole DGF, Kloster FE, Bristow JD, Griswold HE, Atrial myxoma; a continuing diagnostic challenge. Am J Cardiol 1969;23:597-602
11. Murayama H, Tamaki S, Kato N, Yuji N, Yokote J, Mutsuga M, Okada M. Right atrial myxoma associated with atrial septal defect: a case report and review of the literature. 2001, Ann Thorac Cardiovascular Surg Vol 7, No 3, 166-169
12. Idir, M, Oysel, N, Guibaud, JP, Fregmentation of a Right Atrial Myxoma Presenting as a Pulmonary Embolism, J Am Soc Echocardiogr 2000; 13:61-3

Author Information

Kalgi Modi, MD, FACC

Division of Cardiology, Louisiana State University Health Sciences Center

Jessica Pullen

School of Medicine, Louisiana State University Health Sciences Center

Pratap Reddy, MD, FACC

Division of Cardiology, Louisiana State University Health Sciences Center