

A National survey of the use of Powered instruments in Functional Endoscopic Sinus Surgery: UK Otolaryngology trainee perspective

S Duvvi, A Khattab, H Khalil, D Nunez

Citation

S Duvvi, A Khattab, H Khalil, D Nunez. *A National survey of the use of Powered instruments in Functional Endoscopic Sinus Surgery: UK Otolaryngology trainee perspective*. The Internet Journal of Otorhinolaryngology. 2005 Volume 4 Number 2.

Abstract

Objectives: To investigate the use of microdebrider for endoscopic sinus surgery by the otolaryngology trainees in the United Kingdom

Design: A standard postal questionnaire proforma consisting of 5 questions.

Setting: 200 trainees in secondary/tertiary otolaryngology centres in UK

Participants: 200 otolaryngological trainee surgeons in training who are regardless of their year of training were contacted by mail in December 2002 and January 2003. Of them, 164 responded. Three responses were incomplete and are ignored leaving the study number to 161.

Main outcome measures studied: Access to microdebrider, Details of use of microdebrider, Confidence in dealing complications and Training received.

Conclusion: Our study revealed that the usage of microdebrider is not as widespread as might be thought among the trainee otolaryngological surgeons in the United Kingdom.

INTRODUCTION

The use of powered instrumentation in functional endoscopic sinus surgery has been a revolutionary development in the surgical treatment of chronic sinusitis. Powered instrumentation has gained increased popularity in otolaryngology because of its safety and effectiveness in sinus surgery. An understanding of the principles and techniques of powered dissection of the sinuses, setup and handling of instrumentation, and pre- and postoperative care is necessary for otolaryngology trainee in management of patients undergoing these procedures. Several studies have demonstrated the safety, efficacy, and ease of use of this new technique. This survey provides some perspective on how the UK otolaryngology trainees use the Powered instruments in Functional Endoscopic Sinus Surgery

MATERIALS AND METHODS

A preliminary pilot study was done to check the trend of using powered instrumentation in FESS among otolaryngological trainees in UK. Twenty hospitals were selected randomly to conduct this initial pilot study, limiting the search to those trusts with an odd last digit in their main official telephone number did randomisation. This pilot survey has shown to us that the use of powered instrumentation is not so popular, and this has tempted us to widen the search in order to explore the current practice. A national survey was designed the forms were made short and precise with 5 questions (appendix). The questionnaire was sent by postal enquiry using a well-designed unified proforma with a self addressed and stamped envelope enclosed. The names of trusts were the Institute of Healthcare management year book 2002-2003 register of NHS Trusts in the UK and confirmed from the Association

of otolaryngology, Head and Neck surgery in the UK. Questions included are the same as those of the pilot study. Comments were welcomed and all comments were taken into consideration during analysis.

RESULTS

A total of 200 forms questionnaires were posted. One hundred and sixty four replies were received (82% per cent response rate). Incomplete replies (n = 3) were ignored, leaving the study number to 161. Trainees in 9 (5.59%) different centres have no access to any microdebriders. Figure I show the frequency with which the majority uses the microdebrider for treating inflammatory polyps or rhinosiusitis 81 (50.3%). Over half 90 (55.9%) had used the microdebrider for anterior ethmoidectomy, 61 (37.8%) for posterior ethmoidectomy, 75(46.5%) for maxillary, 33 (20.49%) for sphenoid and 23(14.2%) in frontal sinus disease. Figure II shows Frequency of use in relation to other disease indications mucocoele 19 (11.8%), orbital abscess 3 (1.8%), angiofibroma 2(1.2%) and for dacrocystorinostomies 9(5.59%). Majority thinks that complications of FESS are reduced by the microdebrider 61 (37.8%) or 63 (39.1%) don't know if there is any difference, 5 (3.1%) felt that there are more complications with microdebrider and 32 (20%) commented as no difference Table I. Ninety nine (61.49%) of otolaryngology surgeons in training have confidence in dealing with ocular and central nervous system complications if supervised, but 33(20.49%) have confidence in dealing with complications if not supervised Figure III. Formal teaching was admitted by only 123 trainees (76.39%).

Figure 1
Figure 1: Microdebrider usage in relation to sinus disease

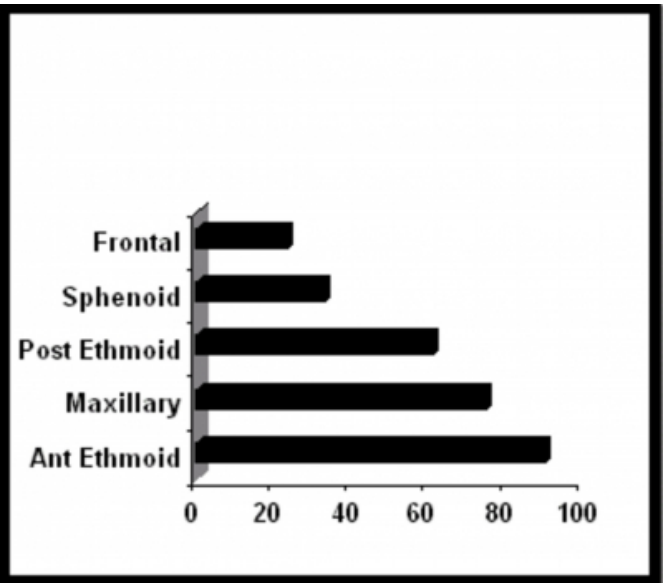


Figure 2
Figure 2: Microdebrider usage in relation to other conditions

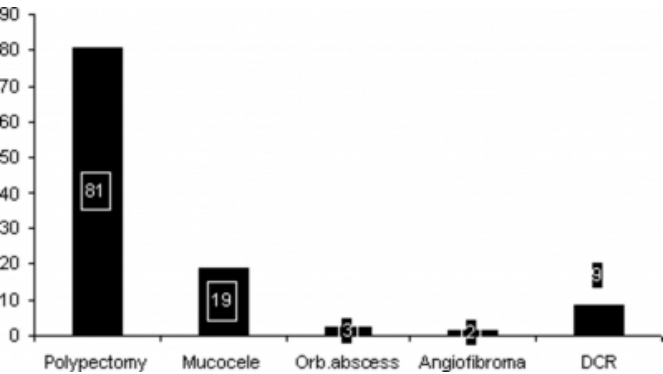


Figure 3

Figure 3: Confidence in dealing complication

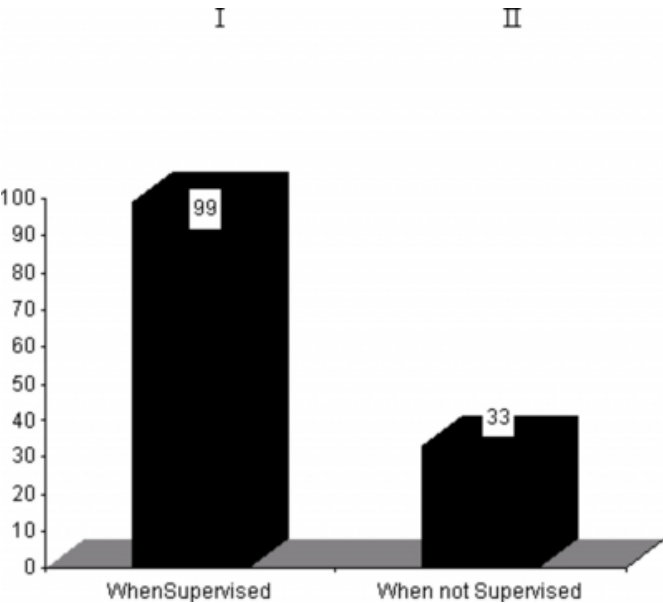


Figure 4

Table 1: Complications of powered fess to conventional fess.

More complications	5 trainees, 3.1%
Less complications	61 trainees, 37.8%
No difference	32 trainees, 20%
Don't know	63 doctors, 39.1%

Figure 5

Table 2: Questionnaire for the use of microdebrider in FESS

1: Do you routinely use the microdebrider for the treatment of?

Rhino sinusitis& polyps..... Mucocoele..... angiofibroma.....

Orbital abscess..... DCR.....

2: Do you use of microdebrider for FESS on the:

Anterior ethmoid..... posterior ethmoid..... maxillary.....

Sphenoid....., Frontal sinuses.....

3: How are the complications of powered FESS compared with conventional FESS?

More....., LESS

4: Do you have confidence in dealing with ocular and neuronal complications of FESS:

Supervised..... Unsupervised.....

5: What teaching did you receive in the use of microdebrider in FESS:

Formal..... Informal.....

DISCUSSION

Over the past decade rhinological surgery has completely changed. Introduction of endoscopes, powered shavers and lasers assisted the technical aspects of the surgery. Our study

reveals a wide variation in the usage of microdebrider (powered shaver) in rhinological procedures by the trainee ENT surgeons in UK. This variation may reflect the availability of surgical tool, the way in which a particular surgeon is trained and the surgeon's belief as to its usefulness.

The microdebrider is a powered rotary shaving device It provides atraumatic dissection by resecting tissue precisely, minimizing inadvertent mucosal trauma and stripping The use of the microdebrider, as a form of powered instrumentation for endoscopic sinus surgery when compared with traditional endoscopic surgical technique the results showed were minimal bleeding, decreased surgical time, faster postoperative healing minimal crust formation, low incidence of synechiae formation and potential cost savings are significant advances offered by the use of this instrumentation. It is easily learned and requires minimal supplemental instrumentation.^{1, 2, 3}

Its use has been extended for removal benign tumors such as osteomas, benign vascular tumors, pituitary adenomas, pneumoceles, benign fibrous tumors, antrochoanal polyps, orbital decompression for dysthyroid eye disease, rhinophyma.^{4, 5, 6, 7}

The microdebrider is particularly helpful for sinus surgery in children, who have smaller anatomic spaces and closer proximity of vital structures. Shaving action combined with continuous real-time suction of the soft-tissue shavers can provide the technical advantage to allow greater precision and ease in performing paediatric endoscopic sinus surgery. In children it is used in benign and malignant sinonasal or base of skull tumors, choanalatresia, complicated adenoidectomies, dacryocystorinostomies, septal spurs, and recurrent respiratory papillomatosis.^{8,9}

These instruments can remove mucosa, neoplastic tissue, cartilage, thin bony septations, nasal debris, and blood under continuous endoscopic visualization. Despite advances in endoscopic sinus surgery technique and instrumentation, the most dreaded ophthalmic and CNS complications may still occur.¹⁰ It is important for endoscopic sinus surgeons to be aware of the intimate anatomical relationship between the orbit and sinuses, as well as the potential risks of the current instruments used in endoscopic sinus surgery.

In UK however microdebrider use among the trainees at present is mostly restricted to the surgical management of

inflammatory sinus disease and nasal polyposis. The majority of powered FESS has been practised in the 'accessible' sinuses of anterior ethmoid and maxillary, as apparent from this study. Not many of trainees have tackled the posterior ethmoid sinus lesions and even fewer have explored the frontal sinus using the microdebrider during performing FESS. However this trend has been reported to be noticed worldwide and could be related to the pathology of the lesions treated. According to the survey this fact could be attributed to many factors lack of experience of use in other conditions or lack of confidence in dealing complications.

With the learning curve and experience in use of powered soft-tissue shavers in standard functional endoscopic sinus surgery majority of trainees were not aware whether microdebrider usage will lead to fewer complications over the use of standard instrumentation more long term studies are required to confirm this.

Confidence in the microdebrider usage is building worldwide with its expanded role to treat benign tumors such as osteomas, benign vascular tumors, pituitary adenomas, pneumoceles, benign fibrous tumors, antrochoanal polyps, orbital decompression for dysthyroid eye disease, rhinophyma^{4, 5, 6,7} but more studies are required to see whether the use can improve the long-term results .

The frontal recess has been regarded as a problematic area in the use of FESS, due to its anatomic location and associated risk of serious complications. The treatment of refractory frontal sinusitis is extremely safe and effective using this technique¹¹. Powered device technique provides an attractive alternative to other method for removing the antral portion of antrochoanal polyp with minimal morbidity⁵.

The use of powered instrumentation has now expanded to include a variety of sinonasal procedures in children.^{8,9} Paediatric FESS is usually done with the microdebrider which gives increased precision for complicated procedures that often were difficult in tiny nostrils in children, with continuous suction at the operative site. Use of the microdebrider as a hummer makes opening of maxillary and sphenoid sinuses and revision of the frontal and sphenoethmoidal recess much easier and safer with no complications¹².

Powered shaving devices are versatile in its uses within the office setting or outpatient department under local

anaesthesia¹³, with ever demanding bed crisis in NHS, last but not least the practicality of the microdebrider technique in the surgical treatment of nasal polyps as outpatient procedure with minimal bleeding and discomfort needs considering.

Complications in powered functional endoscopic sinus surgery are not uncommon and some of them are really serious and frightening, in particular to the new trainees. Subarachnoid haemorrhage, Ocular motility dysfunction has been reported as a complication of endoscopic sinus surgery using powered instrumentation^{14, 15}.

Training of the trainees in otolaryngology on the use of the microdebrider is vital. There have been tremendous advances in the training on FESS recently and early engagement in the training process is crucial. Our survey has showed some lack of confidence in dealing with the potential complications during the course of FESS.

We have chosen this type of survey for its popularity and its simplicity. Unfortunately, we couldn't find a suitable 'validated' survey in the subject and we avoided the use of generic questionnaires. We selected the questions carefully to include the overall training issues. Our survey represents a real life population sample of the majority of our trainees so that the findings would be a reflection of their experience. We appreciate that some of the answers may be judgmental, or done in an attempt to rush into an early or ill-thought conclusion by the respondents when faced some of the questions. The answers also are affected by the level of experience and the sharpness of memory at the time of filling the forms. Interest in the subject and devotion to it might have affected some answers. The time of the survey was chosen in December-January to give trainees time in their new placements after their changeover in October. Outcome measures are chosen to represent important issues in the way of training on the microdebrider in FESS. The three forms which were excluded were without any answer (one form), or with written comments without a clear cut answer of 'yes' or 'no', in two forms.

CONCLUSION

Our study shows that the usage of microdebrider is not as widespread as might be thought among trainee surgeons in the United Kingdom. The intention of this study is not to make a judgement on the optimal usage of newer surgical aids, but to highlight and present the current usage of such tools among the trainee surgeons in the country. Our

findings have implications for training of Otolaryngologist in use of powered instruments in endoscopic sinus surgery. The extended role of these instruments to be taken in to training at an early stage which helps in confidence building and also in dealing with complications resulting from the use of the powered devices.

ACKNOWLEDGEMENT

Our thanks are devoted to Professor Martin Birchall of Bristol University for advice and support.

We are grateful to all our participating otolaryngology trainees for their time in filling the questionnaire.

CORRESPONDENCE TO

Mr S K Duvvi Department of otolaryngology Warrington hospital UK Email: skduvvi@aol.com Ph- 01925662116

References

1. Christmas DA Jr, Krouse JH. Powered instrumentation in functional endoscopic sinus surgery. I: Surgical technique. *Ear Nose Throat J* 1996 Jan;75(1):33-6, 39-40
2. Krouse JH, Christmas DA Jr. Powered instrumentation in functional endoscopic sinus surgery. II: A comparative study. *Ear Nose Throat J* 1996 Jan;75(1):42-4
3. Bernstein JM, Lebowitz RA, Jacobs JB. Initial report on postoperative healing after endoscopic sinus surgery with the microdebrider. *Otolaryngol Head Neck Surg* 1998 Jun;118(6):800-3
4. Daele J, Rombaux P, Moreau P, Born J, Eymael P. EES in rare benign tumors. *Acta Otorhinolaryngol Belg* 2000;54(2):123-33
5. Hong SK, Min YG, Kim CN, Byun SW. Endoscopic removal of the antral portion of antrochoanal polyp by powered instrumentation. *Laryngoscope* 2001 Oct;111(10):1774-8
6. Koay B, Bates G, Elston J. Endoscopic orbital decompression for dysthyroid eye disease. *J Laryngol Otol* 1997;111:946-9.
7. Kaushik V, Tahery J, Malik TH, Jones PH. New surgical adjuncts in the treatment of rhinophyma: the microdebrider and FloSeal. *J Laryngol Otol*. 2003 Jul;117(7):551-2.
8. Parsons DS. Rhinologic uses of powered instrumentation in children beyond sinus surgery. *Otolaryngol Clin North Am* 1996 Feb;29(1):105-14
9. Josephson GD, Vickery CL, Giles WC, Gross CW. Transnasal endoscopic repair of congenital choanal atresia: long-term results. *Arch Otolaryngol Head Neck Surg*. 1998 May;124(5):537-40.
10. May M, Levine HL, Mester SJ, Schaitkin B. Complications of endoscope 1994;104:1080-3. sinus surgery: analysis of 2108 patients--incidence and prevention. *Laryngoscope* 1994;104:1080-3.
11. Christmas DA Jr, Krouse JH. Powered instrumentation in dissection of the frontal recess. *Ear Nose Throat J* 1996 Jun;75(6):359-60, 363-4
12. Lopatin as, piskunov gz. [the hummer microdebrider--new technology in functional endonasal rhinosurgery]. *Vestn Otorinolaringol* 1996 Nov-Dec;(6):54-7
13. Krouse JH, Christmas DA Jr. Powered nasal polypectomy in the office setting. *Ear Nose Throat J* 1996 Sep;75(9):608-10
14. Berenholz L, Kessler A, Sarfaty S, Segal S. Subarachnoid hemorrhage: a complication of endoscopic sinus surgery using powered instrumentation. *Otolaryngol Head Neck Surg* 1999 Nov; 121(5):665-7.
15. Bhatti MT, Giannoni CM, Raynor E, Monshizadeh R, Levine LM. Ocular motility complications after endoscopic sinus surgery with powered cutting instruments. *Otolaryngol Head Neck Surg* 2001 Nov;125(5):501-9.

Author Information

S. Duvvi, MRCS

Department of Otolaryngology Head and Neck Surgery, Southmead Hospital

A. Khattab, FRCS

Department of Otolaryngology Head and Neck Surgery, Southmead Hospital

H.S. Khalil, FRCS

Department of Otolaryngology Head and Neck Surgery, Southmead Hospital

D. Nunez, FRCS

Department of Otolaryngology Head and Neck Surgery, Southmead Hospital