

Bilateral Proptosis: Unusual presentation of Cortical Sinus Thrombosis.

A Bhatt, J Ingole, S Kumar, A Jain

Citation

A Bhatt, J Ingole, S Kumar, A Jain. *Bilateral Proptosis: Unusual presentation of Cortical Sinus Thrombosis.* The Internet Journal of Internal Medicine. 2008 Volume 8 Number 1.

Abstract

We report a rare presentation of Cortical Sinus venous thrombosis. This case presented with bilateral proptosis in an adult female. CT scan of brain showed left cavernous sinus and bilateral superior ophthalmic vein thrombosis with Right subdural hematoma (9cm x1.5cm).

INTRODUCTION

Thrombosis of the cortical veins and sinuses is a distinct Cerebrovascular disorder that, unlike arterial stroke, most often affects young adults and children. The symptoms and clinical course are highly variable. The estimated annual incidence is 3 to 4 cases per 1 million population and up to 7 cases per 1 million among children. About 75 percent of the adult patients are women [1]. During the past decade, increased awareness of the diagnosis, improved neuroimaging techniques, and more effective treatment have improved the prognosis. More than two third of all patients now have a good neurologic outcome [2]. We present here, a case of a 30 years young female who presented with history of headaches and bilateral Proptosis.

CASE SUMMARY

A 30 year old female presented to the emergency department of the hospital with diffuse headache and bilateral proptosis, which was associated with vomiting. On examination she was conscious, oriented, but anxious. She also had low grade fever. There was no history of ear discharge, cough, or burning micturition. She was normotensive and nondiabetic. There was no history suggestive of seizures. No past history suggestive of convulsions, tuberculosis. She is P2L2A0 and the previous deliveries were normal without any complicating events.

General physical examination suggested pulse was 100/min and regular. Her blood pressure at the time of admission was 120/70 mmHg in left upper limb supine position. She was pale and anicteric. On CNS examination, patient had bilateral proptosis with restricted Left Eye movement (III

nerve palsy). There was also associated chemosis and corneal haziness (Due to Exposure of cornea). Papilloedema was also present in fundi of both eyes. All other cranial nerves were normal. There was no any other neurological deficit. Deep tendon reflexes preserved and plantars were flexors.

Her investigations revealed hemoglobin was 10.5 gm/dl, total leukocyte counts were 15,000 per cubic mm. Platelets were normal. There was no sickle cell on peripheral smear. Anti phospholipids antibody was normal. Her chest film was normal. Patient underwent CT scan head –both without and with contrast study. CT scan showed left cavernous sinus thrombosis extending to bilateral superior ophthalmic vein thrombosis [Fig-1]. There was also right subdural hematoma [Fig-2]. On the basis of this CT scan findings and clinical feature we treated the patient with I.V. mannitol, higher antibiotics and corticosteroids. Patient did not show any improvement. She died on subsequent day.

Figure 1

Fig 1 : Bilateral Ophthalmic Vein thrombosis

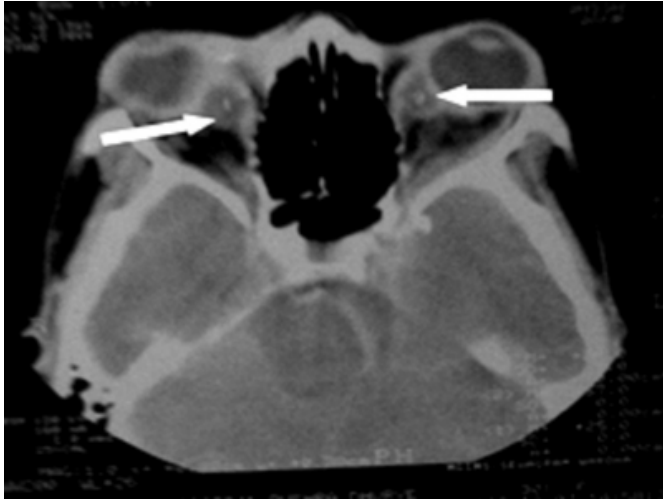
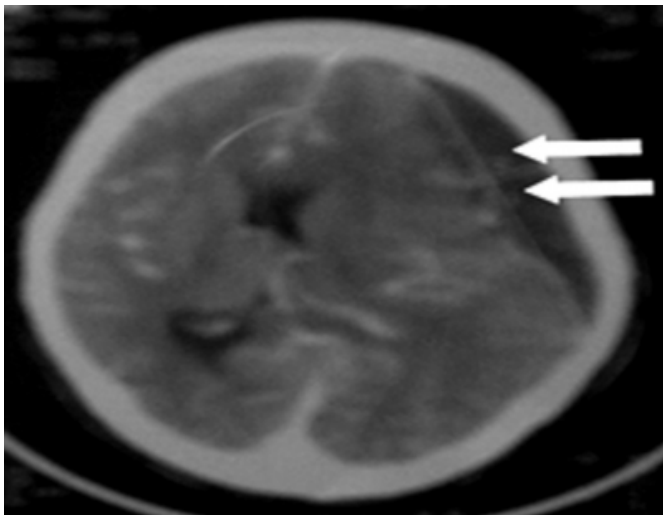


Figure 2

Fig 2 : Subdural hematoma in same patient



DISCUSSION

The first description of thrombosis of the cortical veins and sinuses is attributed to the French physician Ribes, who in 1825 observed thrombosis of the sagittal sinus and cortical veins in a man who had suffered from seizures and delirium [3]. Commonest clinical presentations of cortical sinus venous thrombosis include severe headache which gradually worsens with time and seizures which might be present in half the patients. Apart from these, altered mental status, depressed level of consciousness and neurological deficits are also common mode of clinical presentation.

Generally, patients have associated risk factors like blood coagulation abnormalities ,e.g. factor V Leiden, protein C and protein S deficiency , Nephrotic syndrome, Pregnancy

and post partum state and local infections as mastoiditis and sinusitis[4]. Superior sagittal sinus is affected commonly followed by Cavernous sinus. The lateral wall of cavernous sinus contains III, IV, first division of V and VI cranial nerves. This causes multiple cranial nerve palsies often associated with Proptosis [5]. Our case was unusual in the form that patients had bilateral superior ophthalmic vein thrombosis with left cavernous thrombosis which is a rare manifestation.

Amongst the various neuroimaging techniques, MRI scores over CT scan for being able to visualize the thrombus clearly and detect cerebral edema and infarction better however it is unavailable in many hospitals and the interpretation may be difficult [6]. A systematic review of nineteen studies done in 2006 showed that mortality is about 5.6% during hospitalization and 9.4% in total, while of the survivors 88% make a total or near-total recovery[2]. Death is most often due to transtentorial herniation from cerebral edema or hemorrhagic stroke [7]. It recurs after treatment in fewer than 10% of cases [8]. The poor prognostic indicators include status epilepticus, intracranial hemorrhage, coma, old age and underlying sepsis or malignancy [9].

Treatment strategies are aimed at treating the underlying pathology, controlling intracranial pressure and treatment of seizures or focal deficits caused by cerebral edema or infarction. Guidelines now recommend unfractionated heparin or low molecular weight heparin for the initial treatment to be followed by warfarin provided there are no other bleeding risks [10]. Surgical techniques are used to treat only for sequelae of CVST such as hydrocephalus, raised intracranial pressure and hemorrhagic stroke [11]. In spite of a sea of evidence and guidelines regarding medical management, the area of surgical management still remains a topic for debate and newer interventional strategies as endovascular surgeries need to be studied so as to clearly define the indications of surgery.

References

1. Einhäupl K, Boussier MG, de Bruijn SF, et al (2006). "EFNS guideline on the treatment of cerebral venous and sinus thrombosis". *Eur. J. Neurol.* 13 (6): 553–9. PMID 16796579.
2. Dentali F, Gianni M, Crowther MA, Ageno W (2006). "Natural history of cerebral vein thrombosis: a systematic review". *Blood* 108 (4): 1129–34. PMID 16609071.
3. Ribes MF (1825). "Des recherches faites sur la phlébite". *Rev Med Franc Etrang* 3: 5-41. www.wikipedia.com
4. Jan Stam,: Thrombosis of the Cerebral Veins and Sinuses ; *N Engl J Med* 2005;352:1791-8.
5. Prakash C, Bansal BC. Cerebral venous thrombosis. *J Indian Acad Clin Med* 2000;5:55-61.

6. Smith R, Hourihan MD (2007). "Investigating suspected cerebral venous thrombosis". *BMJ* 334 (7597): 794–5. PMID 17431266.
7. Canhao P, Ferro JM et al. Causes and predictors of death in cerebral venous thrombosis. *Stroke* 2005; 36(8):1720-1725.
8. Masuhr F, Mehraein S, Einhaupl K. Cerebral venous and sinus thrombosis. *J Neurol* 2004; 251(1):11-23.
9. Girot M, Ferro JM et al. Predictors of outcome in patients with cerebral venous thrombosis and intracerebral hemorrhage. *Stroke* 2007; 38(2):337-342.
10. Stam J, De Bruijn SF, DeVeber G (2002). "Anticoagulation for cerebral sinus thrombosis". *Cochrane Database Syst Rev* (4): CD002005. PMID 12519565.
11. Einhaupl K, Boussier MG, de Bruijn SF, Ferro JM, Martinelli I, Masuhr F et al. EFNS guideline on the treatment of cerebral venous and sinus thrombosis. *Eur J Neurol* 2006; 13(6):553-559.

Author Information

Amit Bhatt

Lecturer, Department of Medicine Mahatma Gandhi Institute of medical sciences Sewagram Wardha

Jitendra Ingole

Ex-Registrar, Department of Medicine Mahatma Gandhi Institute of medical sciences Sewagram Wardha

Sunil Kumar

Senior Lecturer, Department of Medicine Mahatma Gandhi Institute of medical sciences Sewagram Wardha

AP Jain

Director Prof and Head, Department of Medicine Mahatma Gandhi Institute of medical sciences Sewagram Wardha