

Giant Leiomyoblastoma Of The Ileum: Report Of A Rare Case And Review Of The Literature

H Nggada, T Bashir, A Ibrahim, K Yawe, M Khalil

Citation

H Nggada, T Bashir, A Ibrahim, K Yawe, M Khalil. *Giant Leiomyoblastoma Of The Ileum: Report Of A Rare Case And Review Of The Literature*. The Internet Journal of Third World Medicine. 2005 Volume 3 Number 2.

Abstract

A case of giant leiomyoblastoma of the ileum in a 60-year-old farmer is presented. The patient complained of 4 months and 2 months history of periumbilical pains and swelling respectively. There was no associated bleeding at presentation and no evidence of intestinal obstruction. The tumour at laparotomy was terminal ileal in origin, solitary, weighing 2.1kg, measuring 19X16X11cm and completely intramural with mucosal ulceration and microscopically showed features of leiomyoblastoma. The patient had resection and end-to-end anastomosis and remained well after 3 months of follow up.

INTRODUCTION

Leiomyoblastoma (Bizarre leiomyoma) was first reported by Martin et al in 1960₁. Two years later Stout proposed the term leiomyoblastoma to distinguish this new entity from the common smooth muscle tumours₂. The lesion arises from a distinctive cell, the leiomyoblast₂. The stomach accounts for the primary site in 93% of all the cases₃. This case report is the first leiomyoblastoma of the ileum to be reported in Nigeria in an adult (60 years). We are highlighting this extremely rare case, with review of literature.

CASE REPORT

A 60-years-old farmer from Tarmuwa L.G.A. of Yobe State of Nigeria presented in the surgical out patients' clinic of University of Maiduguri Teaching Hospital with 4 months of periumbilical pain and 2 months history of periumbilical swelling. The periumbilical pain was colicky, non-radiating, made worse by eating and no relieving factors. There was associated constipation, but no vomiting. Two months later, he noticed a lump in the umbilical area. The lump progressively increased in size to its size at presentation. There was no associated fever, jaundice, no chest pain, cough or difficulty in breathing. He had lost weight and had no urinary symptoms.

On examination, he was ill looking, pale and moderately dehydrated, not in any form of distress. Other findings were on abdominal examination, which revealed a central intra-abdominal mass with smooth surface, moved perpendicular to the line of attachment of the mesentery but not along it.

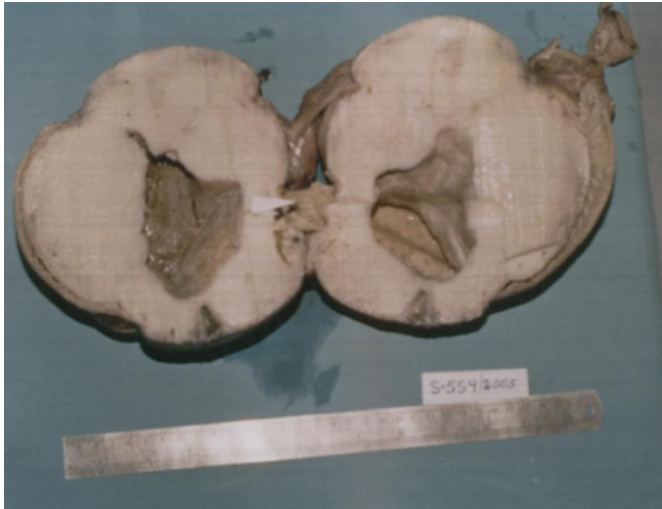
The liver and spleen were not enlarged and there was no ascitis. The external genitalia were normal and rectal examination was unremarkable. The biochemical parameters were also unremarkable. PCV-27%, ESR-130 mm/hr and stool microscopy was negative for melena. Abdominal ultrasound revealed a mesenteric solitary, soft tissue mass. The clinical diagnosis of mesenteric tumour to rule out lymphoma was made. He was prepared for explorative laparotomy. The intra-operative findings were that of a roundish mass involving the ileum and its mesentery about 50cm from the ileocaecal valve. The segment of the affected ileum was resected together with its mesentery and primary end-to-end anastomosis was carried out. Patient did well post-operatively and was discharged home on the 10th postoperative day and remained well after 3 months of discharge.

PATHOLOGICAL FINDINGS

The gross specimen was a huge, round mass, well circumscribed, weighing 2.1kg and measured 19x16x11cm. The cut surface is firm, solid, greyish white whorled appearance and showing a cavity of central ulcer crater and part of the bowel was ulcerated deep into the tumour (fig1).

Figure 1

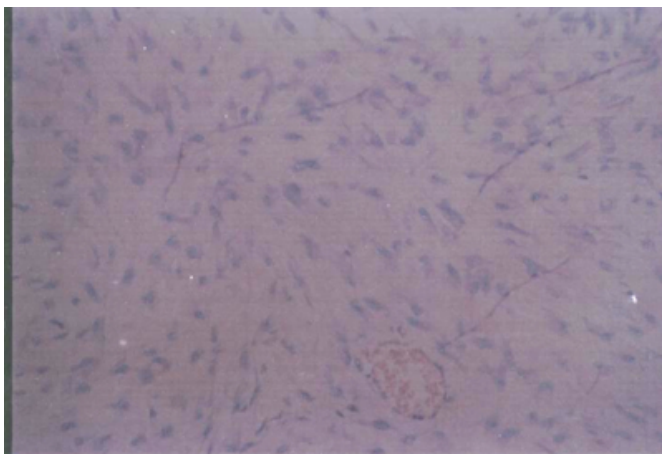
Figure 1: Cut surface of leiomyoblastoma with central crater ulcer (arrow showing intestinal mucosa)



The microscopy revealed a well circumscribed tumour composed of interlacing fascicles of spindle shaped cells with blunt nuclei and abundant eosinophilic cytoplasm. There was a focal area of hypercellularity, large nuclei with perinuclear vacuolation. Special stains reaction for mucus and glycogen were negative. Mitotic figures are 2-3/Hpf and no evidence of necrosis (fig.2), a histological diagnosis of leiomyoblastoma of the ileum was made.

Figure 2

Figure 2: Photomicrograph of Leiomyoblastoma. H&E. X140



DISCUSSION

Leiomyoblastomas of the small intestine are rare, and the small bowel may have intrinsic protective system against the development of neoplasms⁴. However, Spiliotis et al reported 38% of smooth muscle tumour in the small intestine in 32 series of gastrointestinal tumours over a period of 10

years⁵. Gourtsoyiannis et al reported 7 cases of leiomyomas of the small intestine over 7 years⁶. While Ameh et al in Zaria, Nigeria reported a case of small intestinal leiomyoma in a 6-year-old girl⁷. Dass et al also reported a case of leiomyoblastoma of the small intestine in a child⁸. Our case was benign leiomyoblastoma of the small intestine (ileum) in an adult, the first case to be reported from our tertiary hospital over 15 years. Although, there were two reported cases of leiomyoblastomas of the stomach in Calabar over 15 years and one reported case of small intestinal leiomyoma in childhood in Zaria, Nigeria.^{7,9,10}

The presentation of leiomyoblastoma or gastrointestinal stromal tumour of the small intestine is abdominal swelling or mass, pains, gross or occult haemorrhage and intestinal obstruction^{7,8,11,12,13}. On occasions, some of these presentations may be responsible for emergency abdominal surgery¹⁴. Our patient only presented with abdominal swelling and pains despite the severe mucosal ulceration of the small intestine as shown in figure 1. The patient certainly has bleeding from the ulceration subclinically prior to presentation. Thus, accounting for the anaemia. The bleeding could have being chronic and probably the reason why the patient was anaemia (PCV-27%).

The diagnosis of gastrointestinal stromal tumour by ultrasound imaging is non-specific and defining the site of origin may also be difficult to determine as in this case. Other specific investigations like selective angiography define the size, localize the bowel segment with the tumour and identify the blood supply¹⁵. However, angiography was not done in this case because it was not preoperatively suspected.

The explorative laparotomy was able to define the mass as an ileal tumour and the mass was resected and anastomosed. The histological diagnosis of the lesion showed a focal area of bizarre leiomyoma (leiomyoblastoma) of stout as shown in figure 2. Surgery remains the main modality of treatment.

In conclusion, we reported a rare case of a giant leiomyoblastoma of the ileum in an adult farmer presenting with abdominal mass, pain and anaemia.

CORRESPONDENCE TO

Dr.H.A.Nggada. P.O.Box. 316. Maiduguri. Borno State. E-mail: hanaggada@yahoo.com

References

1. Martin JF, Bazin P, Feroldi J, Cabanne F. Tuveurs myoides intra-murales de L'estomac- considerations

- microscopiques apropos de 6 cas, Ann Anat Pathol(Paris)1960;5:484-497.
2. Stout AP. Bizarre smooth muscle tumour of the stomach. Cancer 1962; 15:400- 409.
 3. Lavin P, Hajdu SI, Foote FW. Gastric and extragastric leiomyoblastomas. Cancer 1972; 29: 305- 311.
 4. Croom RD 3rd, Newsome JF. Tumours of the small intestine. Am Surg 1975; 41: 160-7.
 5. Spiliotis J, Scopa CD, Kyriakopoulou D, Pitsis A, Melachrinou M, Tzoracoleftherakis E, et al. Smooth muscle tumours of the gastrointestinal tract, A 10-year experience. Eur J Surg Oncol. 1992; 18:580-4.
 6. Gourtsoyiannis NC, Bays D, Papaioannou N, Theotokas J, Barouxis G, Karabelas T. Benign tumours of the small intestine: preoperative evaluation with a barium infusion technique. Eur J Radiol. 1993; 16:115-25.
 7. Ameh EA, Shehu SM, Rafindadi AH and Nmadu PT. Small intestine leiomyoma in Childhood: A case report. WAJM 2002; 21:157-158.
 8. Dass B, Dalal A, Sharma U, Garg P. Leiomyoblastoma of the small intestine. Indian J Pediatr. 1998; 68(6): 916-918.
 9. Iwatt AR, Khalil M, Attah EB. Gastric epithelioid leiomyoma presenting with spontaneous haemoperitoneum. Central African Journal of Medicine. 1990; 36:200-202.
 10. Essiet A, Kaunda I, Jibrin P, Nkposong EO. Bizarre presentations of leiomyoblastoma of the stomach: A report of two cases, Nigeria Journal of Clinical Practice 2004; 7: 99-101.
 11. Morgan BK, Crompton C, Talbert M, Gallagher WJ, Wood WC. Benign smooth muscle tumours of the gastrointestinal tract. A 24-year experience. Ann Surg. 1990; 211:63-6.
 12. Stothert JC, Riaz A, Joyce PF, Kaminski DL. Preoperative angiographic diagnosis of small bowel leiomyomas. Arch Surg 1978; 113:643-645.
 13. Freeman J. Leiomyoma of the small bowel: a case report. J Paediatr surg. 1979; 14:477-478.
 14. Demirbas A, Kaynaroglu ZV, Daphan C, Sayek I. Leiomyomas of the small bowel: a rare cause of massive and recurrent gastrointestinal bleeding. Case report. Hepatogastroenterology 1994;41:589-90.
 15. Cho KJ, Reuter SR. Angiography of duodenal leiomyomas and leiomyosarcomas. Am J Radiol 1980; 135:31-35.

Author Information

H.A. Nggada, FMCPATH, FICS

Department Of Histopathology, University Of Maiduguri Teaching Hospital

T.A. Bashir, FWACS

Department Of Surgery, University Of Maiduguri Teaching Hospital

A.G. Ibrahim, FWACS

Department Of Surgery, University Of Maiduguri Teaching Hospital

King D. T. Yawe, FWACS, FICS

Department Of Surgery, University Of Maiduguri Teaching Hospital

M.I.A. Khalil, MD, PhD, FICS

Department Of Histopathology, University Of Maiduguri Teaching Hospital