

The Characteristic Extrasellar Extension In Growth Hormone Secreting Macroadenoma ... What And Why?

H Ibrahim, A M El-sayed

Citation

H Ibrahim, A M El-sayed. *The Characteristic Extrasellar Extension In Growth Hormone Secreting Macroadenoma ... What And Why?*. The Internet Journal of Neurosurgery. 2019 Volume 15 Number 1.

DOI: [10.5580/IJNS.54116](https://doi.org/10.5580/IJNS.54116)

Abstract

Object. A trial to identify and interpretate the characteristic extraseller extension in growth hormone secreting macroadenoma in acromegalic patients.

Patients and Methods. This is a retrospective review of Forty-three acromegalic patients of histopathologically proven growth hormone secreting macroadenoma were evaluated based on MR and CT images to identify the characteristic extraseller extension and trial to interpretate causes of this extension in acromegalic patients who underwent transsphenoidal surgery.

Results. This study consisted of the 43 patients with histopathologically proven GH-secreting macroadenomas, 27 males (63%) and 16 females (37%) with male to female ratio of 1.6:1 and age ranged from 28-61 years with a mean of 44.5 years. Based on MR images, overall extraseller extensions were noted into the following regions: infrasellar, 31 patients (72%); suprasellar, 7 patients (16%); cavernous sinus, 5 patients (12%). In acromegalic patients, the GH-secreting macroadenomas had significantly higher rates of infrasellar versus suprasellar extension (72% vs 16%, respectively) and significantly higher rates of infrasellar versus parasellar extension into the cavernous sinus (72% vs 12%, respectively). Based on CT images, the sphenoid sinus pneumatization was sellar type in 39 patients (91%) and presellar in 4 patients (9%). The width of the sphenoid sinus on axial CT images was ranged from 22.7-53.6mm with a mean 34.2mm and the anteroposterior diameter of the sphenoid sinus on mid sagittal CT reformatted images was ranged from 32.8-67.3mm with a mean 51.0mm and the presellar craniocaudal diameter of the sphenoid sinus on mid sagittal CT reformatted images was ranged from 15.7-49.3mm with a mean 35.3mm. Roomy sphenoid sinus was noted in 37 patients (86%) by increasing in width, anteroposterior and craniocaudal diameters. The most common pattern of inter-sphenoid septum was single septum which was present in 29 patients (67%). Double inter-sphenoid septa were present in 8 patients (19%) and no inter-sphenoid septum in 6 (14%) patients and diverging septa were present in 30 patients (81%). The sellar floor was normal in 3 patients (7%) and eroded and rarified (egg shell sellar floor) that documented also intraoperatively in 34 patients (79%) and no floor in 6 patients (14%).

Conclusion. The growth hormone secreting pituitary macroadenomas in acromegalic patients has a characteristic infrasellar extension due to multiple causes. acromegalic patients with growth hormone secreting pituitary macroadenomas associated with increased the sellar type pneumatization of the sphenoid sinus and finally increased incidence of roomy sphenoid sinus, all these are of important implications in transsphenoidal surgery in acromegalic patients.

INTRODUCTION

Growth hormone (GH)-secreting pituitary adenomas account for 20% of pituitary adenomas and causing acromegaly in > 99% of patients, whereas the remaining causes of acromegaly are non-pituitary tumors secreting GH or growth hormone releasing hormone [1, 2].

Excessive production of GH and insulin-like growth factor-I (IGF-I) lead to the clinical characteristics of acromegaly which are related pathologically to skeletal, soft tissue, and

organ overgrowth that leads to dysmorphic craniofacial features, musculoskeletal deformity, and cardiovascular, metabolic, and respiratory complications [3, 4, 5].

Transsphenoidal surgery is a cornerstone in the management of acromegaly, but medical therapy and radiotherapy has an increasingly important role, especially for those patients who are not in remission after surgery or for whom surgery is contraindicated [6].

The majority of the patients with GH-secreting tumors present with large (diameter > 1cm) and invasive tumors that may cause extension into one or more of extrasellar compartments [4, 7].

A detailed preoperative knowledge of tumor extension and relevant surgical anatomy of sphenoid sinus and its anatomical variations by means of neuroimaging is of vital importance and a necessary requisite to transsphenoidal surgery in treatment of acromegalic patients due to growth hormone secreting pituitary macroadenomas [8, 9].

The aim of the current study was to assess whether a growth hormone secreting macroadenoma exhibited preferential characteristic extrasellar extension of tumor growth and a trial to interpretate the causes predisposing this extrasellar extension in acromegalic patients.

PATIENTS AND METHODS

This a retrospective review of 43 cases of histopathologically proven growth hormone secreting macroadenoma to identify the characteristic extrasellar extension and a trial to interpretate causes of this extension in acromegalic patients who underwent transsphenoidal surgery performed in a period of 3 years between January 2013 and December 2015 in Ain Shams University Hospitals and Health Insurance Hospitals. Neuroimaging were reviewed from a computerized data-base of tumor research registry in both hospitals for which patients provided informed consent.

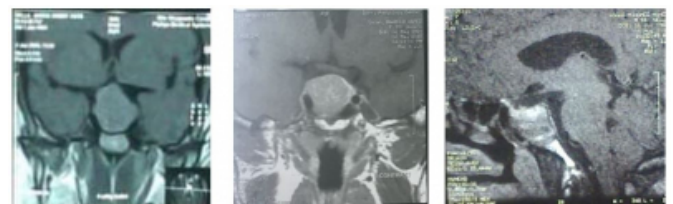
Preoperative magnetic resonance (MR) and computed tomography (CT) images were reviewed to assess for the pattern of tumor extension, and anatomy of the sphenoid sinus. Based on standard preoperative MR and CT imaging performed with and without contrast administration, a macroadenoma was defined as a tumor with a maximal diameter of greater than or equal to 10 mm, Invasion of the cavernous sinuses was defined as extension beyond the line corresponding to the lateral tangents of the 2 components of the intracavernous internal carotid artery, as defined by Knosp et al [10]. Suprasellar invasion was defined as clear tumor growth through the diaphragma sella or above the plane of the inferior optic chiasm. Finally, infrasellar invasion was determined by clear tumor growth through the sellar floor and into the sphenoid sinus.

Based on preoperative CT images, the anatomy of sphenoid sinus was analyzed according to its type of pneumatization

either seller or preseller, roomy sinus or not by increasing in width (which is the distance measured from the lateral side to the lateral side on axial images), anteroposterior (which is the anteroposterior distance of sphenoid sinus below the sella on mid sagittal images) and craniocaudal (which is the presellar height distance measured from floor of sinus up to superior extent of sinus in front of anterior sellar wall on mid sagittal images) diameters and seller floor rarefaction (egg shell seller floor) or not that documented also intraoperatively.

Figure 1

Infrasellar extension of pituitary adenoma in acromegalic patients.



RESULTS

This study consisted of 43 patients with histopathologically proven GH-secreting macroadenomas, 27 males (63%) and 16 females (37%) with male to female ratio of 1.6:1 and age ranged from 28-61 years with a mean of 44.5 years. Based on MR images, overall extrasellar extension was noted into the following regions: infrasellar, 31 patients (72%); suprasellar, 7 patients (16%); cavernous sinus, 5 patients (12%). In acromegalic patients, the GH-secreting macroadenomas had significantly higher rates of infrasellar versus suprasellar extension (72% vs 16%, respectively) and significantly higher rates of infrasellar versus parasellar extension into the cavernous sinus (72% vs 12%, respectively).

Based on CT images, the sphenoid sinus pneumatization was sellar type in 39 patients (91%) and presellar in 4 patients (9%). The width of the sphenoid sinus on axial CT images was ranged from 22.7-53.6mm with a mean 34.2mm and the anteroposterior diameter of the sphenoid sinus on mid sagittal CT reformatted images was ranged from 32.8-67.3mm with a mean 51.0mm and the presellar craniocaudal diameter of the sphenoid sinus on mid sagittal CT reformatted images was ranged from 15.7-49.3mm with a mean 35.3mm. Roomy sphenoid sinus was noted in 37 patients (86%) by increasing in width, anteroposterior and craniocaudal diameters. The most common pattern of intersphenoid septum was single septum which was present in 29

patients (67%). Double inter-sphenoid septa were present in 8 patients (19%) and no inter-sphenoid septum in 6 (14%) patients and diverging septa were present in 30 patients (81%).

The sellar floor was normal in 3 patients (7%) and eroded and rarified (egg shell sellar floor) that documented also intraoperatively in 34 patients (79%) and no floor in 6 patients (14%).

Figure 2
Pie chart of sex distribution.

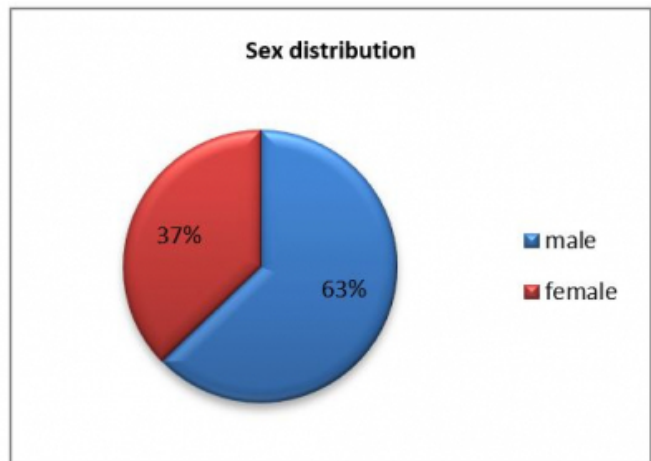


Figure 3
Pie chart of extrasellar extension of adenoma.

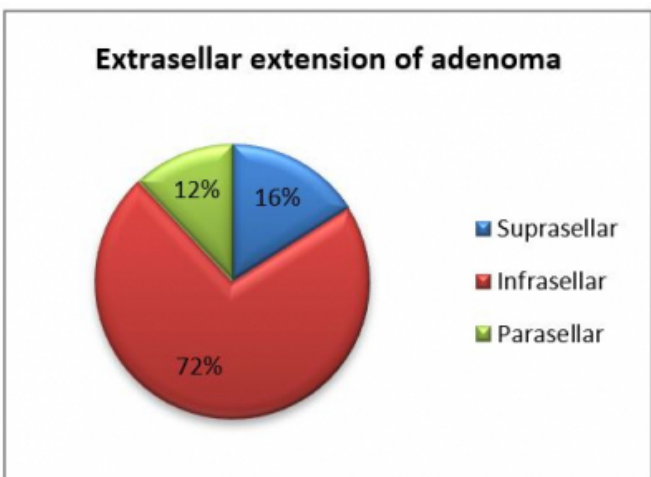


Figure 4
Pie chart of sphenoid sinus pneumatization.

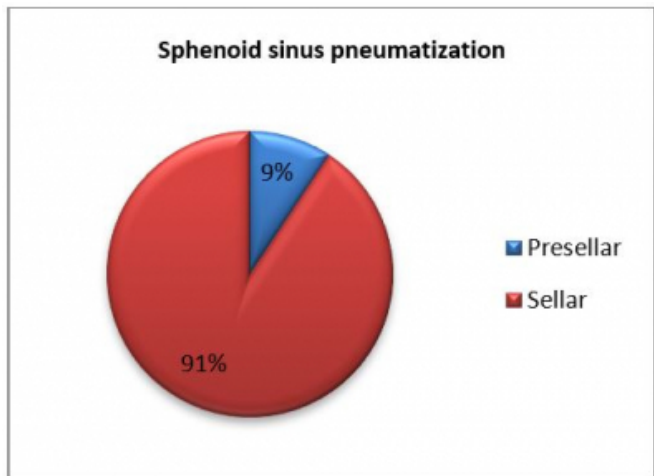


Figure 5
Pie chart of the sellar floor.

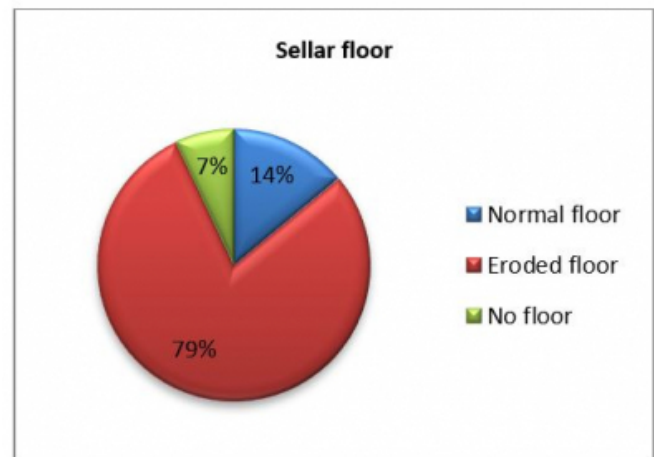
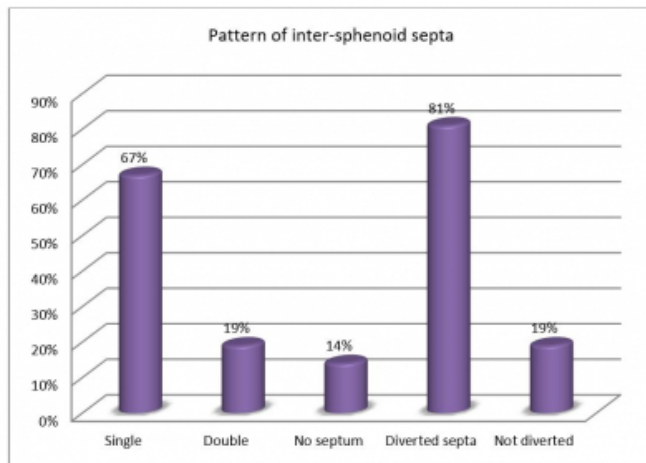


Figure 6

Bar chart of pattern of inter-sphenoid septa.



DISCUSSION

Extrasellar extension of pituitary macroadenomas into the surrounding supra-, para-, or infrasellar compartments is noted in over 90% of resected macroadenomas [11].

A detailed assessment of the pattern of extrasellar extension on preoperative MR images is mandatory prior to attempting transsphenoidal resection of pituitary adenomas, to define which regions pose the greatest limitation for tumor resection and are likely to retain residual tumor that may cause subsequent disease progression or serve as targets for postoperative radiation [12].

In this study, we noticed in all acromegalic patients that the GH-secreting macroadenomas demonstrated a preferential extension into the infrasellar region (72%) versus suprasellar extension (16%) and parasellar extension into the cavernous sinus (12%) respectively.

Zada et al, compared the patterns of extrasellar extension of GH secreting and nonfunctioning macroadenomas in 75 patients undergoing transsphenoidal operations and reported that of the 25 patients with GH-secreting macroadenomas, the overall extension was noted into the following regions: infrasellar, 18 patients (72%); suprasellar, 4 patients (16%); cavernous sinus, 4 patients (16%); and no extension (infrasellar macroadenoma), 6 patients (24%). Also they noted that of the 50 patients with nonfunctioning macroadenomas, the overall extension was noted into the following regions: infrasellar, 23 patients (46%); suprasellar, 41 patients (82%); cavernous sinus, 20 patients (40%); and no extension, 3 patients (6%). When they compared the overall infrasellar extension and isolated infrasellar

extension in both groups, they noted that GH-secreting macroadenomas had significantly higher rates of infrasellar extension (72% vs 46%, respectively; $p < 0.05$) and Patients with GH-secreting macroadenomas were over 8 times more likely to have isolated infrasellar extension than were patients with nonfunctional macroadenomas (52% vs 6%, respectively; $p < 0.0001$). So they concluded GH macroadenomas demonstrated a proclivity for infrasellar extension [12].

Our result regarding the infrasellar growth of the GH-secreting macroadenomas correlated well with Baik et al, who reported that macro-GH adenomas in inferior direction and Hagiwara et al, who reported that GH-producing adenomas tended to demonstrate infrasellar extension rather than suprasellar extension [13, 14].

In this study, we found that the majority of GH-producing macroadenomas in 34 patients (79%) exhibiting eroded and rarified sellar floor (egg shell sellar floor) that documented also intraoperatively and no floor in 6 patients (14%) and the sellar floor was normal in 3 patients (7%). Our result correlated well with study of Gondim et al, who reported that most cases of GH-producing adenomas in acromegalic patients were associated with sellar floor erosion as follows: 10 lesions (14.9%) were with no floor destruction, 45 (67.1%) with minimal floor destruction with no sphenoid sinus invasion, 7 (10.4%) minimal sphenoid sinus invasion and 5 (7.5%) cases diffuse destruction of the sellar floor with sphenoid sinus invasion [9].

In our study based on CT images, the sphenoid sinus pneumatization was sellar type in 39 patients (91%) and presellar in 4 patients (9%). In the study of Carrabba et al, the sphenoid sinus pneumatization was of the presellar or conchal type in 6 out of 23 patients (26%) and sellar type in the remaining 17 patients (74%) with acromegaly and GH producing pituitary adenomas were submitted to transsphenoidal surgery for removal of the pituitary adenoma by the authors [8].

The current study demonstrated that the sphenoid sinus was roomy and this noted in 37 patients (86%) by increasing in width, anteroposterior and craniocaudal diameters in acromegalic patients due to GH secreting pituitary macroadenomas. Our result confirmed well with the studies performed by Carrabba et al and Ebner et al [8, 15].

In our study, we noted that the most common pattern of inter-sphenoid septum was single septum which was present

in 29 patients (67%), double inter-sphenoid septa were present in 8 patients (19%) and no inter-sphenoid septum in 6 (14%) patients and the diverted septa were present in 30 patients (81%). Regarding the inter-sphenoid septations, our result was different from that reported by Carrabba et al, as they reported that acromegalics had a significantly higher number of intrasphenoid septa [8].

Based on the previous discussed points and the results of our study, it was demonstrated that the characteristic extrasellar extension in growth hormone secreting macroadenoma of acromegalic patients was the infrasellar extension and this confirmed by Hagiwara et al, Zada et al and Baik et al [12, 13, 14].

The second question we need to know why growth hormone secreting macroadenoma of acromegalic patients prefer the infrasellar extension. Some authors have suggested three possible explanations of why GH-producing adenomas tend to extend in an infrasellar direction. The first is that since GH thickens soft tissue, the diaphragm of sella may be thickened or hardened, therefore favoring extension in the infrasellar direction. A second possible explanation is that GH decreases the bone density, thus making the sellar floor thinner, so the sellar floor is easily eroded by the tumor. A third possible explanation is that GH itself, and not merely the tumor growth, enlarges the sella [14].

Based on our study, we need to add possible interpretations for this phenomenon. As in acromegalic patients there is a craniofacial disproportion, increased thickness of brain tissue, increased incidence of sellar type pneumatization of the sphenoid sinus and finally increased incidence of roomy sphenoid sinus, all these factors help in inferior direction of the growth hormone secreting pituitary macroadenomas.

Our study has a few limitations; the number of acromegalic patients with growth hormone secreting pituitary macroadenomas was relatively small due to the incidence is low and the period of study is not large enough to include a large number of patients so a further study may be necessary with an increased number of acromegalic patients with growth hormone secreting pituitary macroadenomas to increase the statistical power.

CONCLUSIONS

The growth hormone secreting pituitary macroadenomas in acromegalic patients has a characteristic infrasellar extension due to multiple causes. acromegalic patients with growth

hormone secreting pituitary macroadenomas associated with increased the sellar type pneumatization of the sphenoid sinus and finally increased incidence of roomy sphenoid sinus, all these are of important implications in transphenoidal surgery in acromegalic patients.

References

1. Horvath E, Sheithauer BW, Kovacs K, Lloyd RV. Pituitary adenomas. In: Graham DI, Lantos PL, eds. Greenfield's neuropathology. 6th ed. New York, NY: Oxford University Press, 1054-1076, 1997.
2. Thorner MO, Frohman LA, Leong DA, Thominet J, Downs T, Hellmann P, Chitwood J, Vaughan JM, Vale W. Extrahypothalamic growth-hormone-releasing factor (GRF) secretion is a rare cause of acromegaly: Plasma GRF levels in 177 acromegalic patients. J Clin Endocrinol Metab 59: 846-849, 1984.
3. Jagannathan J, Smith R, DeVroom HL, Vortmeyer AO, Stratakis CA, Nieman LK, et al. Outcome of using the histological pseudocapsule as a surgical capsule in Cushing disease. J Neurosurg 116:721-727, 2012.
4. Melmed S. Acromegaly pathogenesis and treatment. J Clin Invest 119:3189-3202, 2009.
5. Yildirim AE, Sahinoglu M, Divanlioglu d, Alagoz F, Gurcay AG, Daglioglu E, Okay HO and Belen AD: Endoscopic Endonasal Transsphenoidal Treatment for Acromegaly: 2010 Consensus Criteria for Remission and Predictors of Outcomes. Turk Neurosurg Vol: 24, No: 6, 906-912, 2014.
6. Melmed S, Jackson I, Kleinberg D, Klibanski A: Current treatment guidelines for acromegaly. J Clin Endocrinol Metab 83(8):2646-2652, 1998.
7. Lodish MB, Trivellin G, Stratakis CA. Pituitary gigantism: Update on molecular biology and management. Curr Opin Endocrinol Diabetes Obes 23: 72-80, 2016.
8. Carrabba G, Locatelli M, Mattei L, Guastella C, Mantovani G, Rampini P and Gaini SM: Transphenoidal surgery in acromegalic patients: anatomical considerations and potential pitfalls. Acta Neurochir 155:125-130, 2013.
9. Gondim J, Almeida JP, Albuquerque L.A.F, Gomes E, Schops M, and Ferraz T: Pure endoscopic transsphenoidal surgery for treatment of acromegaly: results of 67 cases treated in a pituitary center. Neurosurg Focus 29 (4):E7, 2010.
10. Knosp E, Steiner E, Kitz K, Matula C: Pituitary adenomas with invasion of the cavernous sinus space: a magnetic resonance imaging classification compared with surgical findings. Neurosurgery 33:610-618, 1993.
11. Zada G, Kelly DF, Cohan P, Wang C, Swerdloff R: Endonasal transsphenoidal approach for pituitary adenomas and other sellar lesions: an assessment of efficacy, safety, and patient impressions. J Neurosurg 98:350-358, 2003.
12. Zada G, Lin N, and Laws E.R: Patterns of extrasellar extension in growth hormone-secreting and nonfunctional pituitary macroadenomas. Neurosurg Focus 29 (4):E4, 2010.
13. Baik JS, Lee MH, Ahn KJ, Choi HS, Jung SL, Kim BS, Jeun SS and Hong YK: Characteristic location and growth patterns of functioning pituitary adenomas: correlation with histologic distribution of hormone-secreting cells in the pituitary gland. Journal of Clinical Imaging, 2015.
14. Hagiwara A, Inoue Y, Wakasa K, Haba T, Tashiro T, Miyamoto T: Comparison of growth hormone-producing and non growth hormone producing pituitary adenomas: imaging characteristics and pathologic correlation. Radiology 228: 533-538, 2003.

15. Ebner FH, Kürschner V, Dietz K, Bültmann E, Nägele T, and Honegger J: Craniometric changes in patients with acromegaly from a surgical perspective. *Neurosurg Focus* 29 (4):E3, 2010.

Author Information

Hamdy Ibrahim

Ain Shams University, Neurological Surgery Department
Cairo, Egypt

Ahmed M. El-sayed

Ain Shams University, Neurological Surgery Department
Cairo, Egypt