

# Injectable Poly-L-Lactic Acid (PLLA): Practical Approaches to Optimize Outcomes

U Bauer

---

## Citation

U Bauer. *Injectable Poly-L-Lactic Acid (PLLA): Practical Approaches to Optimize Outcomes*. The Internet Journal of Plastic Surgery. 2009 Volume 7 Number 1.

## Abstract

The use of injectable devices for soft-tissue augmentation has been associated with the occurrence of adverse events. The present case report discusses the successful treatment and resolution of painful nodules that were histologically shown to be foreign body granulomas in a patient who had previously received injectable poly-L-lactic acid for the correction of nasolabial folds, the neck, and zygomatic area. Incorrect injection placement and method may have led to the formation of granulomatous nodules. Properly trained professionals can minimize or avoid the occurrence of many of these types of adverse events for their patients by employing proper reconstitution and injection techniques and injecting appropriate/indicated areas. If granulomas do occur, full resolution may be expected following a course of triamcinolone injections.

## INTRODUCTION

Injectable poly-L-lactic acid (injectable PLLA; Sculptra and Sculptra Aesthetic, Dermik Laboratories, Bridgewater, NJ, a business of sanofi-aventis U.S. LLC) is a biocompatible, biodegradable polymeric device. In the United States, injectable PLLA is approved for use in immune-competent people as a single regimen for the correction of shallow to deep nasolabial fold contour deficiencies and other facial wrinkles in which deep dermal grid pattern injection technique is appropriate.<sup>1</sup> Injectable PLLA is also approved in the United States for the restoration and/or correction of the signs of facial fat loss (lipoatrophy) in people with human immunodeficiency virus (HIV).<sup>2</sup> Injectable PLLA has been shown to have a sustained duration of effect for up to 25 months in immune-competent people<sup>3</sup> and for up to 24 months in patients with HIV-associated facial lipoatrophy.<sup>4-9</sup>

The use of injectable devices for soft-tissue augmentation can be associated with injection- or product-related adverse events. This report describes an approach to optimizing treatment in a patient who received injectable PLLA for aesthetic correction and developed painful subcutaneous nodules. Improper injection technique/placement may have contributed to the occurrence of this adverse effect.

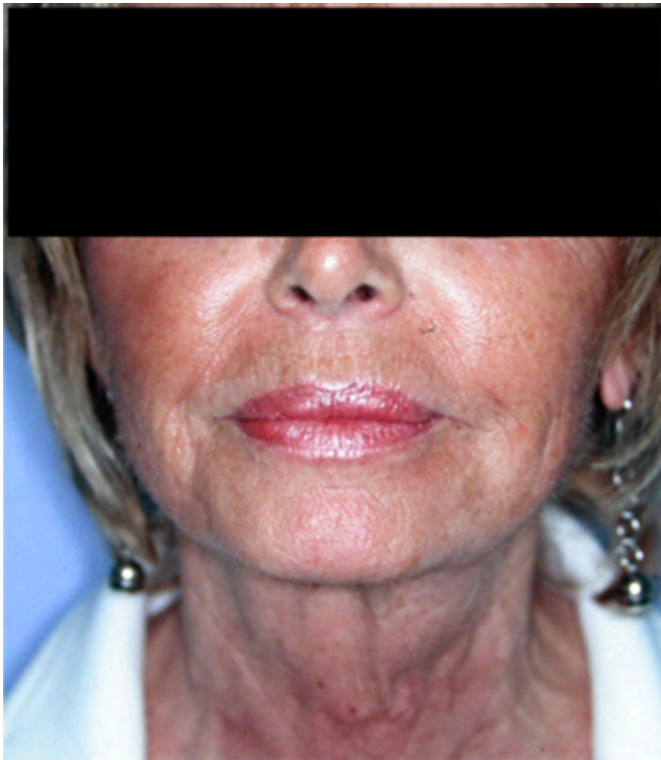
## CASE REPORT

In October 2004, a 52-year-old woman presented with painful subcutaneous nodules. Medical history revealed that

she had received aesthetic treatment with injectable PLLA from 2 different physicians; posttreatment visits had been completed in December 2003. The patient had received a total of 3 treatment sessions at 8-week intervals; areas treated included the nasolabial folds, neck, and zygomatic area. The dilution volume used for the first injection was 4 mL of sterile water; the second and third injections were administered using a 6-mL dilution. Further details of injection technique were not available from the treating physicians. The patient reported that a favorable aesthetic result had been achieved 6 weeks after treatment with injectable PLLA (Figure 1).

**Figure 1**

Figure 1 Photograph of the patient in December 2003, 6 weeks after receiving three injections of poly-L-lactic acid in the nasolabial fold, neck, and zygomatic area.

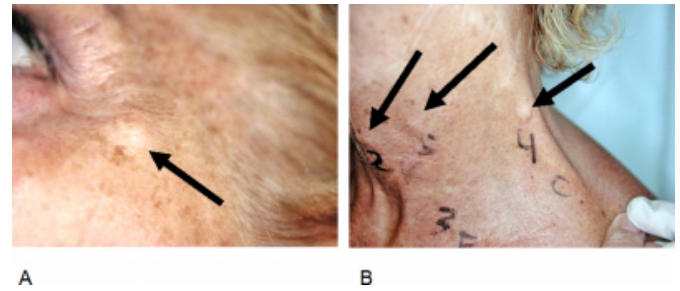


Laboratory test results (including complete blood count and T-lymphocyte, thyroid, and female hormone levels) were within normal limits; and no signs of inflammation or antibody reaction, and no viral diseases were identified. The patient reported a healthy lifestyle, with no history of smoking or alcohol use.

On presentation in October 2004, the subcutaneous nodules were localized in every injection site (Figure 2). Over 20 nodules were observed, ranging from pea- to bean-sized (approximately 5 to 10 mm), were hard and painful (except in the neck) on palpation, and appeared to be in the acute swelling period. The bean-sized nodules were located mostly in the zygomatic and periocular regions, but also in the neck. Nodules in the nasolabial fold appeared to be smaller (pea-sized).

**Figure 2**

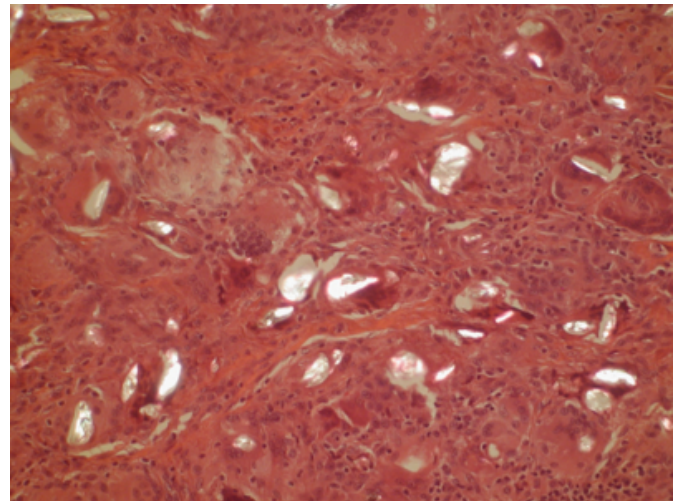
Figures 2A and 2B. Photographs of the patient in October 2004, showing subcutaneous nodules.



A 10-day treatment course with oral prednisone (1 mg once daily) and amoxicillin (1 g every 12 hours) was initiated. The pain, redness, and edema mostly resolved; however, hard, asymptomatic nodules of variable sizes remained in all treated areas. A nodule biopsy was therefore performed in a hidden area of the neck. Histological analysis revealed numerous translucent particles of irregular size and shape, birefringent under polarized light and surrounded by lymphocytes, macrophages, and giant cells (Figure 3).

**Figure 3**

Figure 3. Histology slide showing numerous translucent particles of irregular size and shape that were birefringent under polarized light and surrounded by lymphocytes, macrophages, and giant cells.



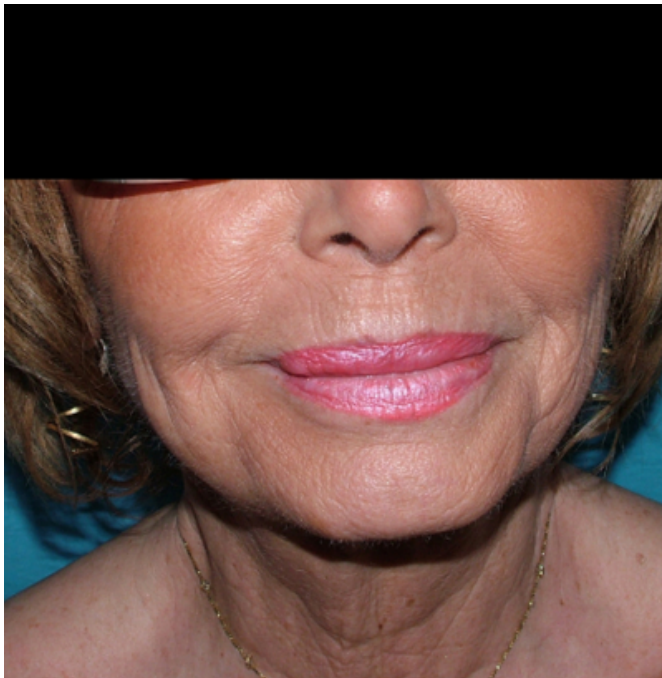
The diagnosis was foreign body granulomas, and intralesional treatment with undiluted triamcinolone 40 mg/mL was commenced. Care was taken to inject within these granulomas (approximately 0.05 mL of triamcinolone for smaller nodules and 0.1 mL for larger ones), avoiding tissue atrophy. After 2 weeks, a 50% reduction in granuloma size was observed. Triamcinolone injection at only the visible sites was repeated after 2 months; 2 weeks later, nodules were further reduced to become only detectable by

palpation (80% reduction from baseline).

During continued follow-up, the patient had periods of near remission and recurrence, particularly after exposure to extreme heat or cold. If remission occurred the foreign body granulomas remained palpable but were less visible. If a recurrence occurred the granulomas were the same size as on initial presentation. Two additional injections of undiluted triamcinolone 40 mg/mL were administered during a period of 6 months. Minor atrophy in the zygomatic area secondary to the corticosteroid injection was corrected with injections of hyaluronic acid. Complete recovery was documented at 2 years after onset of the granulomas, with no signs of atrophy. Figure 4 depicts the patient's visit 3.5 years after treatment for the nodules was initiated.

### Figure 4

Figure 4. Photograph of the patient 3.5 years after initiation of treatment for the nodules.



## DISCUSSION

This case documents the treatment and resolution of symptoms in a woman presenting with painful (except in the neck) subcutaneous nodules at all injection sites 10 months after receiving injectable PLLA. Subcutaneous papules at the injection site have been reported in clinical trials with injectable PLLA, but typically have been palpable, asymptomatic, and have fully resolved after treatment.<sup>4,6,7</sup>

Foreign body granuloma is a relatively rare complication reported with the use of various injectable products for

cosmetic procedures (ie, occurrence 0.01%-1.0%), including collagen, hyaluronic acid, injectable PLLA, calcium hydroxylapatite, hydroxyethyl methacrylate particles, polymethyl methacrylate microspheres, silicone gel, and polyacrylamide gel.<sup>10</sup> In my experience with more than 4000 injectable PLLA treatments in 10 years (since 1999), only 2 patients treated at my clinic have returned with foreign body granulomas; additional patients have been referred by other physicians. Occurrence is unpredictable, with reactions typically appearing simultaneously at all injection sites 6 or more months after treatment. Causes may include bolus injection, insufficient dilution (injected material is too concentrated), and injection in hyperdynamic areas. Lemperle et al have attributed these events to a sudden stimulation of macrophage memory rather than to an allergic reaction.<sup>10</sup> Intralesional injection of corticosteroids, such as triamcinolone, is recommended as the remedy, and was utilized in this case.

Many events associated with the use of injectable products for cosmetic procedures can be avoided or minimized with training in appropriate administration techniques and avoidance of the treatment of high-risk areas.<sup>11</sup> When using injectable PLLA, it is essential that the reconstitution volume and time are sufficient to ensure full product hydration. According to the package insert, injectable PLLA should be reconstituted with 5 mL of sterile water for injection, the vial should stand for at least 2 hours to ensure complete hydration, and any remaining volume should be discarded after 72 hours.<sup>2</sup> In my practice, I use volumes of at least 5 mL for aesthetic procedures. The deep dermis or subcutaneous layer should be injected; superficial injections should be avoided.<sup>2</sup> Experienced physicians, including myself, use injectable PLLA close to<sup>12,13</sup> or below the periosteal plane,<sup>14</sup> although this method is considered off-label and is not described within the package insert.<sup>1</sup> Massage during treatment helps distribute the product evenly. Physicians should instruct patients that massage of the treated area will be required for several days following the procedure. Review of proper massage techniques should also be demonstrated to the patient before and during the treatment session to optimize treatment outcomes. Data are insufficient to recommend use of injectable PLLA in the hands and periorbital areas—and especially in hyperdynamic areas such as the neck, which was reported in this patient—and such use is not recommended by the manufacturer. Moreover, injections should be given by a trained and experienced physician.

## CONCLUSION

The use of injectable PLLA can be optimized through proper injection technique and placement by a trained professional. Following treatment, patients should also be encouraged to massage treated area(s) to minimize the potential for granulomas and optimize treatment outcomes. If granulomas do occur, full recovery can be expected following a course of intralesional corticosteroid injections.

## References

1. Sculptra Aesthetic [prescribing information]. Bridgewater, NJ: Dermik Laboratories; a business of sanofi-aventis U.S. LLC; 2009.
2. Sculptra [prescribing information]. Bridgewater, NJ: Dermik Laboratories; a business of sanofi-aventis U.S. LLC; 2006.
3. Narins RS. A randomized study of the safety and efficacy of injectable poly-L-lactic acid versus human-based collagen implant in the treatment of nasolabial fold wrinkles. *J Am Acad Dermatol*. In press.
4. Mest DR, Humble G. Safety and efficacy of poly-L-lactic acid injections in persons with HIV-associated lipoatrophy: the US experience. *Dermatol Surg*. 2006;32(11):1336-1345.
5. Moyle GJ, Lysakova L, Brown S, et al. A randomized open-label study of immediate versus delayed poly(lactic acid injections for the cosmetic management of facial lipoatrophy in persons with HIV infection. *HIV Med*. 2004;5(2):82-87.
6. Moyle GJ, Brown S, Lysakova L, Barton SE. Long-term safety and efficacy of poly-L-lactic acid in the treatment of HIV-related facial lipoatrophy. *HIV Med*. 2006;7(3):181-185.
7. Valantin MA, Aubron-Olivier C, Ghosn J, et al. Poly(lactic acid implants (New-Fill) to correct facial lipoatrophy in HIV-infected patients: results of the open-label study VEGA. *AIDS*. 2003;17(17):2471-2477.
8. Woerle B, Hanke CW, Sattler G. Poly-L-lactic acid: a temporary filler for soft tissue augmentation. *J Drugs Dermatol*. 2004;3(4):385-389.
9. Burgess CM, Quiroga RM. Assessment of the safety and efficacy of poly-L-lactic acid for the treatment of HIV-associated facial lipoatrophy. *J Am Acad Dermatol*. 2005;52(2):233-239.
10. Lemperle G, Rullan PP, Gauthier-Hazan N. Avoiding and treating dermal filler complications. *Plast Reconstr Surg*. 2006;118(suppl 3):92S-107S.
11. Hanke CW, Redbord KP. Safety and efficacy of poly-L-lactic acid in HIV lipoatrophy and lipoatrophy of aging. *J Drugs Dermatol*. 2007;6(2):123-128.
12. Lam SM, Azizzadeh B, Graivier M. Injectable poly-L-lactic acid (Sculptra): technical considerations in soft-tissue contouring. *Plast Reconstr Surg*. 2006;118(suppl 3):55S-63S.
13. Beer K. Optimizing patient outcomes with collagenic stimulators. *J Drugs Dermatol*. 2007;6(suppl 1):S9-S12.
14. Vleggaar D. Facial volumetric correction with injectable poly-L-lactic acid. *Dermatol Surg*. 2005;31(11 Pt 2):1511-1517.

**Author Information**

**Ute Bauer, MD**

Chirurgia Plastica ed Estetica