

Laparoscopic Retrieval Of Oxidized Cellulose (Surgicel) Presenting As Gossypiboma

T Rao, C Johansson, P Lambrakis, R Sterling

Citation

T Rao, C Johansson, P Lambrakis, R Sterling. *Laparoscopic Retrieval Of Oxidized Cellulose (Surgicel) Presenting As Gossypiboma*. The Internet Journal of Gynecology and Obstetrics. 2020 Volume 24 Number 1.

DOI: [10.5580/IJGO.54219](https://doi.org/10.5580/IJGO.54219)

Abstract

The term "gossypiboma" or "textiloma" denotes a mass of cotton retained in the body after any intervention. Most of these foreign bodies are left behind unintentionally but we present a rare case where Surgicel used intentionally for haemostasis presented as acute abdomen requiring diagnostic laparoscopy and retrieval. The diagnosis is based on clinical examination, medical imaging, mainly X-ray and computerized tomography (CT).

Case report: A 15-year-old female underwent emergency exploratory laparotomy and right ovarian cystectomy for abdominal pain not relieved by analgesics. Surgicel was used to minimise ovarian bleeding at the index operation in otherwise uneventful surgery.

She presented 4 weeks post-operatively in the Emergency department with acute abdomen. A CT scan of her abdomen and pelvis revealed a "small intra-peritoneal haematoma" in the region of clinical tenderness. An incidental left adnexal fluid collection (presumed to be a cyst) was noted. A trans-abdominal pelvic ultrasound suggested small volume of free fluid within the pouch of Douglas.

Diagnostic laparoscopy was performed. Inflammatory adhesions to the right ovary associated with a Surgicel mass were found. The adhesions were divided and the Surgicel completely removed. The histopathological report confirmed it to be a "Gossypiboma" foreign body reaction with abundance of giant cell.

Discussion: It is believed that gossypiboma/textiloma is under-reported owing to its medico-legal implications, in addition to its asymptomatic nature at times. There are instances reported where failure to fully disclose to the patient when a gossypiboma is detected incidentally or at surgery however this practice is not advocated.

CT scans are considered the most specific for the detection of gossypiboma. Compared to other foreign bodies left behind unintentionally like retained gauze or surgical instruments, foreign body mediated reaction with Surgicel is typically mild making it difficult to identify. We believe that this was a type four hypersensitivity reaction and peritoneal histiolytic reaction.

Conclusion: A rare case where a foreign body (Surgicel) left intentionally in the body had to be retrieved surgically. Legal issues associated with foreign bodies (FDA approved Surgicel) needs to be debated.

INTRODUCTION

Inadvertent misplacement of foreign bodies within the human body during surgical procedures constitute a surgical misadventure and has serious clinical and legal ramifications. The term "gossypiboma" or "textiloma" denotes a mass of cotton retained in the body after any intervention. Most of these foreign bodies are left behind unintentionally but we present a rare case where Surgicel (Ethicon, US, LLC) used during a laparoscopic ovarian

cystectomy presented as acute abdomen requiring repeat laparoscopy and retrieval.

CASE REPORT

A 15-year-old female underwent an emergency exploratory laparoscopy and right ovarian cystectomy for a simple ovarian cyst. She presented with acute on chronic abdominal pain which was not relieved by oral analgesics, with a background of missing school due to chronic pain. Surgicel was used to minimise ovarian bleeding at the index

operation. The procedure was otherwise uneventful. The patient had persistent pain post-operatively with minimal improvement. She had high opioid requirements for > 1-week post operatively. Thorough clinical assessment and investigation revealed no organic pathology contributing to the pain.

A multidisciplinary approach comprising gynaecology team, paediatric team and acute pain service could not identify the exact cause of her significant post-operative pain. The possibility that behavioural and psychological components may be contributing to perception of pain were considered and discussed with the patient and her mother. The patient was discharged home on regular paracetamol, non-steroidal anti-inflammatory drugs and oxycodone.

Four weeks after the initial laparoscopy, the patient re-presented to our Emergency Department with a four day history of subjective fever and worsening lower abdominal pain. She described suprapubic and right lower quadrant pain without radiation. The pain was worse with movement and with passing urine. She denied any abnormal vaginal discharge. The patient was one week post her last menstrual period. She had a regular cycle, with menses duration of three days. There was no history of menorrhagia or dysmenorrhoea, and she had never been sexually active. Further history of the pain revealed that the patient had been significantly incapacitated by pain during the post-operative period despite compliance with the post-operative analgesic regimen. She had been “house-bound” due to the pain and had not been able to attend social activities or normal schooling.

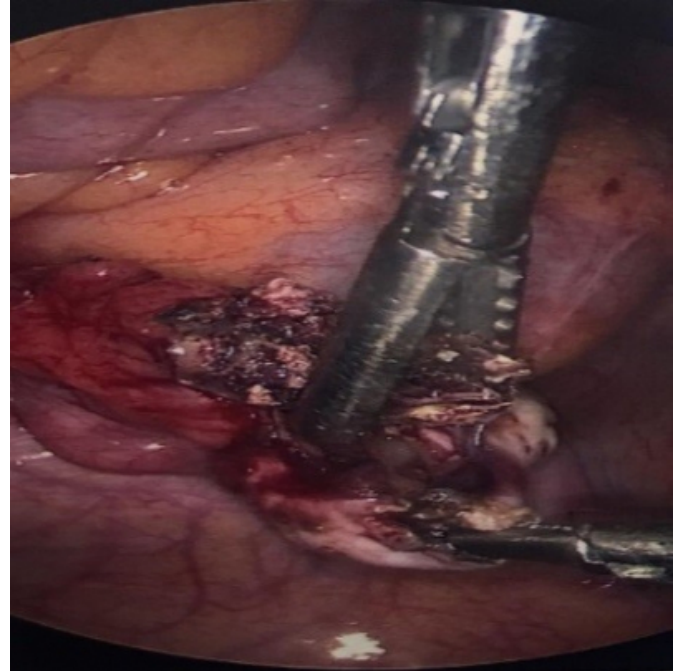
Investigations revealed a normal white cell count and C - reactive protein. A CT scan of her abdomen and pelvis revealed a “small intra-peritoneal haematoma”. An incidental left adnexal fluid collection (presumed to be a left ovarian cyst) was noted. There was no CT evidence of acute appendicitis. A trans-abdominal pelvic ultrasound suggested small volume of free fluid within the pouch of Douglas. The ultrasound was otherwise non-diagnostic.

After initial stabilization, analgesia and assessment, the patient was offered a diagnostic laparoscopy. At the time of the second laparoscopy, the only unusual finding noted was inflammatory adhesions to the right ovary, associated with a Surgicel mass. This operative finding corresponded to the area reported on CT scan as a haematoma. There was no pus or other sign of infection. The adhesions were divided and the Surgicel completely removed. Figure 1 reveals the

operative findings at laparoscopy with a surgical mass adherent to and within the right ovary.

Figure 1

Surgicel mass (gossypiboma) within right ovary (indicated by white arrow) – Laparoscopic extraction



Tissue cultures revealed no growth and histopathology revealed simple foreign body reaction with no other unusual findings (see Figures 2, 3 and 4).

Figure 2

Eosinophilic material

Haematoxylin and Eosin stain x 10

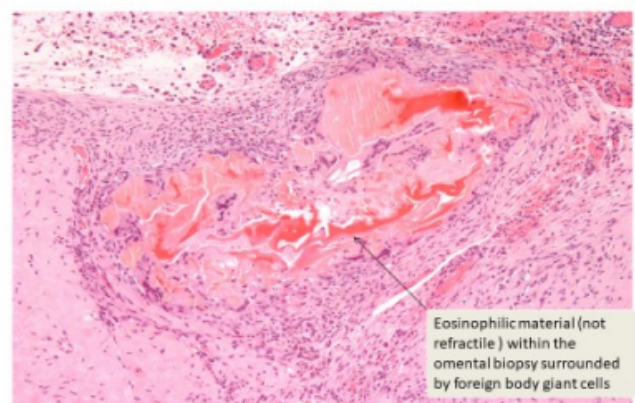


Figure 3

Foreign body giant cell

Haematoxylin and Eosin stain x 2.5

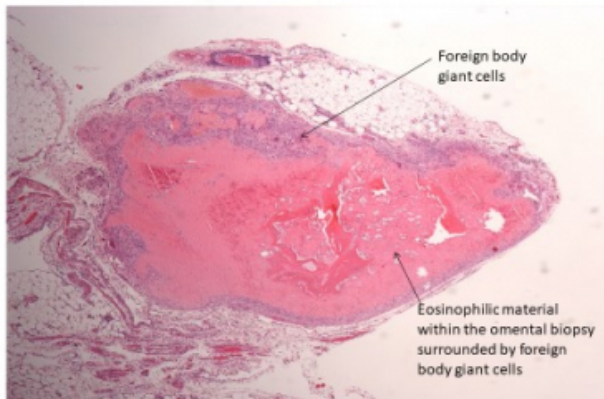
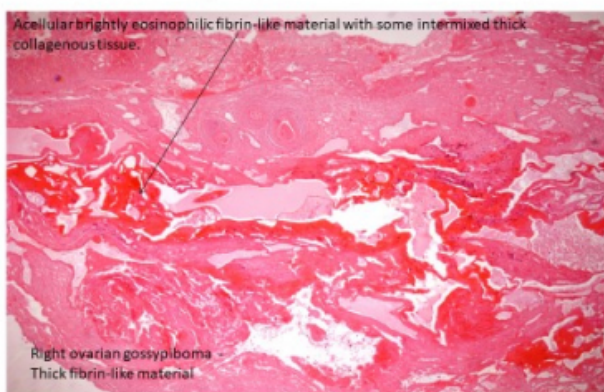


Figure 4

Right ovarian Gossypiboma

Haematoxylin and Eosin stain x 2.5



Although the patient had moderate pain scores during the first seven days after removing the surgical masks, she reported significant reduction in pain compared to the pre-operative period. She also reported that she experienced no pain and had no further analgesics requirement. Once discharged from hospital and had returned to normal social pursuits and schooling activities.

DISCUSSION

It is believed that gossypiboma/textiloma is under-reported owing to its medicolegal implications [1], in addition to its asymptomatic nature [2]. The exact incidence is largely unknown, and different estimates have been reported. Depending on the body's reaction, as well as the characteristics of the retained foreign body, the patient may

present acutely, within months of the original surgery, or may have a delayed presentation year thereafter.

We present a rare case where Surgicel (FDA approved agent) was left intentionally for haemostasis, though required surgical removal due to post-operative pain and symptoms related to a foreign body reaction, thereby behaving as a gossypiboma. Surgicel may be removed or left in situ depending on the clinical need. If left in situ, degradation is expected to commence within 24–48 hours and will be surrounded by inflammatory granulation tissue in a week's time.

Complete degradation will usually occur between 4 and 8 weeks. We believe this case was a Type Four Hypersensitivity reaction and peritoneal histiolytic reaction. A review of the literature pertaining to complications with the use of Surgicel are related to an excess use of the material. Surgicel has an uronic acid component that can increase inflammation of the surrounding tissue and delay healing of the injury. [3]

Complicated degradation reactions due to tissue damage can sometimes occur such as provisional matrix formation, acute or chronic inflammation, the appearance of granulation tissue, and creation of foreign body reactions leading to the formation of a fibrous capsule. Although an inflammatory response is expected, imaging to identify Surgicel complications can be challenging.[4]

CT scans are considered the most specific for the detection of gossypiboma. Typically, in the acute setting, gossypiboma appear as a heterogeneous mass containing large amount of trapped air, which may or may not be surrounded by a peripheral blade ring. In chronic gossypiboma, the CT findings may resemble a tumor that does not capture the intravenous contrast, with calcifications simulating a solid mass with entrapped gas bubbles that may persist over time. Compared to other foreign bodies left behind unintentionally at surgery (i.e. retained gauze or surgical instruments), the foreign body mediated reaction associated with Surgicel is typically mild, making it difficult to identify.

Treatment is based on surgical removal of the gossypiboma and resolution of associated complications. Open surgery is preferred by most surgeons because it generates adequate exposure and direct view of the anatomical site. However, due to the advent of laparoscopic surgery, many of these gossypibomas can be removed by this technique, which

offers the advantage of visual magnification as well as early recovery and reduce morbidity.

Gossypibomas have a serious medicolegal and psychological impact on the patient, the surgeon and the institution. The patient may be incorrectly diagnosed with a sarcoma or recurrent tumour and may undergo emotional distress secondary to this diagnosis, in addition to unnecessary staging procedures and surgical interventions. There are also surgical and anaesthetic risks associated with a second major operation, with death being a rare yet distinct possibility.

CONCLUSIONS

In conclusion, we present a rare case of a foreign body reaction to oxidized cellulose (Surgicel) in pelvic surgery [5], whereby the Surgicel mass behaved identically to a gossypiboma and required removal.[6] The correlation of symptoms, CT findings, operative findings and resolution of pain after removal of the Surgicel mass allowed the diagnosis of gossypiboma to be confirmed.

Our gynaecology unit continues to use Surgicel in small quantities (when indicated) during pelvic surgery, despite the complication of gossypiboma described in the presented

case. We feel the benefits of Surgicel outweigh its potential consequences. It remains important for surgeons and radiologists to be aware of possible complications associated with the use of Surgicel and its association with gossypiboma, despite its rare incidence.

References

1. Shyung LR, Chang WH, Lin SC, Shih SC, Kao CR, Chou SY. Report of gossypiboma from the standpoint in medicine and law. *World J Gastroenterol* 2005;11:1248-9.
2. Apter S, Hertz M, Rubinstein ZJ, Zissin R: Gossypiboma in the early post-operative period: a diagnostic problem. *Clin Radiol.* 1990, 42: 128-129.
3. K. Sekiba, The Obstetrics and Gynaecology Adhesion Prevention Committee Use of Interceed (TC7) absorbable adhesion barrier to reduce postoperative adhesion reformation in infertility and endometriosis surgery *Obstetrics and Gynecology*, 79 (1992), pp. 518-522
4. C. Alpaslan, G.H. Alpaslan, T. Oygur: Tissue reaction to three subcutaneously implanted local hemostatic agents *British Journal of Oral and Maxillofacial Surgery*, 35 (1997), pp. 129-132
5. E. Salmo, R. Bisset, I. Aldean: Oxidized cellulose mimicking a recurrent colorectal cancer: report of a case and review of the literature. *Colorectal Disease*, 12 (2010), pp. 380-386
6. A. Arnold, A. Sodickson: Postoperative Surgicel mimicking abscesses following cholecystectomy and liver biopsy. *Emergency Radiology*, 15 (2008), pp. 183-185

Author Information

Tanushree Rao

Department of Obstetrics & Gynaecology, Liverpool Hospital
Sydney, Australia

Cherryne Johansson

Department of Obstetrics & Gynaecology, Liverpool Hospital
Sydney, Australia

Paul Lambrakis

Department of Obstetrics & Gynaecology, Liverpool Hospital
Sydney, Australia

Ruth-Ann Sterling

Department of Obstetrics & Gynaecology, Liverpool Hospital
Sydney, Australia