

Depressed Skull Fracture In A Newborn Post Caesarean Section

T Rao, S Ahmed

Citation

T Rao, S Ahmed. *Depressed Skull Fracture In A Newborn Post Caesarean Section*. The Internet Journal of Gynecology and Obstetrics. 2020 Volume 24 Number 1.

DOI: [10.5580/IJGO.54258](https://doi.org/10.5580/IJGO.54258)

Abstract

DCF's (depressed skull fractures) are skull distortion similar to a 'ping pong ball' with incidence of 1/10 000 in western countries [1]. It can be spontaneous or traumatic. Over the last twenty years, 22 cases of "spontaneous" depressed skull fractures have been reported in the literature. We report a rare case of Spontaneous DCF in a new born following a straightforward caesarean section in a 33 year old female. Easy delivery of the head was carried out by a single blade of forceps. Depressed right parietal bone noticed immediately after birth. As a part of investigation the baby had X ray and CT brain. CT brain showed right parietal bone fracture with mass effect. There was a maximal depth of 6mm, with some disruption of the right side of the coronal suture by 1.5mm. No intracranial pathology was noted. Fetal blood samples for calcium and Vit D were within normal limits. In our case there was initially a doubt if a single blade of forceps could have been a contributory factor. But on further analysis it was concluded that as the baby was direct occipito posterior the placement of the blade would have been on the occiput rather than the parietal bone. Gold standard for DCF is CT brain with low dose protocol for infants. MRI can be done when CT shows doubtful or incidental intracranial findings. Prognosis of newborn depends on associated intracranial injury. Spontaneous fractures are rare and without further neurological consequences. Their prompt recognition in newborns is essential mainly to rule out intracranial haemorrhage and controlling clinically associated problems, such as seizures.

INTRODUCTION

DCF's (depressed skull fractures) are skull distortion similar to a 'ping pong ball' because of the cranial vault flexibility. It usually occurs in infants as the bone is malleable. Incidence of DCF is 1/10 000 in western countries¹. It can be spontaneous or traumatic. Spontaneous can occur in uneventful pregnancies and after uncomplicated vaginal or caesarean deliveries.

Fetal head pressure against the maternal bony structures can result in fracture. Trauma to the mother's abdomen and traumatic delivery are also accepted as pathological mechanisms for such lesions. The fetal head during the third trimester of pregnancy is completely protected by the surrounding bony structures. Therefore, it is unlikely that an impact, without maternal pelvic injuries, would be responsible for a fetal skull fracture. Other mechanisms related to the fetus itself include skull compression by a twin or pressure exerted by the digits and fists of the newborn on his skull.

We report a rare case of DCF in a new born who suffered

depressed parietal fracture following a caesarean section. No standard treatment is established for depressed skull fracture in neonates. Although there have been reports that with a minimally invasive technique, a good surgical outcome can be achieved with minimal blood loss and no bone loss.

CASE REPORT

A 33-year-old female, G3P1, with history of previous caesarean section for failure to progress presented to Liverpool Hospital, Sydney for her routine booking visit. She was unsure about her dates, hence EDD was based according to scan. Her antenatal bloods were unremarkable. She had an uneventful antenatal course apart from the fact that she developed gestational diabetes at 28 weeks. It was well controlled by diet. She has a growth ultrasound in the third trimester where the estimated fetal weight was on the 80%. After adequate counselling she opted for a repeat caesarean section and it was carried out at 39+3 weeks.

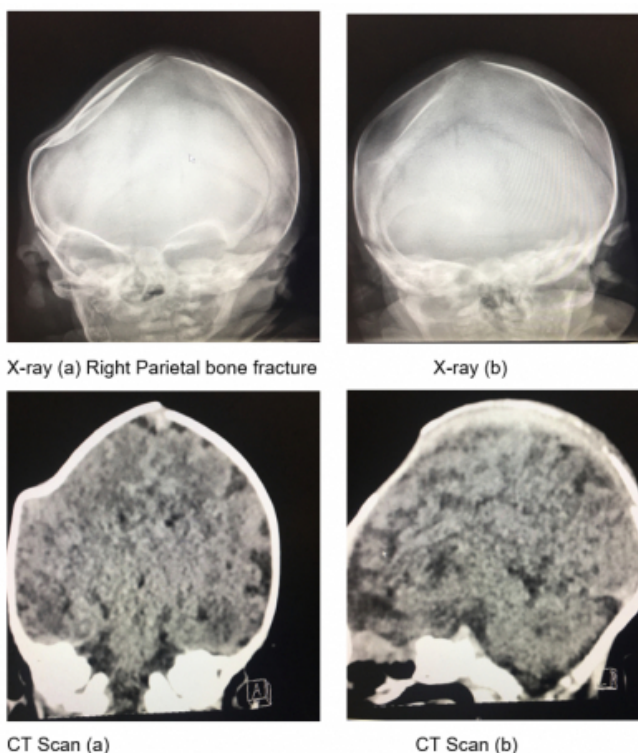
The caesarean section was fairly straightforward. Pfannenstiel's incision was used and the abdomen was opened in layers with sharp dissection. Curvilinear incision

was carried out on the lower uterine segment. The fetus was found to be in direct occipito-posterior position. Easy delivery of the head was carried out by a single blade of forceps. The baby cried immediately after birth. The abdomen was closed in layers.

The baby was born with APGAR score - 9,9 and birth weight of 3.7 kg. Depressed right parietal bone was noticed immediately after birth. The baby was admitted to NICU for 2 days for observation. The baby was alert, feeding well, with regular wet nappies and opening bowels. As a part of investigation, the baby had X ray and CT brain.

Figure 1 a to 1d

Xray and CT scan



CT brain showed right parietal bone fracture with mass effect. There was a maximal depth of 6mm, with some disruption of the right side of the coronal suture by 1.5mm. No intracranial pathology was noted. Fetal blood samples for calcium and Vit D were within normal limits. Follow up with neurosurgical Team at Children's Hospital Westmead in 2 weeks, 6 weeks and 10 weeks was arranged.

DISCUSSION

Although generally related to traumatic injuries, ping-pong fractures can also occur in uneventful pregnancies and after uncomplicated vaginal or caesarean deliveries. Over the last twenty years, 22 cases of "spontaneous" depressed skull

fractures have been reported in the literature². Probably, these "spontaneous" ping-pong fractures result from continual intrauterine mechanical stresses upon the fetal skull caused by bony structures, such as lumbar L5 vertebra, sacral promontory, pubic symphysis, ischial bone, or by an asymmetric or contracted pelvis, and/or uterine fibromas³.

Usually, these factors are unpredictable and not related to demographic or obstetric characteristics. In our case there was initially a doubt if a single blade of forceps could have been a contributory factor. But on further analysis it was concluded that as the baby was direct occipito-posterior the placement of the blade would have been on the occiput rather than the parietal bone.

Gold standard for DCF is CT brain with low dose protocol for infants. MRI can be done when CT shows doubtful or incidental intracranial findings. Prognosis of the newborn depends on associated intracranial injury. Treatment is based on extent of injury. Spontaneous resolution occurs in a few cases. Traditionally, neurosurgery was recommended which requires general anaesthesia, but it permits rapid, complete and effective resolution. There is a case report where the skull fracture was elevated by using an umber 4 Penfield dissector through parietal burr hole². Alternative treatment modality is use of breast milk extractor or vacuum extractor.⁴

Spontaneous fractures are rare and without further neurological consequences. Their prompt recognition in newborns is essential mainly to rule out intracranial haemorrhage and controlling clinically associated problems, such as seizures. In our case, the baby had an uneventful recovery with no neurological deficits. After adequate counselling regarding options available, the parents decided to await spontaneous resolution. As the scalp hair grows the defect becomes less visible as well.

In conclusion, although these fractures are rare and without further neurological consequences, their prompt recognition in newborns is essential to establish fast and adequate treatment, mainly related to controlling clinically associated problems, such as seizures.

References

1. Flannigan C, O'Neill C. Faulty fetal packing. BMJ Case Rep 2011;2011:pii: bcr0220113802doi:10.1136/bcr.02.2011.3802
2. Claudia Fantacci et al. Spontaneous ping pong fractures in new born. Signa Vitae 2015; 10 (1):103-109
3. Aliabadi H, Miller J, Radnakrishnan S, Mehta AI, Thomas K, Selznick L, et al. Spontaneous intrauterine "ping-pong"

fracture: review and case illustration. Neuropediatrics
2009;40:73-5
4. Mastrapa TL, Fernandez LA, Alvarez MD, Storrs BB,

Flores-Urueta A. Depressed skull fracture in Ping Pong:
elevation with Medeva extractor. Childs Nerve Syst
2007;23:787-90.

Author Information

Tanushree Rao, MBBS, MS, MRCOG

Dept. of Obstetrics and Gynaecology, Liverpool Hospital
Sydney, Australia

Shakil Ahmed, MBBS, FRCOG

Dept. of Obstetrics and Gynaecology, Liverpool Hospital
Sydney, Australia