

# Inferior Vena Cava Thrombosis Associated With Acute Pancreatitis: An Unusual Vascular Complication

S Sahu, R Verma, P Sachan, D Bahl

## Citation

S Sahu, R Verma, P Sachan, D Bahl. *Inferior Vena Cava Thrombosis Associated With Acute Pancreatitis: An Unusual Vascular Complication*. The Internet Journal of Surgery. 2006 Volume 13 Number 1.

## Abstract

A rare case of inferior vena cava (IVC) thrombosis secondary to acute pancreatitis is reported.

A 24-year-old male alcoholic presented with severe upper abdominal pain, hyperlipasaemia and swelling in both lower limbs. Radiological imaging showed an isolated inferior vena cava (IVC) thrombosis in the infrahepatic part of the IVC along with a bulky pancreas and ill-defined peripancreatic fat planes. Early treatment with heparin along with the standard management of acute pancreatitis was effective. Awareness of this complication will help in its early diagnosis and management.

## INTRODUCTION

Vascular thrombosis and systemic hypercoagulable states are known complications of pancreatitis.<sup>[1, 2, 3]</sup> We report a rare case of inferior vena cava (IVC) thrombosis associated with acute pancreatitis.

## CASE REPORT

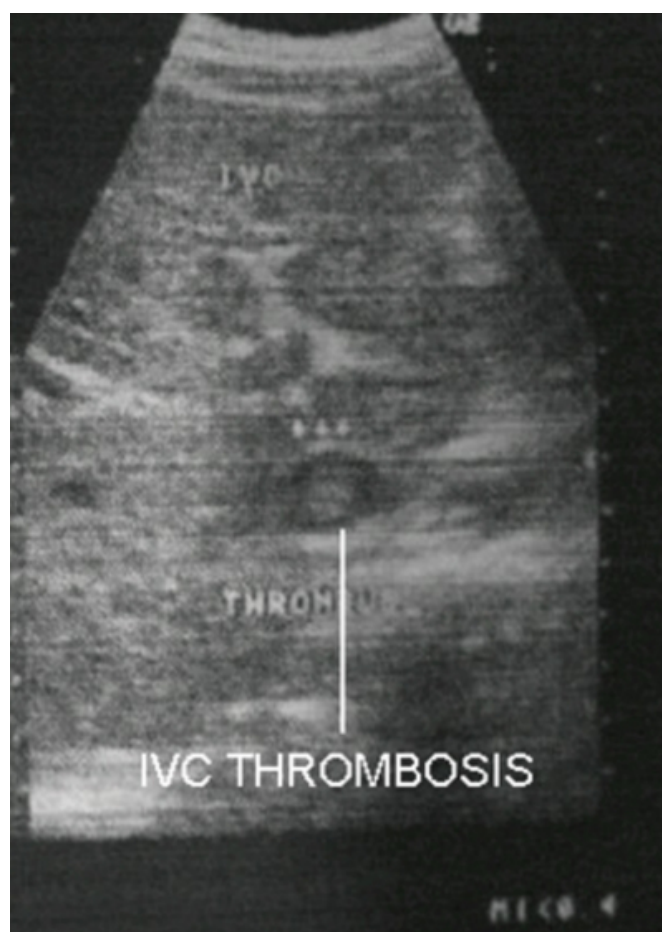
A 24-year-old male alcoholic presented with severe upper abdominal pain and vomiting since the last five days. He also noticed a progressive swelling of both legs since two days. General examination revealed a pitting edema in both legs. On examination of the abdomen, there was diffuse tenderness with absence of bowel sounds.

The relevant laboratory findings on admission were: hemoglobin 16.3g/dl, total leukocyte count 16400, random blood sugar 95 mg/dl, serum creatinine 0.8mg/dl, serum lipase 709 U/L, serum amylase 1416 IU/L and serum albumin 3.8g/dl. The activated partial thromboplastin time was 31 seconds and the prothrombin time was 20 seconds with an International Normalised Ratio (INR) of 1.2.

Ultrasonography of the abdomen showed a 26x12mm sized hyperechoic thrombus in the infrahepatic part of in the inferior vena cava (IVC) (Fig. 1). Abdominal computed tomography revealed a central non-enhancing area within the infrahepatic part of the inferior vena cava extending up to the level of the left renal vein opening, suggestive of a thrombus along with a bulky pancreas with an ill-defined peripancreatic fat plane. The portal vein was normal (Fig. 2).

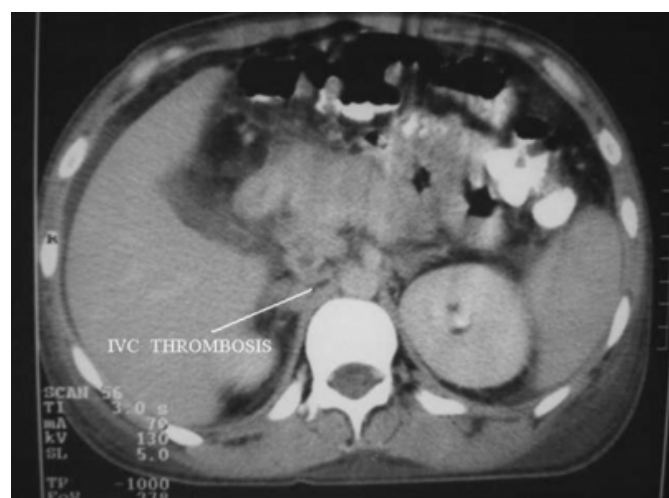**Figure 1**

Figure 1: sonogram of the abdomen showing a hyperechoic thrombus in the infrahepatic part of the inferior vena cava



## Figure 2

Figure 2: Abdominal Computed Tomography Showing An Inferior Vena Cava Thrombus Along With A Bulky Pancreas And Ill-Defined Peripancreatic Fat Planes.



The patient was managed conservatively with nil orally, nasogastric aspiration, intra-venous fluids, antibiotics and analgesics. Intravenous heparin was started at the dose of 5000 U 6-hourly with further dose adjustment maintaining an activated partial thromboplastin time between 50-80 seconds for five days.

The patient improved clinically with a reduction in the swelling of both legs.

## DISCUSSION

Isolated portal vein or combined superior mesenteric vein and portal vein thrombosis are known complications of acute pancreatitis. Isolated inferior vena cava (IVC) thrombosis is a very rare complication of acute pancreatitis, was first reported by Stringer<sup>[4]</sup> et al. in 1988 and there have been very few descriptions about it.<sup>[2,3,5,6,7]</sup>

The mechanism of formation of the IVC thrombus in acute pancreatitis<sup>[6, 7]</sup> is due to a cyst communicating with the pancreatic duct penetrating into the IVC.

Pancreatic juice entering the IVC and triggering the formation of athrombus secondary to vasculitis.

Inferior vena cava thromboses with renal vein thrombosis have also been reported with acute pancreatitis.<sup>[6]</sup>

Virtually all radiological modalities have been applied to the diagnosis of IVC thrombosis in acute pancreatitis. Contrast venography, ultrasonography, contrast-enhanced CT scan and MRI of the abdomen all have defined roles in the

diagnosis of IVC thrombosis.

Pulmonary thromboembolism is a dreadful complication of IVC thrombosis in acute pancreatitis, with the patient developing acute shortness of breath.<sup>[5,7]</sup>

Radionuclide <sup>99m</sup>Tc-venography and lung perfusion scintigraphy are useful in diagnosing pulmonary thromboembolism secondary to IVC thrombosis in pancreatitis, showing abnormal large hot spots at the level of the pancreas and pulmonary embolism.<sup>[7]</sup>

Early treatment with intravenous heparin is effective.<sup>[3]</sup> An IVC filter is sometimes used in the management of IVC thrombosis in acute pancreatitis to prevent pulmonary thromboembolism.<sup>[8]</sup>

This case report describes a rare complication of acute pancreatitis. Familiarity with this complication will aid in its early diagnosis and prevent pulmonary thromboembolism, a rare but catastrophic phenomenon.

## CORRESPONDENCE TO

Dr. Shantanu Kumar Sahu Assistant professor Department of General Surgery Himalayan Institute of Medical Sciences Swamiramnagar Dehradun Uttarakhand 248140 Email - Intshantanu@yahoo.co.in Mob. - 9412933868

## References

1. Nordback I, Sisto T. Peripancreatic vascular occlusion as a complication of pancreatitis. *Int J Surg* 1989; 74: 36-39.
2. Peillon C, Manouvrier JL, Testart J. Inferior vena cava thrombosis secondary to chronic pancreatitis with pseudocyst. *Am J Gastroenterol* 1991; 86: 1854-1856.
3. Antony SJ, Loomis T, Brumble L, Hannis MD. Inferior vena cava thrombosis associated with acute pancreatitis: an unusual vascular complication-its presentation and management. *Angiology* 1994; 45: 1009-1014.
4. Stringer MD, Michell M, McIrvine AJ. Inferior vena cava thrombosis complicating acute pancreatitis. Case report. *Acta Chir Scand* 1988; 154: 161-163.
5. Goenka MK, Kochhar R, Gulati M, Singh G, Khanna SK, Mehta SK. Acute pancreatitis complicated by pulmonary thromboembolism secondary to inferior vena cava thrombosis. *J Clin Gastroenterol.* 1994; 19: 85-6.
6. Ma SK, Kim SW, Kim NH, Choi KC. Renal vein and inferior vena cava thrombosis associated with acute pancreatitis *Nephron* 2002; 92: 475-7.
7. Ohta H, Hachiya T. A case of inferior vena cava thrombosis and pulmonary embolism secondary to acute exacerbation of chronic pancreatitis: A rare finding in radionuclide venography. *Annals of Nuclear Medicine* 2002; 16: 147-149.
8. Jones AL, Ojar D, Redhead D, Proudfoot AT. Case report: Use of an IVC filter in the management of IVC thrombosis occurring as a complication of acute pancreatitis. *Clin Radiol.* 1999; 54: 198.

**Author Information**

**Shantanu Kumar Sahu, MS (GENERAL SURGERY)**

Assistant Professor, Department of General Surgery, Himalayan Institute of Medical Sciences

**Ram Kumar Verma, MS (GENERAL SURGERY)**

Associate Professor, Department of General Surgery, Himalayan Institute of Medical Sciences

**Praveendra Kumar Sachan, MS (General Surgery)**

Professor, Department of General Surgery, Himalayan Institute of Medical Sciences

**Digvijay Bahl, MS (General Surgery), MCh (Cardiothoracic Surgery).**

Professor and Head, Department of General Surgery, Himalayan Institute of Medical Sciences