

Regression Of Megathrombocytes After Helicobacter Pylori Eradication: A Case Report

H Yamanaka, Y Fukui, T Hayakawa, K Miura, H Tamura, Y Matsukawa

Citation

H Yamanaka, Y Fukui, T Hayakawa, K Miura, H Tamura, Y Matsukawa. *Regression Of Megathrombocytes After Helicobacter Pylori Eradication: A Case Report*. The Internet Journal of Hematology. 2019 Volume 13 Number 1.

DOI: [10.5580/IJHE.54626](https://doi.org/10.5580/IJHE.54626)

Abstract

Background

Megathrombocytes are observed in patients with idiopathic thrombocytopenic purpura (ITP), which is well known to relate with Helicobacter pylori (H. pylori) infection. We report a unique patient who had megathrombocytes without thrombocytopenia and disappearance of megathrombocytes after H. pylori eradication.

Case Report

A 61-year-old man was diagnosed with H. pylori-induced atrophic gastritis after endoscopic evaluation. Blood tests revealed the presence of approximately 5% megathrombocytes. After successful eradication, the anti-H. pylori antibody titer decreased from 81.0 to 22.0 U/mL. Megathrombocytes became undetectable, and plateletcrit, mean platelet volume, and platelet distribution width decreased.

Conclusion

Why H. pylori eradication improves thrombocytopenia in some ITP patients remains unresolved. As in the current case, some ITP patients could have hindered megakaryocytic proliferation/differentiation induced by H. pylori, and such patients may respond well to eradication therapy.

INTRODUCTION

Megathrombocytes, or giant platelets, are young platelets recently released from the bone marrow and usually observed in patients with Bernard-Soulier syndrome, May-Hegglin anomaly, and idiopathic thrombocytopenic purpura (ITP) [1]. Apart from these hematologic disorders, patients with diabetic retinopathy and rheumatic diseases, as well as some after surgery, were also reported to show increases in megathrombocytes [1]. The appearance of megathrombocytes is associated with thrombocytopenia and the tendency to bleed [2].

Helicobacter pylori (H. pylori) is well-known to induce thrombocytopenia in ITP patients. Although the precise mechanism of this phenomenon is not fully understood, successful eradication of the bacterium results in remission and even cure of thrombocytopenia in ITP [3,4]. Antibodies against surface glycoproteins expressed on the

megakaryocyte lineages are presumed to participate in the pathoetiology of thrombocytopenia [5-8].

We present a unique case in which the regression of megathrombocytes was confirmed after H. pylori eradication.

CASE REPORT

A 61-year-old man visited Tsurumi University Hospital in July 2016. He had undergone a medical examination in May 2016, and the results suggested the presence of H. pylori infection. We rechecked the data for H. pylori infection on August 25, 2016, and the titer of anti-H. pylori IgG antibody was 81.0 U/mL (a titer greater than 10.0 is considered to indicate H. pylori infection). Values of pepsinogen I (PG I), PG II, and the PG I/PG II ratio were 51.6 ng/mL, 18.2 ng/mL, and 2.83, respectively, also indicating H. pylori infection (Table 1). The patient opted for H. pylori eradication therapy and, after undergoing a

gastrofiberscopic examination to confirm the diagnosis of *H. pylori*-induced atrophic gastritis according to the guidelines of the Ministry of Health, Labor, and Welfare of Japan, the triple-therapy regimen of amoxicillin, clarithromycin, and lansoprazole was initiated.

Before starting treatment, we also performed laboratory tests to evaluate the effects of *H. pylori* infection on hematologic, immunologic, and allergic parameters after receiving written informed consent from the patient. The peripheral blood smear showed the presence of approximately 5% megathrombocytes (Figure 1). He had no history of hematologic, rheumatic, or diabetic disorders and had not undergone recent surgery.

Figure 1

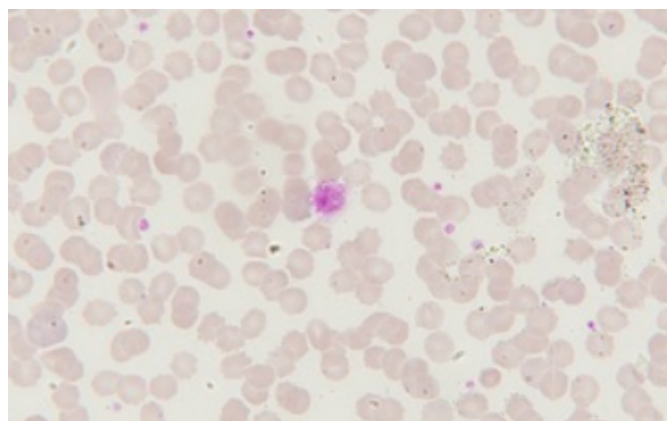
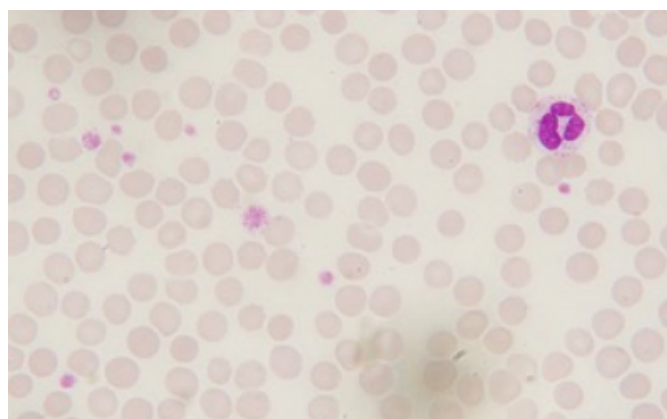


Figure 2



The initial therapy regimen failed to eradicate *H. pylori*, and anti-*H. pylori* IgG antibody, PG I, PG II, and the PG I/PG II ratio showed no marked changes (Table 1). A second treatment regimen consisting of amoxicillin 1500 mg/day, clarithromycin 400 mg/day, metronidazole 750 mg/day, and vonoprazan 40 mg/day for 1 week was initiated on February 7, 2017. Eradication was successful, and the titer of anti-*H.*

pylori IgG antibody decreased from 81.0 U/mL to 44.0 U/mL, finally reaching 22.0 U/mL. The changes in serum levels of PG I and PG II and in fasting serum gastrin also indicated successful eradication. The presence of megathrombocytes was observed after the initial therapy. However, their presence could not be confirmed 3 months after the successful eradication. At the same time, platelet configurations decreased. We also confirmed the absence of antinuclear antibody, antiplatelet antibody, and PAIgG in September 2017.

DISCUSSION

The detailed process by which thrombocytopenia is induced in *H. pylori*-infected patients with ITP remains to be resolved, although it appears that immunologic mechanisms are involved [9-11].

It was reported that *H. pylori* binds von Willebrand factor and interacts with glycoprotein Ib (GPIb) [5]. Satoh et al. reported that the vacuolating cytotoxin (VacA) of *H. pylori* binds to multimerin 1 on human platelets [7]. In addition, Kuwana et al. found that peripheral B cells from primary ITP patients produce anti-GPIb autoantibodies [8]. From those results, it appears that *H. pylori* aggregates platelets in infected individuals through binding to GPIb or multimerin.

Because the regression of megathrombocytes was observed only after successful eradication, the occurrence of *H. pylori* infection may affect normal proliferation or differentiation of the megakaryocytic lineage.

With few reports on the presence of megathrombocytes in healthy individuals, it is difficult to determine whether the detection of megathrombocytes was unique to the current patient. However, Deb Roy et al. reported the presence of giant platelets in voluntary platelet donors in India [12]. Thirty of 45 “healthy” donors were found to have giant platelets and low platelet counts without showing a tendency to bleed. Those 30 donors had Harris platelet syndrome, which is unique to the Indian subcontinent [13]. That is not relevant to our patient, however, who was ethnically Japanese with normal platelet counts.

Although we cannot rule out the possibility that the patient was in the process of developing ITP at the time of the first visit to Tsurumi University Hospital, the presence of megathrombocytes was clearly/closely associated with *H. pylori* infection, since their regression was observed only

after *H. pylori* eradication. In accordance with the phenomenon, platelet parameters such as plateletcrit, mean platelet volume, and platelet distribution width were decreased only after the eradication. We therefore believe that the megathrombocytes were induced by *H. pylori* infection in our patient.

To the best of our knowledge, increases in megathrombocytes in individuals without immunohematologic disorders have rarely been reported, except in diabetic patients with retinopathy and patients who have undergone recent surgery [2]. Because the current patient had neither ITP nor diabetes mellitus, this phenomenon seems to be uniquely induced by *H. pylori* infection.

It remains difficult to understand how *H. pylori* eradication improves thrombocytopenia in some ITP patients. As in the current case, megakaryocytic proliferation/differentiation could be affected in some patients by *H. pylori* itself or by its products such as anti-GPIb antibody and VacA. Such patients may respond well to eradication therapy. ITP appears to develop via three distinct mechanisms: induction by *H. pylori* itself; induction by *H. pylori* products; and by a mechanism unrelated to *H. pylori*. If the status of megakaryocytic differentiation could be evaluated, it might be possible to predict the efficacy of *H. pylori* eradication for some ITP patients.

To clarify the mechanism of megathrombocytes induction in *H. pylori*-infected patients, further follow-up with careful evaluation of hematologic characteristics in those with and without ITP will be crucial. Elucidation of the pathoetiologic roles of *H. pylori* infection in ITP patients will require the collection and comparative analysis of additional cases in whom eradication were both successful and unsuccessful.

CONCLUSION

Why *H. pylori* eradication improves thrombocytopenia in some ITP patients remains unresolved. As in the current case, some ITP patients could have hindered megakaryocytic proliferation/differentiation induced by *H. pylori*, and such patients may respond well to eradication therapy.

Acknowledgment

We thank Dr. Yumi Ito, Division of Diagnostic Pathology, Tsurumi University School of Dental Medicine, for technical assistance in the analysis of this case study.

Authors' contributions

HY, HT, and YM planned the case report concept and design, collected data, and prepared the manuscript. YF, TH, and KM assembled study data and offered useful criticism of the manuscript. All authors read and approved the final manuscript.

Conflicts of interest

Dr. Yoshihiro Matsukawa received honoraria for lectures from Astra-Zeneca and Takeda Pharmaceutical.

Dr. Hideto Tamura received honoraria for lectures from Bristol-Myers Squibb, Cellegene, Ono Pharmaceutical, and Takeda Pharmaceutical; advisory fees from Ono Pharmaceutical; and a research grant from Cellegene.

Drs. Hiroyuki Yamanaka, Yuri Fukui, Tohru Hayakawa, and Katsuhiro Miura have no conflicts of interest to report.

We declare that the patient's written informed consent for the publication of this case report was obtained on December 1, 2018.

References

1. Karg SK, Lackner H, Karpatkin S (1972) The increased percentage of megathrombocytes in various clinical disorders. *Ann Intern Med* 77:361–367
2. Saito H, Matsushita T, Yamamoto K, Kojima T, Kunishima S (2005) Giant platelet syndrome. *Hematology* 10 suppl 1:41–46
3. Gasbarrini A, Franceschi F, Tartaglione R, Landorfi R, Pola P, Gasbarrini G (1998) Regression of autoimmune thrombocytopenia after eradication of *Helicobacter pylori*. *Lancet* 352:878
4. Franchini M, Cruciani M, Mengoli C, Pizzolo G, Veneri D (2007) Effect of *Helicobacter pylori* eradication on platelet counts in chronic idiopathic thrombocytopenic purpura: a systematic review and meta-analysis. *J Antimicrob Chemother* 60:237–246
5. Byrne MF, Kerrigan SW, Corcoran PA, et al (2003) *Helicobacter pylori* binds von Willebrand factor and interacts with GPIb to induce platelet aggregation. *Gastroenterology* 124:1846–1854
6. Corcoran PA, Atherton JC, Kerrigan SW, et al (2007) The effect of different strains of *Helicobacter pylori* on platelet aggregation. *Can J Gastroenterol* 21:367–370
7. Satoh K, Hirayama T, Takano K, et al (2013) VacA, the vacuolating cytotoxin of *Helicobacter pylori*, binds to multimerin 1 on human platelet. *Thrombosis J* 11:23.
8. Kuwana M, Okazaki Y, Ikeda Y (2014) Detection of circulating B cells producing anti-GPIb autoantibodies in patients with immune thrombocytopenia. *PLoS One* 9:e86943
9. Kuwana M (2014) *Helicobacter pylori*-associated immune thrombocytopenia: clinical features and pathogenic mechanisms. *World J Gastroenterol* 21:714–723
10. Flydman GH, Davis N, Beck PL, Fox JG (2015) *Helicobacter pylori* eradication in patients with immune thrombocytopenic purpura: a review and the role of biogeography. *Helicobacter* 20:239–251

11. Zufferey A, Kapur R, Semple JW (2017) Pathogenesis and therapeutic mechanisms in immune thrombocytopenia (ITP). J Clin Med 9:6(2)
12. Deb Roy A, Choudhury N, Ray D (2015) Giant platelets

- in platelet donors—a blessing in disguise? J Clin Diag Res 9:EC01–03
13. Choccalingam C, Samuel P, Swamynathan K (2013) Harris platelet syndrome: the need to recognise the entity. J Med Health Sci 2:11–12

Author Information

Hiroyuki Yamanaka

Department of Internal Medicine, Tsurumi University School of Dental Medicine
Kanagawa, Japan

Yuri Fukui

Department of Internal Medicine, Tsurumi University School of Dental Medicine
Kanagawa, Japan

Tohru Hayakawa

Department of Dental Engineering, Tsurumi University School of Dental Medicine
Kanagawa, Japan

Katsuhiro Miura

Division of Hematology and Rheumatology, Department of Medicine, Nihon University School of Medicine
Tokyo, Japan

Hideto Tamura

Department of Hematology, Nippon Medical School
Tokyo, Japan

Yoshihiro Matsukawa

Department of Internal Medicine, Tsurumi University School of Dental Medicine; Division of Hematology and Rheumatology, Department of Medicine, Nihon University School of Medicine
Kanagawa, Japan; Tokyo, Japan