

Cerebral Metastases From Merkel Cell Carcinoma: Long Term Survival

S Rogers, S Honeybul, R Junckerstorff

Citation

S Rogers, S Honeybul, R Junckerstorff. *Cerebral Metastases From Merkel Cell Carcinoma: Long Term Survival*. The Internet Journal of Neurosurgery. 2009 Volume 7 Number 1.

Abstract

Merkel cell carcinoma is a rare primary cutaneous neuro-endocrine tumour that is locally aggressive. In most cases the primary treatment is local surgical excision, however, there is a high incidence recurrence both local and distant. Cerebral metastases from Merkel cell carcinoma are extremely uncommon with only 12 cases published in the literature. We report a case that is particularly unusual in that, not only was no established primary lesion identified, but also the patient has survived for five years following initial diagnosis, and for four years following excision of a single brain metastasis.

INTRODUCTION

Merkel cell carcinoma is a rare primary cutaneous neuro-endocrine tumour that is locally aggressive and has potential for metastatic spread. It was originally described in 1972 by Toker as a sweat gland variant and has become so named because of the discovery of membrane bound dense core neurosecretory granules similar to those found in the normal merkel cell, a neuroendocrine cell of the skin[19].

Given the limited number of published series, there is currently no consensus regarding optimal therapeutic approach [3, 12]. The principal treatment is surgical excision, however, the clinical behaviour is characterised by a high incidence of local recurrence, lymph node involvement and distant metastases [3, 12]. Adjuvant radiotherapy and chemotherapy have limited impact on overall survival and the prognosis for those patients with progressive disease is poor [12]. The incidence of disease related death ranges from 35% to almost 50% [3, 12].

Cerebral metastases from Merkel cell carcinoma are extremely uncommon with only 12 cases published in the literature. We report a case that is particularly unusual in that, not only was no established primary lesion identified, but also the patient has survived for five years following initial diagnosis, and for four years following excision of a single brain metastasis.

CASE REPORT

In June 2005, a 65 year-old male presented with a 10cm mass in the right axilla. This had been present for several

months but had recently increased in size. There were no primary skin lesions. Initially he underwent fine needle aspiration cytology and then an axillary clearance. Histopathological examination showed metastatic high-grade neuroendocrine carcinoma in three out of nine lymph nodes. The tumour cells showed positive immunohistochemical staining for the neuroendocrine markers synaptophysin, chromogranin and CD56. There was perinuclear dot-like positivity for cytokeratin 20 and the overall findings were consistent with metastatic Merkel cell carcinoma. He was extensively investigated but there was no clinical or radiological evidence of a primary source. He had local radiotherapy at a dose of 50.8 Gy in 28 fractions to the right axilla and supraclavicular fossa over a six week period followed by systemic chemotherapy with cisplatin and etoposide. He made an uneventful recovery but presented one year later with intermittent dysphasia and confusion. MRI of the brain revealed a homogeneously enhancing lesion in the left posterior temporal lobe (Figure 1).

Figure 1

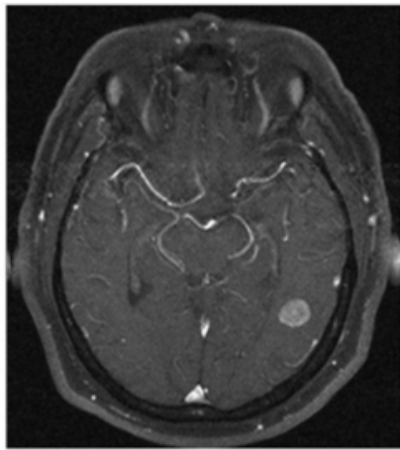


Figure 1. Axial T1 with Gadolinium MRI showing left temporal lesion

Staging CT scans identified no other lesions and this was felt to be an isolated metastasis. The patient had a craniotomy and excision of the tumour. Histopathology confirmed a high-grade neuroendocrine carcinoma with an identical immunohistochemical profile consistent with metastatic Merkel cell carcinoma (Figure 2).

Figure 2

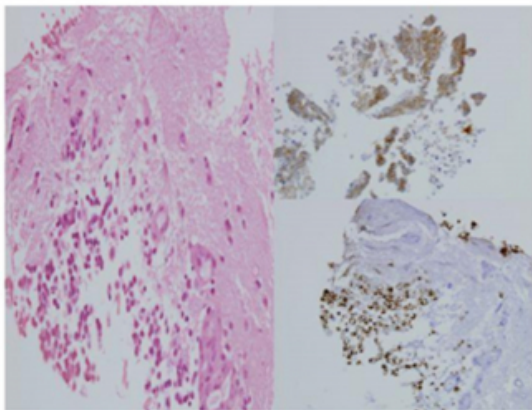


Figure 2. H&E Stain for brain tissue, left. Immuno-stain for CK20 bottom right; Immuno-stain for CD56 upper right. 400x magnification

After recovering from surgery the patient had a course of whole brain radiation therapy (30Gy). He remains well at five years follow up with no clinical or radiological evidence of recurrence (Figure 3).

Figure 3

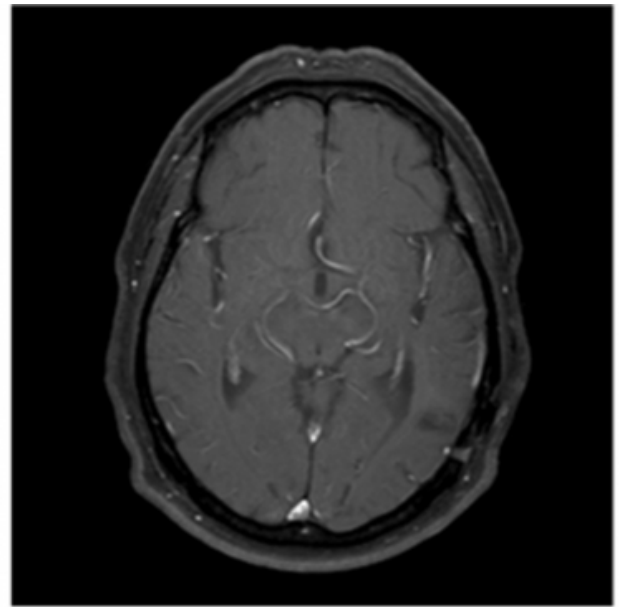


Figure 3. Axial T1 with Gadolinium MRI showing no evidence of recurrence at 3 year follow up.

DISCUSSION

Merkel Cell carcinoma is a cutaneous, neuro-endocrine tumour, which is locally aggressive and has the potential for metastatic spread [12]. Whilst the incidence has been reported to be increasing [3], it is still a relatively rare tumour. It predominantly affects elderly Caucasians with a male predominance [3, 12] and it most commonly arises on sun exposed areas of the head and neck region (40.6%) with lesions in the extremities and trunk representing 33% and 23% of cases respectively. In some cases no primary lesion can be identified [5, 12].

The most consistent prognostic factor associated with survival is the stage of the disease at presentation [1]. Investigators at Memorial Sloan-Kettering Cancer Center identified tumour diameter as an independent predictor of survival and developed a 4 tiered staging system in 1999. The more recently modified 4 tiered system separates patients with localised and distant disease. Stage I (primary tumour <2cm); stage II (Primary tumour >2 cm diameter); Stage III (Patients with regional disease) and Stage IV (patients with distant disease) [1]. 70% of patients present with stage I or II disease, 25% have loco-regional lymph node involvement and 5% present with stage IV) [2, 12, 13].

Because of its aggressive clinical behaviour, the treatment of choice is wide surgical excision of the primary tumour with

adjuvant radiotherapy to control local disease [12]. Chemotherapy is generally reserved for stage III disease. Despite these treatment regimes outcome can be poor especially for stage III and Stage IV disease [5, 12]. Allen reported their single institution five year survival rates for Stage I - 81%, Stage II - 67%, Stage III - 52% and stage IV - 11% [2].

When considering all types of isolated brain metastases, surgical resection can give better results than radiotherapy alone in cases where the lesion is accessible and causing either neurological symptoms or significant mass effect. A number of studies have demonstrated that patients with a good preoperative level of function and well-controlled systemic disease have improved survival, longer functional independence and a better quality of life than similar patients treated with radiotherapy alone [14, 15, 20].

Interpreting these studies in relation to merkel cell carcinomas has its limitations as there have been only 12 cases reported [5 – 11, 16 – 18, 21–22]. Of these, one case advocated aggressive chemotherapy and radiotherapy with curative intent resulting in marginal prolongation of survival [21]. A similar management strategy was supported by Ikawa, with the addition of surgical resection in combination with radiotherapy and chemotherapy, however, this led to survival of only 11 months [11]. Unfortunately most cases with brain metastases have been treated with palliative radiotherapy and chemotherapy and overall survival has been poor.

The question still remains as to why our particular patient has survived for so long.

The lack of a known primary tumour may be of some relevance. Whilst merkel cell carcinomas presenting with lymph node metastases and an unknown primary is a rare occurrence it has been reported [5, 12], and two possible hypotheses have been suggested: firstly, spontaneous regression of the primary lesion and secondly, primary nodal localisation of merkel cell carcinomas [13].

Whilst the complete spontaneous regression is very rare it is well documented [4] and it has been suggested to be due to an immune reaction induced by biopsy [12]. Whether this may be responsible for the prolonged survival in this case unknown, however, there are certainly unanswered questions regarding immunological aspects of this cancer. What this case demonstrates is that in certain cases resection of an isolated metastases may provide good disease despite what

may appear to be an indicator of poor prognosis.

References

1. Allen PJ, Zhang ZF, Coit DG (1999) Surgical management of Merkel cell carcinoma. *Ann Surg* 229: 97-105
2. Allen PJ, Browne WB, Jaques DP, Brennan MF, Busam K, Coit DG (2005) Merkel cell carcinoma: prognosis and treatment of patients from a single institution. *J Clin Oncol* 23: 2300-2309
3. Bichakjian CK, Lowe L, Lao CD, Sandler HM, Bradford CR, Johnson TM, Wong SL (2007) Merkel cell carcinoma: critical review with guidelines for multidisciplinary management. *Cancer* 1;110(1):1-12
4. Connolly TJ, Cribier B, Brown TJ, Yanguas I (2000) Complete spontaneous regression of merkel cell carcinoma: a review of 10 reported cases. *Dermatol surg* 26:853-856
5. De Cicco L, Vavassori A, Jerezek-Fossa BA, Pruneri G, Catalano G, Ferrari AM, Orecchia R (2008) Lymph node metastases of Merkel cell carcinoma from unknown primary site: report of three cases. *Tumori* 94(5):758-61
6. Eggers SD, Salomao DR, Dinapoli RP, Vernino S (2001) Paraneoplastic and metastatic neurological complications of Merkel Cell Carcinoma. *Mayo Clin Proc* 76: 327-330
7. Eusebi V, Capella C, Cossu A, Rosai J (1992) Neuroendocrine carcinoma within lymph nodes in the absence of a primary tumor, with special reference to Merkel cell carcinoma. *Am J Surg Pathol* 16(7):658-66.
8. Goepfert H, Remmler D, Silva E, Wheeler B (1984) Merkel cell carcinoma (endocrine carcinoma of the skin) of the head and neck. *Arch Otolaryngol* 110:707-712
9. Giannone L, Johnson D, Grosh W, Dabis B, Marangos P, Greco FA (1985) Serum neuron-specific enolase in metastatic Merkel cell tumours. *Med Pediatr Oncol* 13:357-362
10. Hitchcock CL (1988) Neuroendocrine (Merkel Cell) Carcinoma of the skin its natural history, diagnosis and treatment. *Ann Surg* 207:201-207
11. Ikawa F, Kia K, Uozumi T, Yuki K, Takeshita S, Hamasaki O, Arita K, Kurisu K (1999) Brain metastasis of Merkel cell carcinoma. *Neurosurgical review* 22: 54-57
12. Medina-Franco H, Urist MM, Fiveash J, Heslin MJ, Bland KI, Beenken SW (2001) Multimodality treatment of merkel cell carcinoma: case series and literature review of 1024 cases. *Ann surg oncol* 8:204-208
13. Ott MJ, Tanabe KK, Gadd MA (1999) Multimodality management of Merkel cell carcinoma. *Arch surg.* 134: 388-392; discussion, 392-383
14. Patchell RA, Tibbs PA, Walsh JW, Dempsey RJ, Maruyama Y, Kryscio RJ (1990) A randomised trial of surgery in the treatment of single metastases to the brain. *N Engl J Med* 322:494-500.
15. Patchell RA, Tibbs PA, Regine WF (1998) Postoperative radiotherapy in the treatment of single metastases to the brain: a randomised trial. *JAMA* 280:1485-1489
16. Sharma D, Flora G, Grunberg SM (1991) Chemotherapy of metastatic Merkel Cell carcinoma: Case report and review of the literature. *Am J Clin Oncol* 14:166-169
17. Small KW, Rosenwasser GO, Alexander E III, Rossitch G, Dutton JJ (1990) Presumed choroidal metastasis of merkel cell carcinoma. *Ann Ophthalmol* 22:187-190
18. Snodgrass SM, Landy H, Markoe AM, Feun L (1994) neurologic complications of Merkel cell carcinoma. *J Neurooncol* 22:231-234
19. Tang CK, Toker C (1978) Trabecular carcinoma of the skin: an ultrastructural study. *Cancer* 42:2311-2321
20. Vecht C, Haaxma-Rieche H, Noordijk EM (1993)

Treatment of single brain metastases: radiotherapy alone or combined with neurosurgery? Ann Neurol 33:583-590.

21. Wick M, Goellner JR, Scheithauer B, Thomas JR, Sanchez N, Schroeter A (1983) Primary neuroendocrine

ccarcinomas of the skin (Merkel Cell tumours). Am J Clin Pathol 79:6-13

22. Yiengspruksawan A, Coit DG, Thaler HT, Urmacher C, Knapper WK (1991) Merkel cell Carcinoma. Prognosis and management. Arch Surg 126:1514-1519

Author Information

S.J Rogers

Department of Neurosurgery, Sir Charles Gairdner Hospital and Royal Perth Hospital

S Honeybul

Department of Neurosurgery, Sir Charles Gairdner Hospital and Royal Perth Hospital

R. C Junckerstorff

Division of Tissue Pathology, PathWest Laboratory Medicine