

Sphingobacterium Thalpophilum Bacteraemia: A Case Report

A Azarfar, S Bhattacharya, S Siddiqui, N Subhani

Citation

A Azarfar, S Bhattacharya, S Siddiqui, N Subhani. *Sphingobacterium Thalpophilum Bacteraemia: A Case Report*. The Internet Journal of Infectious Diseases. 2020 Volume 18 Number 1.

DOI: [10.5580/IJID.55030](https://doi.org/10.5580/IJID.55030)

Abstract

A Gram-negative rod was isolated from the blood cultures of an immunocompetent patient with right lower extremity cellulitis. The microbiology lab identified the bacterium as "Sphingobacterium Thalpophilum," a very rare microorganism from Sphingobacterium genus that can cause human infection. High sphingophospholipids in the cell membrane, is the characterization of these bacteria. Only a few species have been reported to cause infections in humans, including *S. mizutae*, *S. multivorum*, and *S. spiritivum*. We treated our patient based on prior published case reports and literature. He received piperacillin-tazobactam for 5 days that resulted in the improvement of the patient's symptoms. This is the first reported case of human *S. thalpophilum* infection in the United States. Although infection with this genus is rare but literature have shown they can be fatal, specifically in immunosuppressed population.

INTRODUCTION

Sphingobacterium genus includes gram-negative, saccharolytic, non-lactose-fermentative microorganisms which they are catalase and oxidase positive, indole negative, and produce small circular, convex, smooth and opaque colonies with light yellow pigment, mostly on blood agar and MacConkey agar plates. An important feature of bacteria that belong to this genus is the presence of high concentrations of sphingophospholipids in their cell membrane^[1,6]. This genus consists of 15 species: *S. anhuiense*, *S. antarcticus*, *S. bambusae*, *S. canadense*, *S. composti*, *S. daejeonense*, *S. faecium*, *S. heparinum*, *S. kitahiroshimense*, *S. multivorum*, *S. piscium*, *S. shayense*, *S. siyangense*, *S. spiritivum*, and *S. thalpophilum*^[2,4,7]. They can be found in the water source, soil, on plants and in food materials^[3], but the isolation of the species from human clinical specimens has been rarely reported worldwide^[4]. Two bacteria from this group (*Sphingobacterium multivorum* and *Sphingobacterium spiritivum*) have been shown to be associated most with bacteremia, peritonitis and respiratory infection in patients with severe underlying diseases^[5], but to our knowledge, there are very few case reports on infections with *Sphingobacterium thalpophilum* in the immunocompetent host. We present a case of 69-year-old relatively healthy male with *Sphingobacterium*

thalpophilum right leg cellulitis, which caused bacteremia.

CASE PRESENTATION

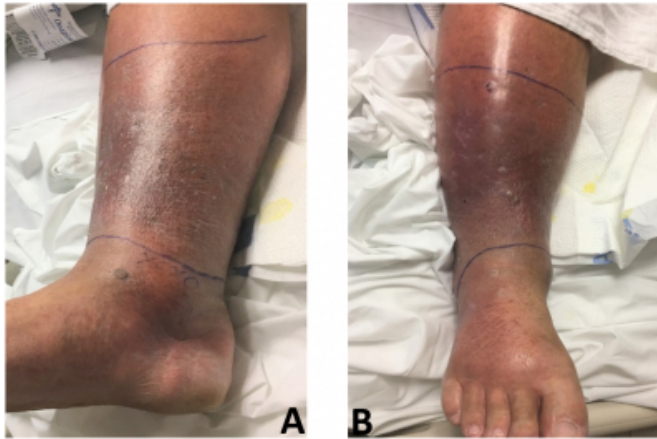
69-year-old man with a past medical history of hypertension, chronic vascular insufficiency, and obesity who was admitted to our hospital with complain of acute onset pain and swelling in his right lower extremity. On the night before admission, the patient had noticed a progressive burning sensation and edema accompanied by aching dull pain on his right lower extremity. The same day, he noted a small open wound on his right lower extremity (without a preceding trauma) while pressure washing his dock, which was covered in bird feces, dirt, and algae. On the review of systems, he reported associated frontal headache, rigors and left sided flank pain all started the night prior to admission. He denied having recent fevers, nausea, vomiting, productive cough, diarrhea, dysuria, and increase in urinary frequency.

Physical examination revealed normal vital signs. The patient was alert and oriented to person, place and time, was not in distress, heart and lung sounds were normal, abdominal exam was benign, 1+ non pitting edema noted in lower extremities with decreased peripheral pulses bilaterally, right lower extremity skin appeared swollen, red, and was painful to palpation and warm to the touch, borders

of the cellulitis were diffused, and they were marked with a pen to better assess the progression (Figure 1).

Figure 1

Right leg cellulitis with redness, warmth, and swelling of the skin and poorly demarcated borders. A, medial view and B, anterior view.



An initial complete blood cell count showed the following results: hemoglobin, 14.1 g/dL; white blood cell counts (WBC), 27.75 K/mm³ (neutrophils, 88.1%); platelet counts, 223 K/mm³. Lactic acid was within normal limit. The patient's blood was collected for cultures. Empiric therapy of piperacillin-tazobactam (4.5 g every 8 hours), and vancomycin (1g every 8 hours) were initiated. The next day after initiation of therapy, the patient had much improvement in his symptoms, and borders of the cellulitis had decreased in size, although his WBC stayed high at 23.03 K/mm³. Preliminary gram stain of the blood cultures 2 out of 2 sets showed gram-negative rods, and the antibiotic regimen narrowed down to piperacillin-tazobactam only. 48 hours later, the bacterium was identified as "*Sphingobacterium Thalophilum*". Unfortunately, our microbiology lab could not identify a proper antibiogram and sensitivities for this specific bacteria, so we continued the treatment with the same regimen, based on patient excellent clinical response and other publications of similar cases with the same recommendations for the treatment. The patient was clinically stable during remaining stay with complete resolution of his leukocytosis and underlying cellulitis. His antibiotic regimen was switched to oral amoxicillin-clavulanic acid (875 mg every 12 hours) for another 5 days to complete a 10-day course of therapy.

DISCUSSION

Bacteria that belong to *Sphingobacterium* genus are gram-negative, catalase, and oxidase positive, non-fermentative

bacilli which are rarely involved in human infections^[6,7]. This species contains sphingolipids, can ferment glucose, can reduce nitrate to nitrite, and is oxidase, DNase and urease positive.

S. thalophilum is extremely rare announced to be a human pathogen^[8]. It was first reported in 1983 by B. Holmes et al. as a new strain of *Flavobacterium* group that was mainly isolated from clinical specimens, which among those specimens, most common sources, were blood and wounds^[9]. The name of the group then changed to *Sphingobacterium* as this genus cell wall found to have a high concentration of sphingolipids. *Sphingobacterium*s are usually of low virulence, but in the immunocompromised patients, they can cause severe degree of symptoms^[5]. They can be found in water, soil and foodstuff^[3], but in our case, we were not able to establish the source of the pathogen, we speculate that it was present in the water or soil of the patient yard as per patient history.

Because *Sphingobacterium* infections are infrequent, there are no established therapies for them, and they have shown a variable antimicrobial susceptibility pattern. In general, *Sphingobacterium* species are resistant to aminoglycosides and polymyxin B but are susceptible to quinolones and trimethoprim-sulfamethoxazole^[4]. In one study, Holmes et al. reported the isolate *S. thalophilum* was resistant to ampicillin, gentamycin, and tetracycline but a case report of Ostwal et al. revealed that *S. thalophilum* is sensitive to all antibiotics except ampicillin^[9,10]. Unfortunately, our microbiology lab was not equipped to do sensitivities for this bacterium, herby, we treated the patient empirically with piperacillin-tazobactam and he recovered drastically after 5 days.

We believe our case is unique, as despite detailed research, we were unable to identify any other reports of the *Sphingobacterium thalophilum* bacteraemia in an immunocompetent host in the United States. This case can be a contribution to the limited number of published cases of human infection with this novel strain of bacteria so far.

Conflict of interest

The authors declare that there is no conflict of interest.

Disclaimer

This research was supported (in whole or in part) by HCA Healthcare and/or an HCA Healthcare affiliated entity. The views expressed in this publication represent those of the

author(s) and do not necessarily represent the official views of HCA Healthcare or any of its affiliated entities.

Ethics and Consent

The patient has provided permission and a written consent to publish these features of his case. The identity of the patient has been protected.

Funding statement

No specific funding was received from any bodies in the public, commercial or not-for-profit sectors to carry out the work described in this case report.

References

1. Mandell G, Bennett J, Dolin R. Principles and practice of infectious diseases. 7th ed. Philadelphia: Elsevier; 2010. 3016–3017, 3027.
2. Holmes B, Owen RJ, Hollis DG: *Flavobacterium spiritovorum*, a new species isolated from human clinical specimens. *Int J Syst Bacteriol* 1982, 32:157-165.
3. Grimaldi D, Doloy A, Fichet J, Bourgeois E, Zuber B, Wajsfisz A, et al. Necrotizing fasciitis and septic shock related to the uncommon Gramnegative pathogen *Sphingobacterium multivorum*. *J Clin Microbiol* 2012;50:202–3.
4. Koh, Y. R., Kim, S. Y., Chang, C. L., Shin, H. J., Kim, K. H., & Yi, J. (2013). The first Korean case of *Sphingobacterium spiritovorum* bacteremia in a patient with acute myeloid leukemia. *Annals of laboratory medicine*, 33(4), 283-287.
5. Tronel, H., Plesiat, P., Ageron, E., & Grimont, P. A. D. (2003). Bacteremia caused by a novel species of *Sphingobacterium*. *Clinical microbiology and infection*, 9(12), 1242-1244.
6. Reina J, Borrel N, Figuerola J. *Sphingobacterium multivorum* isolated from a patient with cystic fibrosis. *Eur J Clin Microbiol Infect Dis*. 1992;11:81–82. doi: 10.1007/BF01971283
7. Lambiase, A., Rossano, F., Del Pezzo, M., Raia, V., Sepe, A., de Gregorio, F., & Catania, M. R. (2009). *Sphingobacterium* respiratory tract infection in patients with cystic fibrosis. *BMC research notes*, 2(1), 262.
8. Barahona, F., & Slim, J. (2015). *Sphingobacterium multivorum*: case report and literature review. *New microbes and new infections*, 7, 33-36.
9. Holmes, B., Hollis, D. G., Steigerwalt, A. G., Pickett, M. J., & BRENNER, D. J. (1983). *Flavobacterium thalpophilum*, a new species recovered from human clinical material. *International Journal of Systematic and Evolutionary Microbiology*, 33(4), 677-682.
10. Ostwal, K., Shah, P., Jadhav, A., Shaikh, N. (2015). *Sphingobacterium thalophilum* in H1N1 positive patient - first case report in India. *International Journal of Applied Research*, 1(5): 215-217.

Author Information

Azin Azarfar

University of Central Florida HCA GME Healthcare; Department of Internal Medicine, University of Central Florida College of Medicine
Orlando, FL

Sreyasi Bhattacharya

University of Central Florida HCA GME Healthcare; Department of Internal Medicine, University of Central Florida College of Medicine
Orlando, FL

Shoaib Siddiqui

Osceola Regional Medical Center
Kissimmee, FL

Noman Subhani

Osceola Regional Medical Center
Kissimmee, FL