

Trepopnea Due To Compression Of The Right Main Bronchus By The Vertebral Bodies: A Case Report

N Wadaa, Y Kataokaa, T Takemuraa, K Okazakia, E Saitoa, H Matsumotoa, R Ikia, J Nikaidoa, I Yuasab, T Fukadab, H Takechib, H Sakaib, K Itoi

Citation

N Wadaa, Y Kataokaa, T Takemuraa, K Okazakia, E Saitoa, H Matsumotoa, R Ikia, J Nikaidoa, I Yuasab, T Fukadab, H Takechib, H Sakaib, K Itoi. *Trepopnea Due To Compression Of The Right Main Bronchus By The Vertebral Bodies: A Case Report*. The Internet Journal of Pulmonary Medicine. 2020 Volume 20 Number 1.

DOI: [10.5580/IJPM.55072](https://doi.org/10.5580/IJPM.55072)

Abstract

Trepopnea due to causes other than heart failure is rare. Here we report an unusual case involving a 63-year-old man with trepopnea caused by compression of the right main bronchus by the thoracic vertebral bodies. The patient had a history of pulmonary tuberculosis and a deformed thorax, and he was hospitalized for acute exacerbation of chronic obstructive pulmonary disease secondary to pneumococcal pneumonia. Although his pneumonia resolved, significant hypoxemia was observed in the left lateral decubitus position. Bronchoscopic examination confirmed compression of the right main bronchus by the fifth and sixth thoracic vertebral bodies. An Ultraflex™ stent was placed for expansion of the bronchus, following which the trepopnea disappeared. Two years later, we performed balloon expansion of the bronchus because granulation tissue had narrowed the stent lumen. The latest bronchoscopic examination performed 6 years after balloon expansion showed no abnormalities. Our findings suggest that trepopnea due to causes other than heart failure can be resolved by identification and management of the underlying cause. Bronchoscopy may be useful in cases where the cause is difficult to identify by conventional imaging modalities.

Abbreviations

COPD: chronic obstructive pulmonary disease

CT: computed tomography

INTRODUCTION

Trepopnea, defined as dyspnea while lying on one side, generally occurs in cases of unilateral pleural effusion due to heart failure or unilateral lung lesions [1,2]. There are very few reports of trepopnea associated with other causes [3-5]. Here, we report a rare case involving a 63-year-old man with trepopnea caused by compression of the right main bronchus by the fifth and sixth thoracic vertebral bodies.

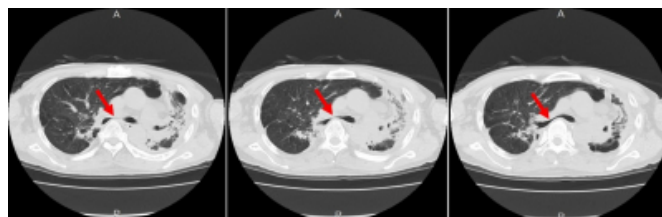
CASE REPORT

A 63-year-old man presented to the emergency department with breathing difficulty accompanied by cough and sputum. He was diagnosed with acute exacerbation of COPD secondary to pneumococcal pneumonia and was intubated. He had undergone treatment for pulmonary tuberculosis at the age of 53 years and was a current smoker. He

complained of breathing difficulty, particularly in the left lateral decubitus position, before hospitalization. Chest radiography and CT revealed deformation of the left lung and deviation of the trachea to the left, which were consequences of the pulmonary tuberculosis (Figure 1,2).

Figure 1

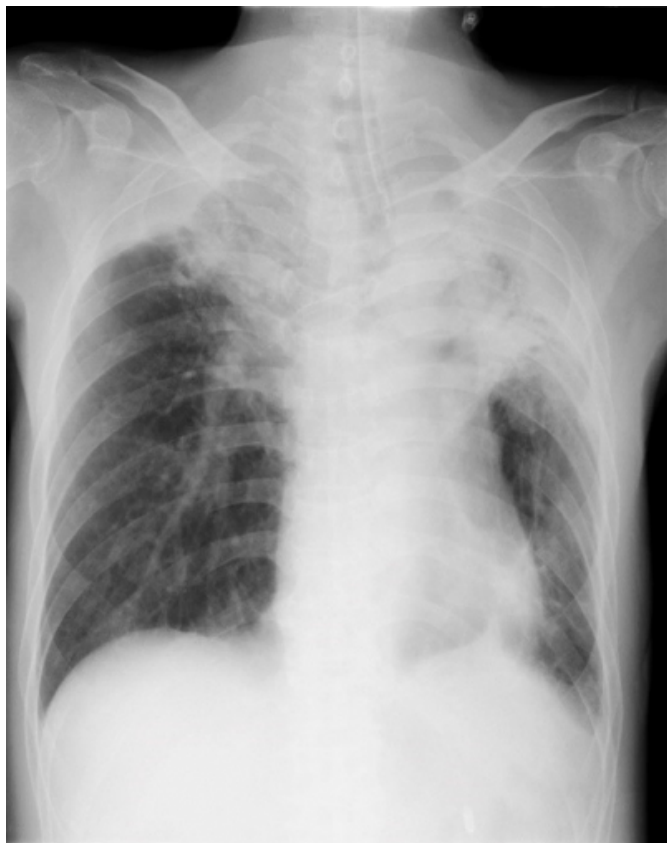CT findings for a 63-year-old man with trepopnea



The images show deformation of the left lung. Arrows indicate the right main bronchus.

Figure 2

Chest X-ray findings for a 63-year-old man with trepopnea



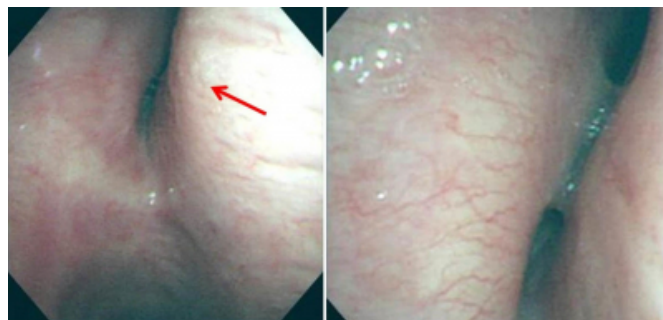
The images show deformation of the left lung and deviation of the trachea to the left, which are consequences of previous pulmonary tuberculosis.

Antibiotic and steroid therapy was administered and the pneumonia gradually resolved; however, significant hypoxemia persisted in the left lateral decubitus position. Contrast-enhanced CT and echocardiography could not clarify the cause of this trepopnea.

We performed bronchoscopy in the supine position and observed compression of the orifice of the right main bronchus and its lower lobe branch by the fifth and sixth thoracic vertebral bodies (Figure 3).

Figure 3

Findings of bronchoscopy for a 63-year-old man with trepopnea

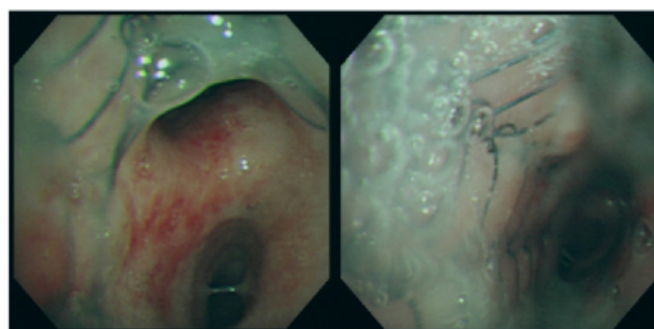


Bronchoscopy shows compression of the orifice of the right main bronchus (arrow) and its lower lobe branch by the fifth and sixth thoracic vertebral bodies

The patient and his family provided written informed consent for off-label usage of a metallic stent for the management of a benign disease. On day 15 of hospitalization, a metallic stent was inserted in the trunk of the middle tracheal branch through an intubation tube. We selected the Ultraflex™ stent (Microinvasive, Boston Scientific Corporation, Boston, MA), which had a diameter of 12 mm and length of 4 cm. The trepopnea disappeared after the stent placement procedure (Figure 3,4).

Figure 3a

Bronchoscopy shows that the entrance of the right upper lobe has been opened by the stent.



Two years later, we observed granulation tissue formation that narrowed the stent lumen in the right main bronchus and accordingly performed balloon expansion. No further complications were observed, and the latest bronchoscopic examination performed 6 years after the balloon expansion showed no abnormalities (Figure 4).

Figure 4

Findings of CT after insertion of a metallic stent (Ultraflex™; Microinvasive, Boston Scientific Corporation, Boston, MA) in a 63-year-old man with trepopnea

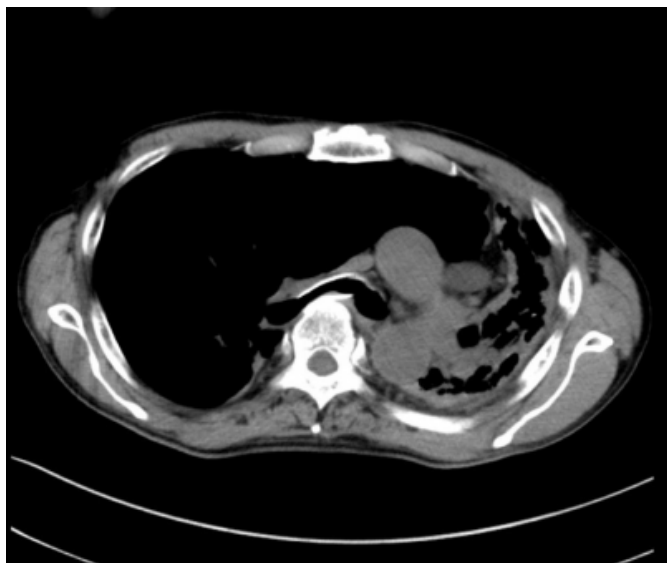
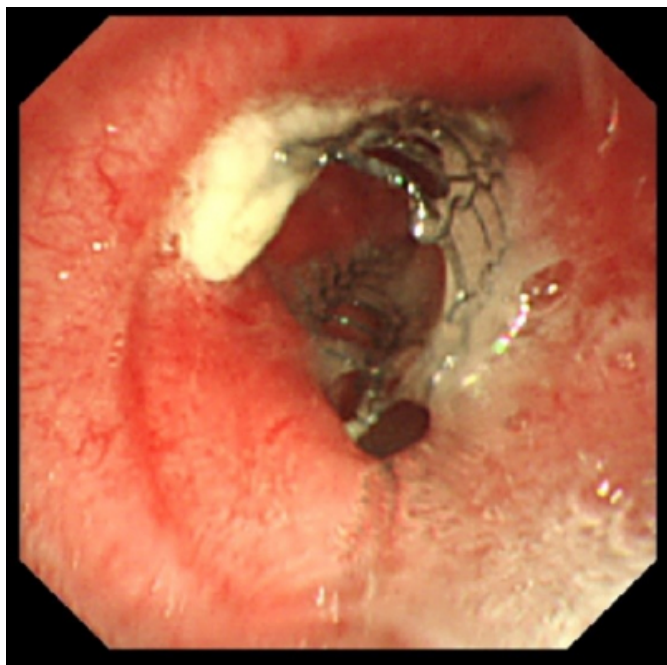


Figure 5

Findings of bronchoscopy performed 6 years after insertion of a metallic stent (Ultraflex™; Microinvasive, Boston Scientific Corporation, Boston, MA) in a 63-year-old man with trepopnea. Bronchoscopy shows the entire right upper lobe. The stent has maintained patency of the lumen.



DISCUSSION

To the best of our knowledge, there is no reported case of trepopnea due to bronchial compression by the vertebral bodies. In the present case, significant hypoxemia was

observed in the left lateral decubitus position, even after antibiotic and steroid treatment for COPD exacerbation secondary to pneumonia. Trepopnea generally occurs in association with unilateral pleural effusion due to congestive heart failure or other forms of unilateral lung disease [1,2], and other causes are quite rare. In patients with heart failure, it usually occurs in the left recumbent position, so the patients prefer to remain in the right lateral decubitus position. The present case was similar, with the patient avoiding the left lateral decubitus position because of hypoxemia. However, he showed no signs of heart failure or right pleural effusion. Trepopnea due to physical airway obstruction by a huge blood clot [4] and a lung tumor [6] has been reported; our patient also exhibited airway obstruction due to bronchial compression by the vertebral bodies. Normally, in addition to physical examination, imaging modalities such as chest radiography, chest CT, and echocardiography are required for determination of the cause of trepopnea. If these modalities fail to identify the cause, bronchoscopy can be performed.

We chose an endotracheal stent to relieve the compression of the right main bronchus by the vertebral bodies. The treatment of trepopnea is based on the treatment of the underlying disease. Airway stenting proves to be valuable in the management of airway stenosis due to both malignant and benign conditions [7,8]. Stents are generally manufactured from silicone, a wire mesh, or a combination of these materials, although the perfect material remains to be elucidated. We chose the Ultraflex™ stent (Microinvasive). Metallic stents are soft and flexible, can be inserted by flexible bronchoscopy, and can be used to manage complex stenosis. On the other hand, silicone stents require a rigid endoscope for insertion. In the present case, we considered insertion of a rigid endoscope to be difficult because of the tracheal deflection angle. Moreover, the silicone stent itself was thick enough to cause tracheal obstruction. Although silicone stents are more resistant to external pressure when expanded, we selected a metallic stent for our patient after considering the ease of deployment, ease of use in cases of complicated stenosis, and high self-expanding force [8]. These stents also exhibit lesser migration and mucosal damage due to physical compression than do silicone stents. However, there is a greater likelihood of granulation tissue formation around metallic stents. In addition, they are more difficult to remove or reposition and are associated with a greater risk of mucosal necrosis and fistula formation [9,10].

CONCLUSIONS

In conclusion, we reported a rare case of trepopnea due to bronchial compression by the vertebral bodies. Although trepopnea due to causes other than heart failure is rare, it can be resolved by identification and management of the underlying cause. Bronchoscopy may be useful in cases where the cause is difficult to identify by conventional imaging modalities. If complex stenosis with strong external bronchial compression is observed, a metallic stent may be more suitable than a silicone stent. Further studies are necessary for determining the optimal intratracheal stent.

ACKNOWLEDGEMENTS

We would like to thank Editage (www.editage.jp) for English language editing. This work was supported, in part, by a grant from the Hyogo Prefectural Amagasaki General Medical Center fiduciary funds (for e-mail delivery service and English editing; no grant numbers apply). This research data is available to access and suitable to post.

References

1. B.S. De Araujo, R. Reichert, D.A. Eifer, S.A. Soder, M.B. Dos Santos, N. Clausell, L. Beck-da-Silva, Trepopnea may explain right-sided pleural effusion in patients with decompensated heart failure, *Am. J. Emerg. Med.* 30 (2012) 925–931.e2. DOI: 10.1016/j.ajem.2011.04.013
2. M. Fujita, S. Miyamoto, K. Tambara, B. Budgell, Trepopnea in patients with chronic heart failure, *Int. J. Cardiol.* 84 (2002) 115–118.
3. L.M. Blasco, Trepopnea due to amiodarone-induced diffuse alveolar hemorrhage, *Respir. Care.* 58 (2013) e11–e13. DOI: 10.4187/respcare.01965
4. G. Sindhvani, R. Khanduri, V. Jethani, S. Kumar, Trepopnea due to blood clot: An uncommon presentation, *Med. J. DY. Patil. Univ.* 9 (2016) 280–282. DOI: 10.4103/0975-2870.167964
5. J. Acosta, F. Khan, R. Chitkara, Trepopnea resulting from large aneurysm of sinus of Valsalva and descending aorta, *Heart. Lung.* 11 (1982) 342–344.
6. Y. Tsunezuka, H. Sato, T. Tsukioka, H. Shimizu, Trepopnea due to recurrent lung cancer, *Respiration.* 67 (2000) 98–100. DOI: 10.1159/000029472
7. C.S. Chin, V. Little, J. Yun, T. Weiser, S.J. Swanson, Airway stents, *Ann. Thorac. Surg.* 85 (2008) S792–S796. DOI: 10.1016/j.athoracsur.2007.11.051
8. H. Kim, Stenting therapy for stenosing airway disease, *Respirology.* 3 (1998) 221–228.
9. K. Tsakiridis, K. Darwiche, A.N. Visouli, P. Zarogoulidis, N. Machairiotis, C. Christofis, A. Stylianaki, N. Katsikogiannis, A. Mpakas, N. Courcotsakis, K. Zarogoulidis, Management of complex benign post-tracheostomy tracheal stenosis with bronchoscopic insertion of silicon tracheal stents, in patients with failed or contraindicated surgical reconstruction of trachea, *J. Thorac. Dis.* 4 (2012) 32–40. DOI: 10.3978/j.issn.2072-1439.2012.s002
10. N. Charokopos, C.N. Foroulis, E. Rouska, M.N. Sileli, N. Papadopoulos, C. Papakonstantinou, The management of post-intubation tracheal stenoses with self-expandable stents: early and long-term results in 11 cases, *Eur. J. Cardio-thoracic. Surg.* 40 (2011) 919–924. DOI: 10.1016/j.ejcts.2010.12.042

Author Information

Nobuko Wadaa

Department of Respiratory Medicine, Hyogo Prefectural Amagasaki General Medical Center
Amagasaki, Hyogo, Japan

Yuki Kataokaa

Department of Respiratory Medicine, Hyogo Prefectural Amagasaki General Medical Center
Amagasaki, Hyogo, Japan

Tomoyasu Takemuraa

Department of Respiratory Medicine, Hyogo Prefectural Amagasaki General Medical Center
Amagasaki, Hyogo, Japan

Koya Okazakia

Department of Respiratory Medicine, Hyogo Prefectural Amagasaki General Medical Center
Amagasaki, Hyogo, Japan

Emiko Saitoa

Department of Respiratory Medicine, Hyogo Prefectural Amagasaki General Medical Center
Amagasaki, Hyogo, Japan

Hiroataka Matsumotoa

Department of Respiratory Medicine, Hyogo Prefectural Amagasaki General Medical Center
Amagasaki, Hyogo, Japan

Reika Ikia

Department of Respiratory Medicine, Hyogo Prefectural Amagasaki General Medical Center
Amagasaki, Hyogo, Japan

Juniti Nikaidoa

Department of Respiratory Medicine, Hyogo Prefectural Amagasaki General Medical Center
Amagasaki, Hyogo, Japan

Itsuki Yuasab

Department of Thoracic Surgery, Hyogo Prefectural Amagasaki General Medical Center
Amagasaki, Hyogo, Japan

Takehisa Fukadab

Department of Thoracic Surgery, Hyogo Prefectural Amagasaki General Medical Center
Amagasaki, Hyogo, Japan

Hiroko Takechib

Department of Thoracic Surgery, Hyogo Prefectural Amagasaki General Medical Center
Amagasaki, Hyogo, Japan

Hiroaki Sakaib

Department of Thoracic Surgery, Hyogo Prefectural Amagasaki General Medical Center
Amagasaki, Hyogo, Japan

Kazumi Itoi

Department of Thoracic Surgery, Hyogo Prefectural Amagasaki General Medical Center
Amagasaki, Hyogo, Japan