

Treatment Of Chronic Airway Obstruction Secondary To Hypertrophy Of The Tori Tubarius In A Ten Year Old Male

M Greenberg, S Pransky, A Magit

Citation

M Greenberg, S Pransky, A Magit. *Treatment Of Chronic Airway Obstruction Secondary To Hypertrophy Of The Tori Tubarius In A Ten Year Old Male*. The Internet Journal of Otorhinolaryngology. 2005 Volume 5 Number 2.

Abstract

We describe a case of severe hypertrophy of the tori tubarius (TT) treated with coblation radiofrequency. The patient, a ten year old boy, had repeated bouts of nasal airway obstruction despite adenotonsillectomy. After coblation radiofrequency the TT hypertrophy is much improved and the patient is asymptomatic. Treatment of TT hypertrophy requires a conservative approach to prevent eustachian tube dysfunction.

INTRODUCTION

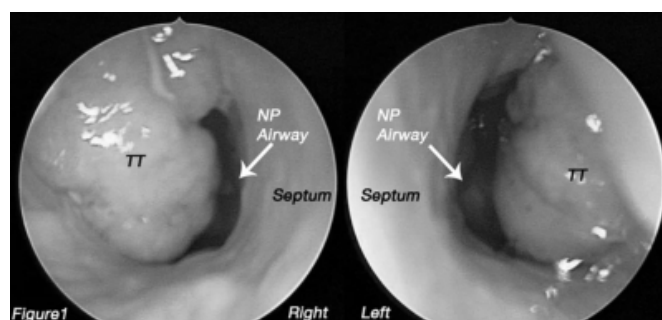
Chronic nasal obstruction can occur for a variety of reasons, including: adenoid hypertrophy, nasal septum abnormalities or trauma, polyps or tumors of the nose, turbinate edema and many congenital anomalies affecting the airway. The tori tubarius, structures that are the opening of the Eustachian tubes into the nasal pharynx are normally lateral to the adenoids. We describe a case of severe hypertrophy of the tori tubarius (TT), which required a carefully planned and executed treatment plan.

CASE REPORT

The patient was a ten-year-old male who had multiple operations for airway obstruction and was still experiencing symptoms of difficult nasal breathing. Initially the patient received bilateral myringotomy with tube placement at 13 months, and tonsillectomy and adenoidectomy at 3 years. Due to continued nasal obstruction he had inferior turbinate reduction at 5 and 6 years of age. During his second turbinate surgery at 6 years, he was noted to have hypertrophy of the TT. He had multiple evaluations for allergy and gastroesophageal reflux, which were unremarkable. He continued to have nasal obstruction, which had worsened over the prior six months. After extensive discussion with the family, it was decided to re-evaluate the nasal airway and attempt reduction of TT at surgery. After induction of general anesthesia and topical preparation of the nasal pharyngeal airway with oxymetazoline and 1% lidocaine with epinephrine, nasal endoscopy revealed extensive TT hypertrophy (figure 1).

Figure 1

Figure 1: Intra-operative photograph of the nasopharynx, highlighting the enlarged Tori Tubarius



To reduce the possibility of damage to the Eustachian tubes, it was decided to use Coblation radiofrequency instead of unipolar cautery. The Arthrocare coblation system (Sunnyvale, CA) was used for 15 seconds on a setting of '6', set to reduce the TT. Five separate lesions were used in each side. After the ablation there was minimal bleeding or swelling. There were no complications associated with the procedure.

Re-examination of the nasal airway 6 weeks later showed a significant decrease in swelling and increased patency of the posterior nasal airway. During this time the patients' symptoms significantly improved.

DISCUSSION

Normally the TT are part of a system where the eustachian tube functions to balance pressures between the middle ear and the pharynx. They are situated lateral to the choanae and must be carefully avoided during adenoidectomy (1). Injury

to the TT can cause persistent eustachian tube dysfunction (2). In rare cases such as this one, severe hypertrophy of these structures causes symptoms similar to adenoid hypertrophy. Radiofrequency ablation has been used as a way to atraumatically reduce the volume and size of the nasal turbinates, tonsils and adenoids (3,4,5,6,7). Use of this surgical modality to decrease the volume of the TT, is a novel and safe approach to an unusual cause of nasopharyngeal airway obstruction. In this case, surgical intervention required a great deal of judgment and planning given the unique circumstances of the airway obstruction.

It is difficult to know with certainty why the TT became so hypertrophic in this patient. It is known that nasal turbinate mucosa hypertrophies in response to allergic stimulation and also will enlarge to fill the volume of space within the nares when a septal deviation is present. It is not common to see TT hypertrophy after an adenoidectomy, but theoretically the mucosa of the TT could expand to fill the space vacated by the adenoids if excessive stimulation was present.

CORRESPONDENCE TO

Mark Greenberg, M.D. Department of Anesthesiology
UCSD Medical Center 200 West Arbor Dr. San Diego, Ca
92103-8770 Telephone: 619-543-5297 Fax: 619-543-5424
Email: mgreenberg@ucsd.edu

References

1. Hohn DJ, Deschler DG, Tucker JA. Central incisor width as a predictor of appropriate curette size in adenoidectomy. *Ann Otol Rhinol Laryngol.* 2001 Sep;110(9):841-3.
2. Saunders N.C., Hartley B.E.J., Sell D., Sommerlad B. Velopharyngeal insufficiency following adenoidectomy. (2004) *Clin. Otolaryngol.*29, 686-688
3. Shehata EM, Ragab SM, Behiry AB, Erfan FH, Gamea AM. Telescopic-assisted radiofrequency adenoidectomy: a prospective randomized controlled trial. *Laryngoscope.* 2005 Jan;115(1):162-6.
4. Bhattacharyya N, Kepnes LJ. Clinical effectiveness of coblation inferior turbinate reduction. *Otolaryngol Head Neck Surg.* 2003 Oct;129(4):365-71.
5. Chang KW. Randomized controlled trial of Coblation versus electrocautery tonsillectomy. *Otolaryngol Head Neck Surg.* 2005 Feb;132(2):273-80
6. Timms MS, Temple R. Coblation tonsillectomy: a double blind randomized controlled study. *J Laryngol Otol.* 2002 Jun;116(6):450-2.
7. Belloso A, Chidambaram A, Morar P, Timms MS. Coblation tonsillectomy versus dissection tonsillectomy: postoperative hemorrhage. *Laryngoscope.* 2003 Nov;113(11):2010-3.

Author Information

Mark Greenberg, M.D.

Associate Professor of Anesthesiology and Pediatrics, UCSD Medical Center, University of California

Seth M. Pransky, M.D.

Associate Professor of Otolaryngology, University of California, San Diego, Childrens Hospital and Health Center

Anthony Magit, M.D.

Associate Professor of Otolaryngology and Pediatrics, University of California, San Diego, Childrens Hospital and Health Center