

Clear Cell Myoepithelioma Of The Hard Palate

A Agarwal, A Sethi, S Chopra, D Sareen

Citation

A Agarwal, A Sethi, S Chopra, D Sareen. *Clear Cell Myoepithelioma Of The Hard Palate*. The Internet Journal of Head and Neck Surgery. 2006 Volume 1 Number 2.

Abstract

Salivary gland myoepitheliomas are rare tumours. We report the case of a 40-year-old female who presented to us with a hard palatal mass. The tumour was excised with a healthy rim of surrounding tissue. Histological and immunohistochemical analyses revealed the tumour to be a myoepithelioma of the clear cell variety.

INTRODUCTION

Myoepithelial cells are contractile cells derived from ectoderm and are seen in major and minor salivary glands, lacrimal glands, breast, sweat glands and prostate ¹. These cells are thought to be responsible for expulsion and propagation of secretions from the acini and through the ductal network of these tissues. These cells may assume several distinct forms- as a spindled, plasmacytoid, clear, stellate or a basket-like cell ². The tumours arising exclusively from these cells are rare and account for less than 1% of all salivary gland tumours ³. Most of these tumours have been reported in the parotid gland and minor salivary glands on the hard palate ⁴. Although, clear cell myoepitheliomas have been reported at other sites ^{5,6,7,8}, most of the cases of palatal myoepitheliomas have been plasmacytoid or spindle cell type ⁹. We did not find any report of a clear cell myoepithelioma of the hard palate in the review of medical literature. The extreme rarity of such an occurrence prompted us to report this case.

CASE REPORT

A 40-year-old female presented to us with a palatal mass of 6 months duration. It has been gradually increasing in size and was painless. The patient had no other significant complaints. The patient had history of chewing tobacco for the past 15 years. Examination of the oral cavity revealed a firm, non-tender, well-circumscribed mass located on the hard palate on the right side, measuring 2cmX 2cm with a partly ulcerated overlying mucosa (figure 1). Nicotine stains could be seen on the teeth. The patient had no trismus or cervical lymphadenopathy.

Routine hematological and urine analyses and chest X-ray

were normal. ELISA for HIV was non-reactive. A fine needle aspiration cytology (FNAC) of the tumour revealed a cellular minor salivary gland tumour suggestive of a pleomorphic adenoma. An enbloc excision of the tumour with a rim of surrounding normal mucosa was performed and subjected to histopathological evaluation. The postoperative period was insignificant and the patient is totally asymptomatic for the disease without any signs of recurrence one year postoperatively.

The specimen consisted of a firm, circumscribed tumour with a smooth external and a solid, tan cut surface. On light microscopy, it was found to be surrounded by a thick fibrous capsule. The tumour was uniformly composed of large polyhedral cells with glassy, clear eosinophilic cytoplasm arranged in closely packed interlacing bundles (Figure 2). The nuclei were round to oval, eccentrically placed and were vesicular with small nucleoli. Immunohistochemically, the clear cells were immunoreactive for cytokeratin, S-100 and muscle specific actin (MSA), and, non-reactive for epithelial membrane antigen (EMA), vimentin and carcinoembryonic antigen (CEA). A final diagnosis of clear cell myoepithelioma of the hard palate was made.

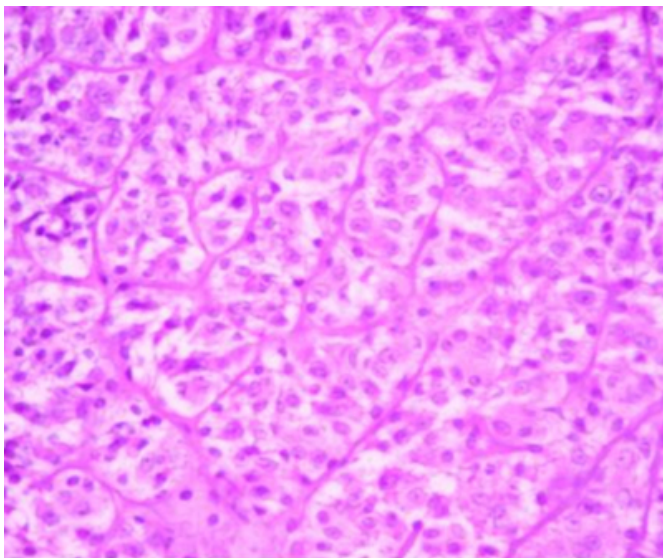
Figure 1

Figure 1: showing a partly ulcerated right palatal mass.

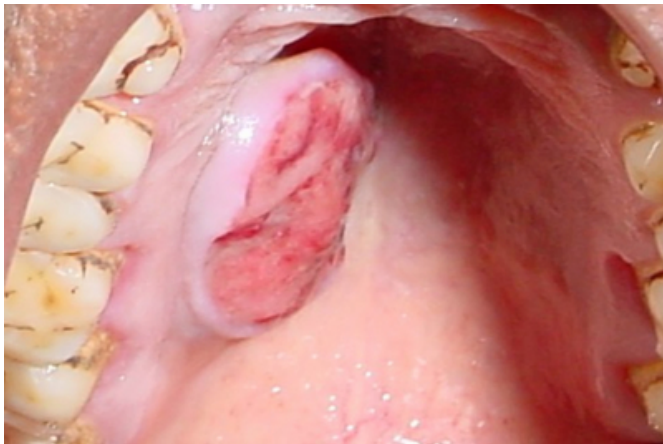

Figure 2

Figure 2: showing large, polyhedral cells with clear eosinophilic cytoplasm and round to ovoid nucleus (H & E staining, 400X).



DISCUSSION

Myoepitheliomas are rare, generally benign tumours with the parotid gland and palate accounting for three-fourths of all cases². The age range is wide, and there is no significant gender predisposition of this tumour^{2,4}. The plasmacytoid variant appears to have a predilection for the palate in slightly younger individuals, while the spindle cell type tends to occur in the parotid gland of older individuals^{5,6}. On the other hand, clear cell tumours of the salivary glands are almost invariably malignant in nature, with rare exceptions in the form of myoepitheliomas and oncocytomas⁶. When benign, the tumour most often presents as an asymptomatic mass that slowly enlarges over a course of

several months to years. Parotid lesions never produce facial dysfunction and those of the palate rarely ulcerate². Our patient had a history of 6 months with a partly ulcerated, slowly growing mass.

Pathologically, myoepitheliomas vary from 1 to 5 cms in greatest dimensions and are well demarcated with a smooth, sometimes bosselated external appearance and a uniform white, tan or gray cut surface. They are generally encapsulated except for palatal myoepitheliomas, which may or may not have a capsule². In our patient, the tumour measured 2cm X 2cm and was encapsulated. Microscopically, primarily spindle-shaped cells, occasionally plasmacytoid cells, or a combination of these two cell types constitutes these tumours, with the stellate and clear cell variants as rare².

Immunohistochemically, a large number of markers have been used for establishing the diagnosis of myoepitheliomas. The myoepithelial cells are usually found to be immunoreactive to S-100, actin and prekeratin, and are non-reactive to desmin and EMA. Other markers that have been used in some reports are CEA, secretory piece, high molecular weight keratin, cytokeratin and factor VIII antigen⁹. The reactivity to MSA and vimentin has been reported variably in different reports^{2,4,10}. In our patient, the tumour cells were found to be immunoreactive to MSA, S-100 and cytokeratin and negative for vimentin and EMA. There is a close correlation between histological appearance and prognosis. Tumours showing a more aggressive behaviour are mitotically active, more anaplastic and contain fewer myofilaments. Cellular pleomorphism, increased mitotic activity, necrosis and invasion indicate towards possibility of malignancy². These features were absent in our case. Wide local excision with a rim of surrounding normal tissue is considered the treatment for myoepitheliomas. Our patient also underwent similar treatment without any evidence of recurrence one year following the surgery.

In conclusion, myoepitheliomas of the salivary glands are uncommon tumours with clear cell variants still rarer. In our review of medical literature, we did not come across any report of a palatal clear cell myoepithelioma. The diagnosis of these tumours is based on a combination of routine microscopy as well as immunocytochemistry. The treatment is surgical with wide local excision.

LEARNING POINTS

1. Myoepitheliomas are rare benign tumours arising from myoepithelial cells that are contractile cells

present in minor and major salivary glands.

2. These tumours are difficult to diagnose on routine histochemical staining and require immunohistochemical staining for diagnosis.
3. The clear cell variants of myoepitheliomas are extremely rare on the palate with no case reported in the pertinent medical literature in the past.
4. Wide local excision is usually curative.

CORRESPONDENCE TO

Dr Ashwani Sethi E-80, Naraina Vihar New Delhi-110028, INDIA. Phone No: 91-11-9811338978 E mail- dr_sethi@rediffmail.com

References

1. Hamperl H. The myoepithelia (myoepithelial cells). Normal state; regressive changes; hyperplasia; tumors. *Curr Topics Pathol* 1970; 53: 161-220.
2. Barnes L, Appel BN, Perez H and El-Attar AM.

Myoepitheliomas of the head and neck: case report and review. *J Surg Oncol* 1985; 28: 21-28.

3. Scuibba JJ and Brannon RB. Myoepithelioma of salivary glands. Report of 23 cases. *Cancer*; 1982; 49: 562-572.

4. Ellyn JEW and Gnepp DR. Myoepithelioma of the palate in a child. *Int J Pediatr Otolaryngol* 1986; 11: 5-13.

5. De Steffani A, Lerda W, Bussi M, Valente G and Cortesina G. Tumours of the parapharyngeal space: case report of clear cell myoepithelioma of the parotid gland and review of literature. *Acta Otolaryngol Ital* 1999; 19(5): 276-282.

6. Maiorano E, Altini M and Favia G. Clear cell tumors of the salivary glands, jaws and oral mucosa. *Semin Diagn Pathol* 1997; 14(3): 203-212.

7. Son HJ, Jung SH, Lee SY and Moon WS. Glycogen-rich clear cell mammary malignant myoepithelioma. *Breast* 2004; 13(6): 506-509.

8. Boniuk M and Halpert B. Clear cell hidradenoma or myoepithelioma of the eyelid. *Arch Ophthalmol* 1964; 72: 59-63.

9. Kanazawa H, Furuya T, Watanabe T and Kato J. Plasmacytoid myoepithelioma of the palate. *J Oral Maxillofac Surg* 1999; 57: 857-860.

10. Das DK, Haji BE, Ahmed MS and Hossain MNR. Myoepithelioma of the parotid gland initially diagnosed by Fine Needle Aspiration Cytology and Immunocytochemistry. A case report. *Acta Cytol* 2005; 49: 65-70.

Author Information

A. K. Agarwal, M.S.

Director Professor , Dean, Department of ENT, M.A.M.C. and associated L.N.Hospital

Ashwani Sethi, M.S.

Senior Resident, Department of ENT, M.A.M.C. and associated L.N.Hospital

Shamit Chopra, M.B.B.S.

Junior Resident, Department of ENT, M.A.M.C. and associated L.N.Hospital

Deepika Sareen, M.B.B.S.

Junior Resident, Department of ENT, M.A.M.C. and associated L.N.Hospital