

Medical Images: Aortic Dissection

B Phillips

Citation

B Phillips. *Medical Images: Aortic Dissection*. The Internet Journal of Internal Medicine. 2002 Volume 3 Number 2.

Abstract

This case is presented to show images obtained from a patient with aortic dissection.

CASE

64 yr. old Hispanic male with type II diabetes and an otherwise negative past medical history (normotensive) began experiencing dull chest pain and dyspnea 2 days prior to admission. On the morning of admission, his symptoms progressed to include light-headedness and an episode of syncope. His wife & family brought him to the emergency room.

Physical examination revealed a lethargic, confused, elderly male with a BP of 77/52 mmHg, Pulse 118 and 86 % sat. on room air. He was placed on 2 liters of supplemental O₂ and given 2 liters of crystalloid solution intravenously. Within 30 minutes of his arrival, and after the above measures, the patient was awake, alert & oriented with a BP 112/68, Pulse 86, and 98 % saturation.

The dissection was treated surgically.

DIAGNOSTIC STUDIES

Figure 1

Figures 1 and 2: widened mediastinum"

3 months prior to admission day of admission

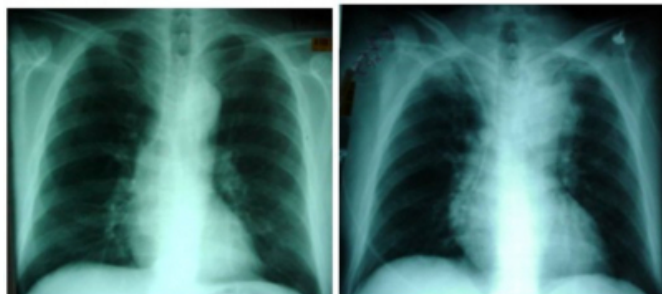

Figure 2

Figures 3 and 4: Chest C.T: "Aortic dissection"

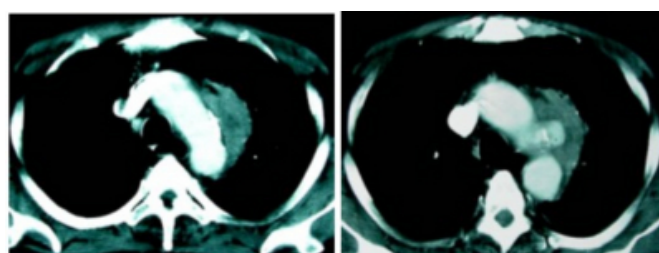


Figure 3

Figures 5 and 6: Arteriogram: "Ruptured Aorta with pseudoaneurysm"

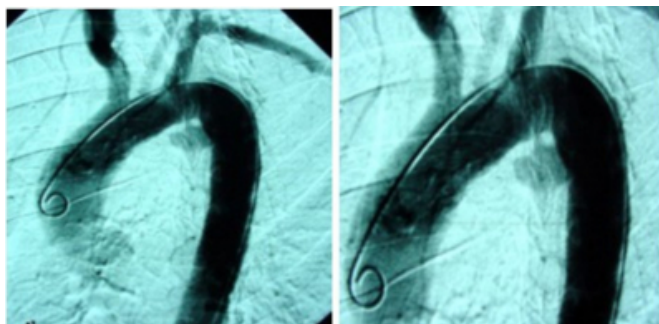


Figure 4

Figure 7: TEE - Cross-sectional view “Ulcerated plaque with a mobile flap”

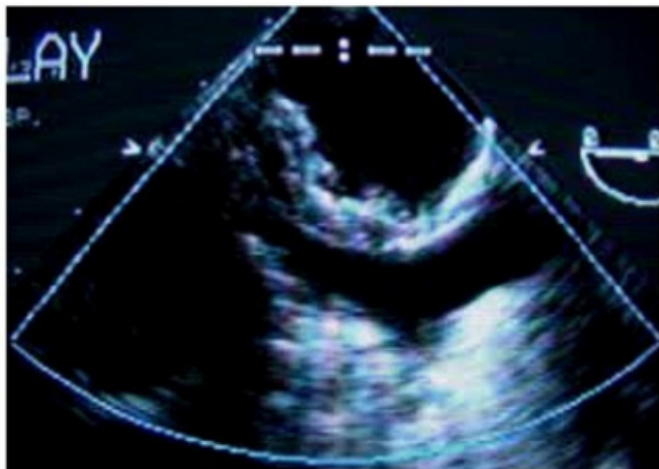
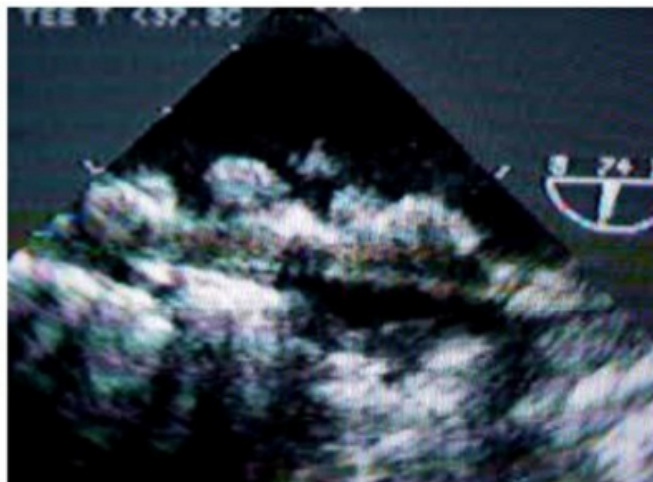


Figure 5

Figure 8: TEE - Longitudinal view



References

Author Information

Bradley J. Phillips, MD

Dept. of Trauma & Critical Care , Boston University School of Medicine , Boston Medical Center