

# Non-Accidental Injury In Children: The Orthopaedic Aspect

M U Christmas

## Citation

M U Christmas. *Non-Accidental Injury In Children: The Orthopaedic Aspect*. The Internet Journal of Pediatrics and Neonatology. 2020 Volume 22 Number 1.

DOI: [10.5580/IJPN.55410](https://doi.org/10.5580/IJPN.55410)

## Abstract

Non-accidental injury (NAI), sometimes referred to as “the battered child syndrome” or simply, physical child abuse has been an old social and medical problem that has plagued our societies for a very long time and still is a major cause of disability among our children. The diagnosis of non-accidental injury is seldom easy to make and requires a careful consideration of socio-behavioural factors and clinical findings (1). In reality, the possibility of child abuse is often overlooked in clinical practice (2). Fractures are the second most common presentation of physical abuse after skin lesions, and more than a quarter of abused children will eventually be seen by an orthopaedic surgeon (3-5). Thus, it is essential that the orthopaedic surgeon has a clear understanding of the manifestations of physical abuse, to increase awareness, recognition and appropriate management.

There is no pathognomonic fracture pattern in abuse. Rather, the age of the child, the overall injury pattern, the stated mechanism of injury and pertinent psychosocial factors must all be considered in each case (1). The differential diagnosis of NAI includes other conditions that may cause fractures but, are not limited to accidental injury, birth trauma, osteogenesis imperfecta, metabolic bone disease, congenital syphilis, leukemia and coagulation disorders. Management should be multidisciplinary, with the key being recognition, as children suffering from NAI have a substantial risk of repeated physical abuse and death. A case is presented focusing on the physical abuse with particular emphasis on fractures.

## CASE REPORT

A seventeen-month old male child was brought to the Accident and Emergency department by his twenty-year old unemployed mother with a one-day history of discolouration around the left eye with associated periorbital swelling. The exact mechanism of injury was uncertain but mom assumed that the child had fallen in her absence and hit his face on a hard object resulting in bruising. This history was not unusual for her, as the child had apparently fallen in the past. There was no history of loss of consciousness, vomiting, seizure like activity, anorexia, lethargy, ear, nose or throat bleeding. She reported that though he remained active, he was quite fussy. She also revealed that both parents and occasionally the grandmother were the only adults that looked after the child.

On examination, an unkempt, mildly undernourished, male child was seen in no obvious distress however, he appeared generally fussy and would cry intermittently for no apparent reason. His salivary pool was mildly decreased and several crusted lesions were noted on his upper and lower limbs with some evidence of infection to some of these lesions. There

was mild swelling of his left upper eyelid with surrounding ecchymosis, the classical raccoon’s eye. The eyeball itself was unremarkable and visual acuity appeared preserved. There was no sclera discolouration and he had normal dentition for his age. There were no lateralizing signs detected, however in his musculoskeletal examination, he was found to be guarding his right lower limb which was swollen and tender around the ankle with decreased function. Mild swelling and tenderness were also found at the right proximal arm however, he was moving the limb comfortably. A non-tender, bony hard swelling was palpable over the middle one third of the left clavicle. He was assessed as malnutrition with head injury secondary to a fall, to rule out a base of skull fracture. A case of coagulopathy and suspected child abuse were two other differential diagnoses entertained.

The child received an intravenous access for hydration and was investigated with a full blood count, bleeding indices with blood film and white cell differential. Electrolytes, urea, creatinine, proteins and liver function tests were also done as initial investigations. He was radiographically

investigated with a skeletal survey and a computerized tomography scan of the brain was ordered. Blood investigations showed a microcytic, hypochromic anaemia with decreased albumin and an elevated urea. The skeletal survey revealed:

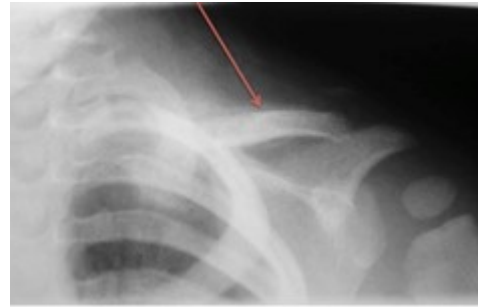
- Minimally displaced fracture of the left mid clavicle with exuberant callus formation
- Acute undisplaced spiral fracture through the proximal shaft of the right humerus
- Old healed fracture of the anterior angle of the fifth left rib
- Old healed fracture of the posterior angle of the right ninth rib
- Possible healed fracture of the posterior angle of the right eighth rib
- Acute transverse fractures through the distal metaphyses of the right tibia and fibula with periosteal reaction of the tibia indicating subperiosteal haemorrhage (See figures below).

The CT brain was an unremarkable study with no fractures or acute intracranial pathology detected.

The child was admitted to the ward with a diagnosis of non-accidental injury and malnutrition. The patient was referred to the orthopaedic surgical team for assessment and management of his fractures. There was no gross movement at the proximal right humeral fracture on examination and a decision was made to treat conservatively, out of a cast. His right lower limb was placed in a below knee, Plaster of Paris cast and he was commenced on oral analgesia. Both parents were thoroughly interviewed after discussion of the findings. Mother and father denied any knowledge of abuse and confirmed that the grandmother is the only other adult who cares for the child. The social worker and the Child Development Agency were invited to investigate the case. The child spent a total of eight weeks in hospital during which his malnourished state and fractures were addressed and was subsequently discharged to a children's home with supervised visitation of the parents. One year follow up revealed a healthy, relatively playful child with no functional deficits from his multiple fractures.

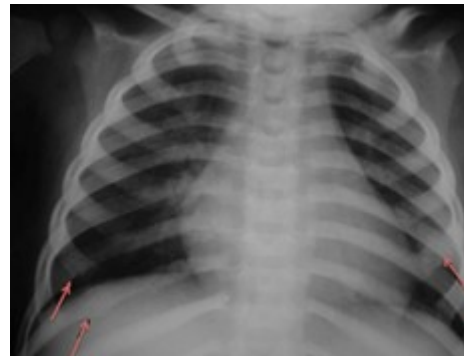
**Figure 1**

Figures 1-6. Plain radiographs showing multiple fractures in different stages of healing (red arrows)



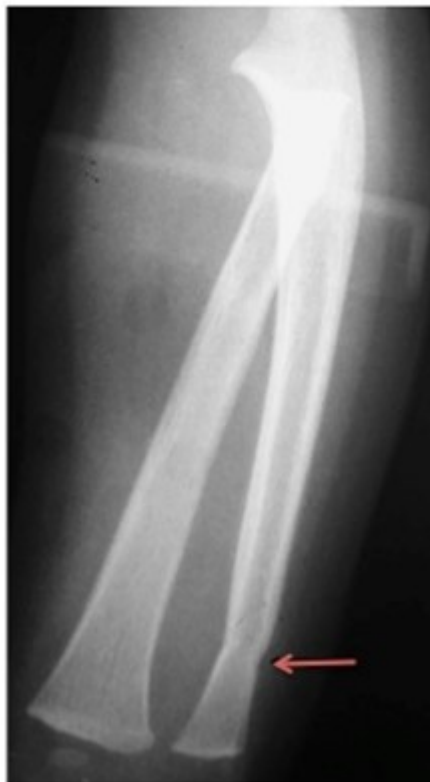**Figure 2**

Figures 1-6. Plain radiographs showing multiple fractures in different stages of healing (red arrows)



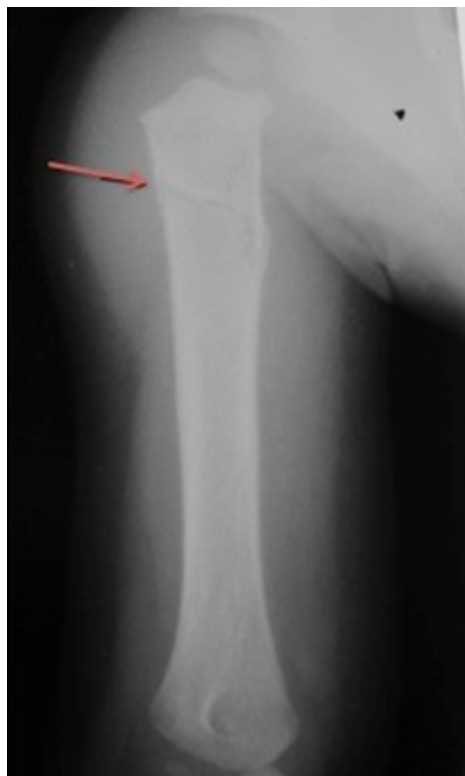**Figure 3**

Figures 1-6. Plain radiographs showing multiple fractures in different stages of healing (red arrows)



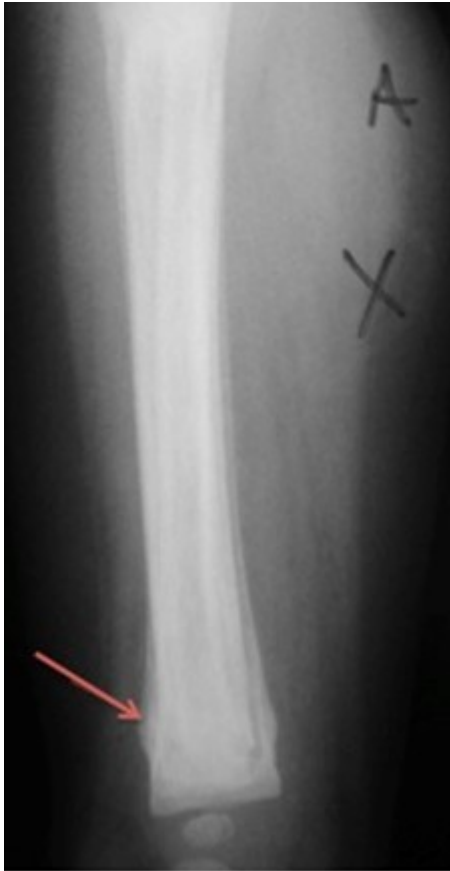**Figure 4**

Figures 1-6. Plain radiographs showing multiple fractures in different stages of healing (red arrows)



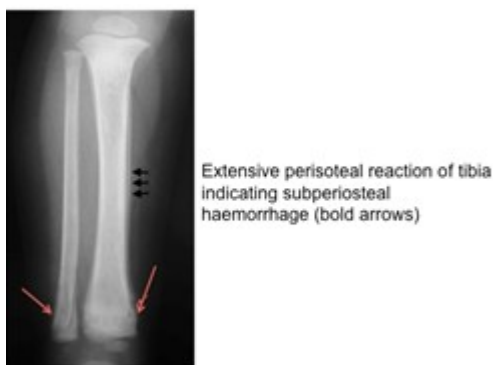**Figure 5**

Figures 1-6. Plain radiographs showing multiple fractures in different stages of healing (red arrows)



**Figure 6**

Figures 1-6. Plain radiographs showing multiple fractures in different stages of healing (red arrows)



## DISCUSSION

Non-accidental injury or child maltreatment as it is now referred to, was uniformly defined by the Centre for Disease Control and Prevention in 2008 as “any act or series of acts of commission or omission by a parent or other caregiver that results in harm, potential for harm, or threat of harm to a child” (6). The diagnosis of child maltreatment is not easy to

make and manifestations of physical abuse involve the entire child, therefore a thorough history and a complete examination are essential. The abuse of children is a universal problem, affecting children from all social classes, races and religious groups. The surgeon who is suspicious of abuse should not only notify the appropriate state agencies as required by law but, because of the association between parental stress and maltreatment, the proactive paediatric Orthopaedic surgeon should also strongly consider referring the parents or guardians to social services for counselling (7). Demographic analysis has shown that those most at risk for maltreatment include first-born children, unplanned children, premature infants, stepchildren, and handicapped children. In addition, children of single-parent homes, drug abusing parents, parents who were themselves abused, unemployed parents, and families of lower socioeconomic status were shown to be at increased risk (8, 9). Many of these risk factors mentioned can easily be identified in the index case. Failure to recognize injuries due to child abuse can be fatal (10). Children who have been physically abused represent a small proportion of the total number of childhood fractures. Most children who sustain fractures do so from falls, motor vehicle accidents, or other non-abusive trauma (11). However, although abuse is common, it may be difficult to discern the true cause of an injury and it is estimated that approximately 7% of children who have signs suggestive of abuse actually have an underlying medical condition that explains their injuries (12). Medical conditions such as osteogenesis imperfecta, metabolic bone disease, congenital syphilis, leukemia and coagulation disorders are some of the more common conditions mimicking fractures in physically abused children. Fractures are second only to bruising in frequency with physical abused children (13). Skeletal fractures are diagnosed in up to a third of children who have been investigated for physical abuse (14). Fractures from abuse are more common in younger children, who are at greater risk because of the diminished structural and mechanical properties of the developing skeleton and because they are demanding, defenseless, and non-verbal. In addition, long-bone fractures in pre-ambulatory infants in the absence of metabolic bone disease are more often inflicted than accidental (1). Coffey et al in a retrospective case series of 4942 children demonstrated that nearly one third of children younger than 18 months old admitted to the trauma service were victims of child abuse. Furthermore, nearly 75% of patients younger than 18 months with a lower extremity fracture were injured because of child abuse (15). In another retrospective analysis

of 467 children presenting or referred with a suspicion of non-accidental fractures, Carty et al found that 91% were less than 2 years old (16). The index case falls into the category of children with the highest incidence of skeletal trauma due to physical abuse.

Skeletal survey and bone scintigraphy are utilized in imaging for identification of skeletal injuries in cases of suspected child abuse. Utilization of both imaging modalities allows increased identification and documentation of these injuries (17). The British Society of Paediatric Radiology and the American Academy of Paediatrics (AAP) Guidelines state that a skeletal survey should be mandatory in all cases of suspected physical abuse in children less than 2 years. The AAP recommends that both skeletal survey and bone scan have little value as a screening examination in children over 5 years of age. The 2–5-year age group should be handled on an individual case basis (18). However, in recent times, the optimal investigation strategy to identify all fractures in children with suspected abuse was deemed to include a skeletal survey including oblique views of the chest, which has a much higher sensitivity for identifying rib fractures than a standard chest radiograph (19, 20). Skeletal survey is useful in documenting and dating multiple episodes of trauma (21). Bone Scintigraphy on the other hand, is deemed more sensitive than skeletal surveys especially in detecting any occult injuries, rib and long bone fractures. A bone scan however requires radionuclide exposure, lacks specificity, requires sedation, is not readily available, has limited expertise, is more expensive and time consuming. It is also difficult to detect epiphysio-metaphyseal injuries due to normally increased activity in these areas in childhood (22). Repeat radiographs of doubtful areas should be obtained after one to two weeks, to identify callus (to assist with approximate dating of injuries) and previously occult injuries (23).

No fracture, on its own, can distinguish an abusive from a non-abusive cause. During the assessment of individual fractures, the site, fracture type, and developmental stage of the child can help to determine the likelihood of abuse (24). Multiple fractures in different stages of healing and unusual fractures should alert the orthopaedic surgeon to non-accidental injury (11). Worlock et al found a highly significant association between multiple fractures in the absence of metabolic bone disease, and abuse. In their study seventy-four (74%) percent of abused children had two or more fractures compared with sixteen (16%) percent of non-abused children (25). Single fractures do occur in NAI,

however these are usually found in older children. Therefore, it is not wise for the orthopaedic surgeon to assume that a single fracture is as a result of non-abusive trauma. Almost every fracture has been described in NAI, however the commonest fractures patterns occur in the femur, humerus and ribs. Each fracture identified in physically abused children has been studied with respect to the degree of specificity in NAI (26). O'Connor et al in their study on dating fractures assessed the specificity of musculoskeletal radiologic findings in child abuse as follows:

### **High specificity**

- Metaphyseal corner lesions
- Posterior rib fractures
- Scapular fractures
- Spinous process fractures
- Sternal fractures

### **Moderate specificity**

- Multiple fractures
- Fractures of different ages
- Physeal separations
- Vertebral body fractures
- Digital fractures
- Complex skull fractures

### **Low specificity**

- Clavicle fractures
- Long bone shaft fractures (femur, tibia, humerus)
- Linear skull fractures

Some of the more important and common fracture patterns observed in NAI are discussed. In the absence of a confirmed traumatic cause, rib fractures have the highest probability (71%) of being caused by abuse. Humeral fractures have a one in two chance of being the result of abuse, and for femoral or skull fractures, the estimated probability is one in three (24).

Metaphyseal corner lesions have been thought for a very long time to be the most valuable single sign of non-

accidental injury (27). The most subtle indication of injury is a transverse lucency within the sub-epiphyseal region of the metaphysis. The fracture may be visible in only one projection and its appearance is influenced by the severity of the bony injury, the degree of displacement of the fragments and the chronicity of the process (28).

In the absence of prematurity, birth injury, metabolic disorders, bone dysplasias and major trauma such as road traffic accidents, rib fractures can be considered almost specific for abuse. Rib fractures are common in physical abuse and can result from anteroposterior (AP) or lateral compressive forces associated with squeezing, direct impact from striking, or oscillation and compression during violent shaking (1). Literature review on the location of rib fractures does not confirm the widely held belief that posterior fractures are discriminators for abuse. However, multiple rib fractures in any location, in the absence of overt trauma, are strongly associated with abusive injury (24).

Femoral fractures are quite common, occurring more commonly in the younger age groups. It was once thought that mid-shaft spiral fractures due to a twisting force were characteristic of child abuse however, transverse fractures are also very common among abused children. In fact, there has been no real difference in patterns of diaphyseal fractures of the femur between abuse and non-abuse (15, 29). Tornetta et al retrospectively reviewed 456 fractures in two level I paediatric trauma centres and found that a transverse fracture of the femur was in fact the commonest pattern seen in abuse cases overall but was under-represented in those referred for investigation. They concluded that this suggests that practitioners are more likely to view transverse fractures as accidental and have a lower index of suspicion for abuse in these cases (30). Such bias may lead to missed cases of abuse in children with transverse fractures. Importantly, Schwend et al looked at motor milestones and it was found that femoral fractures from abuse were significantly more common in children who were not walking (31).

Supracondylar fractures were more likely to be associated with non-abusive injury. This was confirmed in a large cross sectional study that looked specifically at displaced supracondylar fractures in 388 children of all ages. Seventy nine per cent of these fractures occurred after a fall, and only 0.5% were the result of abuse. The authors cautioned that a supracondylar fracture should not be assumed to have non-abusive causes without careful consideration. The most common type of humeral fracture from abuse in children

under 15 months of age was a spiral/oblique fracture.

Physical abuse should be considered in the differential diagnosis when an infant (under 18 months) presents with a fracture in the absence of an overt history of important trauma or a known medical condition that predisposes to bone fragility. The following indicators can be used to inform decisions about the likelihood of child abuse:

- Multiple fractures are more common after physical abuse than after non-abusive

traumatic injury

- A child with rib fractures has a 7 in 10 chance of having been abused

- A child with a femoral fracture has a 1 in 3-4 chance of having been abused

- Femoral fractures resulting from abuse are more commonly seen in children who are not yet walking

- A child younger than three years with a humeral fracture has a 1 in 2 chance of having been abused

- Mid-shaft fractures of the humerus are more common in abuse than in non-abuse,

whereas supracondylar fractures are more likely to have non-abusive causes

## CONCLUSION

We know that children who have been physically abused often sustain bony fractures and different fracture types have variously been described as having a high probability for abuse. However, no one fracture in isolation is specific for physical abuse. Rib fractures, regardless of type, are highly suggestive of abuse in the absence of an overt traumatic or organic cause. Fractures from child abuse are significantly more common in children under 18 months of age than in older children. In this younger age group, any significant injury to the lower extremity that lacks a plausible mechanism merits a thorough investigation. The case presented above was investigated because of a high index of suspicion but in retrospect one would realize that there were several indicators in his environment that increased his risk of non-accidental injury. He was the result of an unplanned pregnancy and the first born to a young unemployed mother. In addition he presented with multiple fractures including multiple rib fractures at different stages of healing. Unexplained fractures are of particular concern as missing

these potential cases of NAI can lead to serious morbidity and mortality.

### References

1. Kocher MS, Kasser JR. Orthopaedic aspects of child abuse. *J Am Acad Orthop Surg*. 2000 Jan-Feb;8(1):10-20.
2. Taitz J, Moran K, O'Meara M. Long bone fractures in children under 3 years of age: is abuse being missed in Emergency Department presentations? *J Paediatr Child Health*. 2004 Apr;40(4):170-4.
3. McMahon P, Grossman W, Gaffney M, Stanitski C. Soft-tissue injury as an indication of child abuse. *J Bone Joint Surg Am*. 1995 Aug;77(8):1179-83.
4. Akbarnia BA, Akbarnia NO. The role of orthopedist in child abuse and neglect. *Orthop Clin North Am*. 1976 Jul;7(3):733-42.
5. Loder RT, Feinberg JR. Orthopaedic injuries in children with nonaccidental trauma: demographics and incidence from the 2000 kids' inpatient database. *J Pediatr Orthop*. 2007 Jun;27(4):421-6.
6. Uniform definitions for public health and recommended data elements Centre for Disease Control and Prevention Jan 2008.
7. Sullivan PM, Knutson JF. Maltreatment and disabilities: a population-based epidemiological study. *Child Abuse Negl*. 2000 Oct;24(10):1257-73.
8. Kempe CH, Silverman FN, Steele BF, Droegemueller W, Silver HK. The battered-child syndrome. *JAMA*. 1962 Jul 7;181:17-24.
9. Rosenberg N, Bottenfield G. Fractures in infants: a sign of child abuse. *Ann Emerg Med*. 1982 Apr;11(4):178-80.
10. Jenny C, Hymel KP, Ritzen A, Reinert SE, Hay TC. Analysis of missed cases of abusive head trauma. *JAMA*. 1999 Feb 17;281(7):621-6.
11. Rennie L, Court-Brown CM, Mok JY, Beattie TF. The epidemiology of fractures in children. *Injury*. 2007 Aug;38(8):913-22.
12. Wardinsky TD, Vizcarrondo FE, Cruz BK. The mistaken diagnosis of child abuse: a three-year USAF Medical Center analysis and literature review. *Mil Med*. 1995 Jan;160(1):15-20.
13. Lynch A. Child abuse in the school-age population. *J Sch Health*. 1975 Mar;45(3):141-8.
14. Belfer RA, Klein BL, Orr L. Use of the skeletal survey in the evaluation of child maltreatment. *Am J Emerg Med*. 2001 Mar;19(2):122-4.
15. Coffey C, Haley K, Hayes J, Groner JJ. The risk of child abuse in infants and toddlers with lower extremity injuries. *J Pediatr Surg*. 2005 Jan;40(1):120-3.
16. Carty H, Pierce A. Non-accidental injury: a retrospective analysis of a large cohort. *Eur Radiol*. 2002 Dec;12(12):2919-25.
17. Mandelstam SA, Cook D, Fitzgerald M, Ditchfield MR. Complementary use of radiological skeletal survey and bone scintigraphy in detection of bony injuries in suspected child abuse. *Arch Dis Child*. 2003 May;88(5):387-90; discussion -90.
18. American Academy of Pediatrics. Section on Radiology: Diagnostic imaging of child abuse. *Pediatrics*. 1991 Feb;87(2):262-4.
19. Standards for Radiological Investigations of Suspected Non-Accidental injury. London: Royal College of Radiologists/Roya College of Paediatrics and Child Health 2008.
20. Ingram JD CJ, Hay TC, Strain JD, McKenzie T, Mueller CF. Oblique radiographs of the chest in non-accidental trauma. *Emerg Radiol*. 2000;7:42-6.
21. Ellerstein NS, Norris KJ. Value of radiologic skeletal survey in assessment of abused children. *Pediatrics*. 1984 Dec;74(6):1075-8.
22. Jaudes PK. Comparison of radiography and radionuclide bone scanning in the detection of child abuse. *Pediatrics*. 1984 Feb;73(2):166-8.
23. Mok JY. Non-accidental injury in children--an update. *Injury*. 2008 Sep;39(9):978-85.
24. Kemp AM, Dunstan F, Harrison S, Morris S, Mann M, Rolfe K, et al. Patterns of skeletal fractures in child abuse: systematic review. *BMJ*. 2008;337:a1518.
25. Worlock P, Stower M, Barbor P. Patterns of fractures in accidental and non-accidental injury in children: a comparative study. *Br Med J (Clin Res Ed)*. 1986 Jul 12;293(6539):100-2.
26. O'Connor JF CJ. Dating Fractures. In: Wilkins Wa, editor. *Diagnostic Imaging of Child Abuse*. PK ed. Baltimore: Kleinman; 1987. p. 103.
27. Caffey J. The parent-infant traumatic stress syndrome; (Caffey-Kempe syndrome), (battered babe syndrome). *Am J Roentgenol Radium Ther Nucl Med*. 1972 Feb;114(2):218-29.
28. Chapman S. Radiological aspects of non-accidental injury. *J R Soc Med*. 1990 Feb;83(2):67-71.
29. Kowal-Vern A, Paxton TP, Ros SP, Lietz H, Fitzgerald M, Gamelli RL. Fractures in the under-3-year-old age cohort. *Clin Pediatr (Phila)*. 1992 Nov;31(11):653-9.
30. Scherl SA, Miller L, Lively N, Russinoff S, Sullivan CM, Tornetta P, 3rd. Accidental and nonaccidental femur fractures in children. *Clin Orthop Relat Res*. 2000 Jul(376):96-105.
31. Schwend RM, Werth C, Johnston A. Femur shaft fractures in toddlers and young children: rarely from child abuse. *J Pediatr Orthop*. 2000 Jul-Aug;20(4):475-81.

**Author Information**

**Maxim U. S. I. Christmas, BSc. MBBS, DM (Orthopaedics); Consultant Orthopaedic Surgeon**

Division of Orthopaedic Surgery Department of Surgery, Radiology, Anaesthesia and Intensive Care The University Hospital  
of The West Indies

Kingston, Jamaica