

Urgent Carotid Endarterectomy For Acute Cerebral: A Trinidad Experience

A Esack, M Ramdass, D Maharaj, A Naraynsingh, S Teelucksingh, V Naraynsingh

Citation

A Esack, M Ramdass, D Maharaj, A Naraynsingh, S Teelucksingh, V Naraynsingh. *Urgent Carotid Endarterectomy For Acute Cerebral: A Trinidad Experience*. The Internet Journal of Surgery. 2002 Volume 4 Number 1.

Abstract

A brief report of 3 patients with acute stroke undergoing urgent Carotid Endarterectomy under local-regional anaesthesia are presented.

In cases with acute or evolving ischaemic stroke, a narrow time window exists between neuronal cell ischaemia and cell death. The stroke outcome is largely dependent on management strategies during this time interval. Treatments may include anti-thrombotic and reperfusion therapy and medication for neuronal protection [1]. Reperfusion of existing ischaemic areas may either be accomplished through thrombolysis with drugs such as recombinant tissue plasminogen activator (rTPA)[2] or carotid endarterectomy (CEA) where there is significant ipsilateral carotid stenosis. For about a decade now, it has been established that CEA significantly reduces the stroke risk in patients with symptomatic carotid stenosis [3,4]. However, controversy has surrounded the use of urgent CEA for acute cerebral ischaemia [5], the major fear being conversion of cerebral ischaemia into haemorrhage with worsening of the neurologic state.

Three patients undergoing urgent CEA under local anaesthesia are presented. Two had stroke in evolution and one had a crescendo transient ischaemic attack. Fresh clot was found at the site of occlusion in 2 cases and all 3 patients had a full recovery.

CASE 1

A 51-year old woman with a history of angina, hypercholesterolaemia and heavy smoking presented with severe right retro-orbital pain. Examination on first consultation revealed a blood pressure of 140/90 mmHg. A right carotid bruit was noted and the neurological examination at that time was normal. Twelve hours later the patient complained of numbness and grade 4 power of the

left upper limb with mild left facial weakness. Computed tomography brain scanning (CT) showed a small area of infarction in the right frontal region and carotid duplex scanning showed significant stenosis of the left internal carotid artery. Over the ensuing 12 to 24 hours, the patient's neurological status deteriorated with further weakness of the left upper limb and left lower limb. She underwent urgent left CEA. At operation, the left internal carotid artery was 90% occluded and fresh clot was noted association with the plaque. The patient showed rapid improvement with the disappearance of the retro-orbital pain post-operatively and her neurological status was normal at one week.

Figure 1

Figure 1: Carotid bifurcation before endarterectomy.

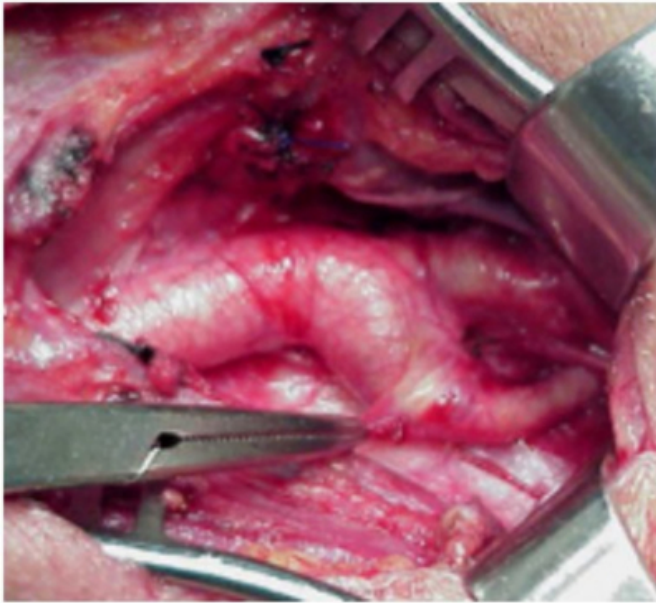


Figure 2

Figure 2: Carotid endarterectomy in progress. Plaque can be seen in the lumen of the common carotid artery and the internal carotid artery.

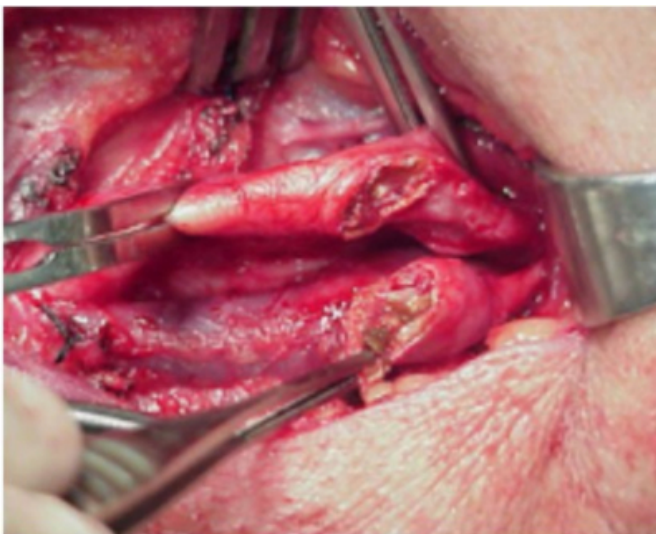

Figure 3

Figure 3: Eversion Carotid endarterectomy in progress.

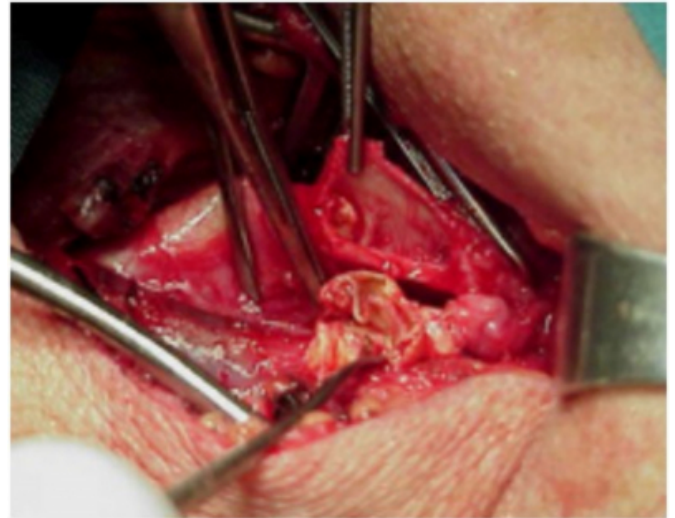


Figure 4

Figure 4: Carotid bifurcation after repair of endarterectomy at the junction of the common carotid and internal carotid vessels.

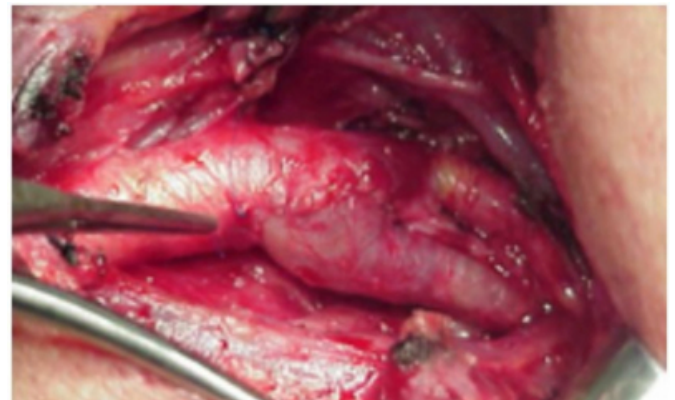


Figure 5

Figure 5: Doppler ultrasound done prior to surgery Showing the plaque and thrombus as a 'white' area Within the internal carotid artery lumen.

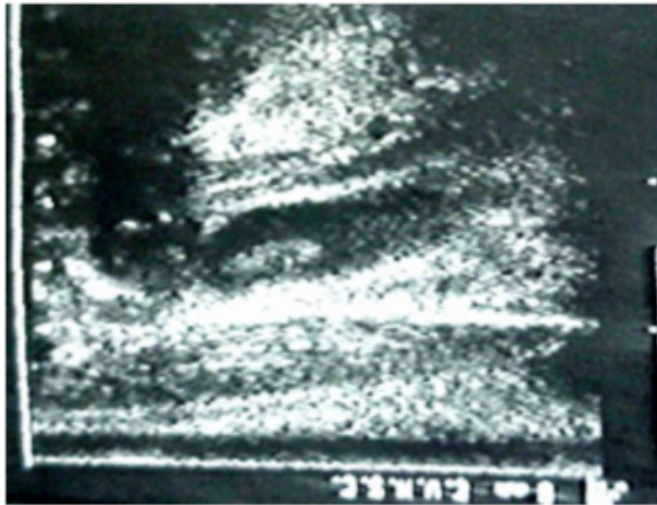
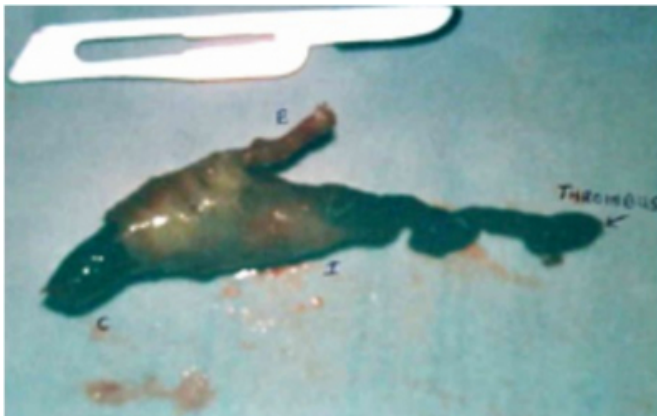

Figure 6

Figure 6: Picture showing the plaque (yellow area) With the acute thrombus (dark red area) extending through It from the common carotid to the internal carotid artery.



CASE 2

A 72-year old hypertensive lady was admitted with mild dysphasia and a grade 4 right hemiparesis. Her blood pressure was 160/90 mmHg and bilateral carotid bruits were noted. A CT brain scan was normal and carotid dopplers showed bilateral carotid occlusion with critical stenosis of the left internal carotid artery.

On the day of admission, the patient's neurological state fluctuated significantly and she developed acute transient periods of grade 1 to grade 2 weakness of the right side along with more profound dysphasia. Intravenous heparin was started and the patient's condition deteriorated. At emergency CEA the left internal carotid artery was almost

completely occluded with fresh clot adherent to the plaque. There was a striking improvement in power and speech immediately post-operatively and the patient was discharged 36 hours later.

CASE 3

An 81-year old hypertensive man presented with a one-week history of transient attacks with dysphasia and right upper limb weakness. He had 2-3 attacks per day, each lasting 1-2 hours. On the day of presentation he had a prolonged attack lasting 6-8 hours. Examination revealed a blood pressure of 220/120 mmHg and a left carotid bruit. Carotid doppler showed a pedunculated clot of the left internal carotid with significant internal carotid occlusion and a CT brain scan showed no abnormality. In view of the pedunculated nature of the carotid lesion, plus the frequency of attacks, the patient underwent emergency CEA. All attacks ceased post-operatively and he was discharged on aspirin and anti-hypertensive medication.

DISCUSSION

Several large studies have supported the role for urgent CEA in patients with acute cerebral ischaemia. Mentzer et al [6] compared 24 patients with fluctuating neurological deficit undergoing CEA with 31 matched patients managed conservatively. The outcome both for patients with stroke in evolution and crescendo transient ischaemic attack (TIA), was significantly better in the operative group. Greenhalgh et al [7] reported 15 patients with progressing stroke, 14 out of 15 (93%) improved significantly with only 1 case developing an ipsilateral stroke. A recent study by Eckstein et al [8] examined 71 consecutive patients undergoing emergency CEA, 16 had acute onset of severe stroke, 34 evolving and 21 crescendo TIA. The recovery rates for each group were 56.3%, 76.4% and 80.9% respectively. Although reports from the 1960's on urgent surgical revascularization have shown disappointing results, these patients would not have had CT brain scans and comatosed patients were included [9].

CEA on its own carries an increased risk of stroke and it remains clear that patient selection is crucial. Those with progressive or evolving stroke, crescendo TIA and CT brains scans not showing haemorrhage or large cerebral infarcts are most likely to benefit from urgent CEA.

In this report the first and second cases presented with stroke in evolution, whilst the third case had features compatible with crescendo transient ischaemic attacks. At surgery, all 3

patients had significant carotid stenosis with fresh clot present at the site of occlusion in the first 2 cases. All 3 patients were also remarkably better 24 hours post-endarterectomy and remained so for several months. The mean duration of hospital stay was 31 hours.

Additionally, these 3 cases had CEA done using local-regional anaesthesia. Carotid endarterectomy using this technique is known to carry a lower morbidity and lower cost, when compared to general anaesthesia [IX] and may be preferentially desirable when dealing with fluctuating cerebral perfusion.

The morbidity and mortality for patients with untreated ischaemic stroke is high, therefore, in addition to the judicious management of blood pressure and thrombolysis (including rTPA), urgent CEA should be added to the armamentarium for the treatment of acute stroke in selected cases.

CORRESPONDENCE TO

Mr. Michael J Ramdass 100 East Drive, Champs Fleurs, St. Joseph, Trinidad, West Indies E-mail: jimmyramdass@hotmail.com Fax: (868) 663-9064

References

1. Rosenbaum DM, Zambramski J, Frey J. Early treatment if ischaemic stroke with calcium antagonist. *Stroke* 1991; 22:437.
2. Mori E, Yoneda Y, Ohksawa S. Double-blind, placebo-controlled trial of recombinant tissue plasminogen activator (r-TPA) in acute carotid stroke. *Neurology* 1991; 41(suppl 1): 347.
3. European Carotid Surgery Trialists' Collaborative Group. MRC. European Carotid Surgery Trial: interim results for symptomatic patients with severe (70-99%) or with mild (0-29%) carotid stenosis. *Lancet* 1991; 337:1235-1243.
4. North American Symptomatic Carotid Endarterectomy Trial (NASCET) Steering Committee: North American Symptomatic Carotid Endarterectomy Trial. Methods, Patient characteristics and progress. *Stroke* 1991; 22:711-720.
5. Wylie EJ, Hein MF, Adams JE: Intracranial haemorrhage following surgical revascularization for treatment of acute strokes. *J Neurosurg* 1964; 21: 212-215.
6. Mentzer RM Jr, Finkelmeier BA, Crosby IK, Wellons HA Jr. Emergency Carotid Endarterectomy for fluctuating neurologic deficits. *Surgery* 1981 Jan; 89(1): 60-6.
7. Greenhalgh RM, Cuming R, perkin GD, Mc Collum CN. Urgent Carotid Surgery for high risk patients. *Eur J Vasc Surg* 1993 Mar; 7 (Suppl A): 25-32.
8. Eckstein HH, Schumacher H, Klemm K, Laubach H, Kraus T et al. Emergency Carotid Arterectomy. *Cerebrovasc Dis* 1999 Sep-Oct; 9(5): 270-81.
9. Corson JD, Chang BB, Shah DM, Leather R, DeLeo B, Karmody A. The Influence of Anaesthetic Choice on Carotid Endarterectomy Outcome. *Arch Surg* 1987 Jul; Vol 122.

Author Information

Asad Esack, MRCP

Departments of Medicine & Surgery , University of the West Indies

Michael J. Ramdass, MBBS MRCS

Departments of Medicine & Surgery, University of the West Indies

Dale Maharaj, FRCS

Departments of Medicine & Surgery, University of the West Indies

Aroon Naraynsingh, FRCA

Departments of Medicine & Surgery, University of the West Indies

S. Teelucksingh, MRCP

Departments of Medicine & Surgery, University of the West Indies

Vijay Naraynsingh, FRCP

Departments of Medicine & Surgery, University of the West Indies