

A Case Report Of An Incarcerated Gallbladder In A Parastomal Hernia

M Rashid, K Abayasekara, E Mitchell

Citation

M Rashid, K Abayasekara, E Mitchell. *A Case Report Of An Incarcerated Gallbladder In A Parastomal Hernia*. The Internet Journal of Surgery. 2009 Volume 23 Number 2.

Abstract

Gall bladder in a parastomal hernia is a rare condition which has only been reported twice before in the literature. We present a case of an incarcerated parastomal hernia in a seventy-four year old female, which contained an ischemic gallbladder in addition to small bowel. A cholecystectomy was performed and the patient made a full recovery. Unusual contents of hernia sacs are uncommon but can have important implications for intra-operative management and patient consent.

INTRODUCTION

Gall bladder in a parastomal hernia is a rare condition. Only two previous cases exist in the literature. We present a case of an incarcerated parastomal hernia which contained an ischemic gallbladder in addition to loops of viable small bowel.

CASE REPORT

The patient, a seventy-four year old female, was admitted in November 2007, as a surgical emergency with features of small-bowel obstruction.

Her past medical history included ulcerative colitis, hyperlipidemia, drug-controlled hypertension, Parkinson's disease, haemorrhoids, hypothyroidism, hiatus hernia and she also suffered from acute exacerbations of chronic obstructive airway disease.

Seventeen months ago, in June 2006, she had a total colectomy with end ileostomy for an acute exacerbation of ulcerative colitis, which had failed to respond to medical treatment. The surgery itself was uncomplicated. Inflamed and oedematous bowel was found, the small bowel was normal, good haemostasis was achieved and an ileostomy was created in the right iliac fossa. Initially her wound healed very well.

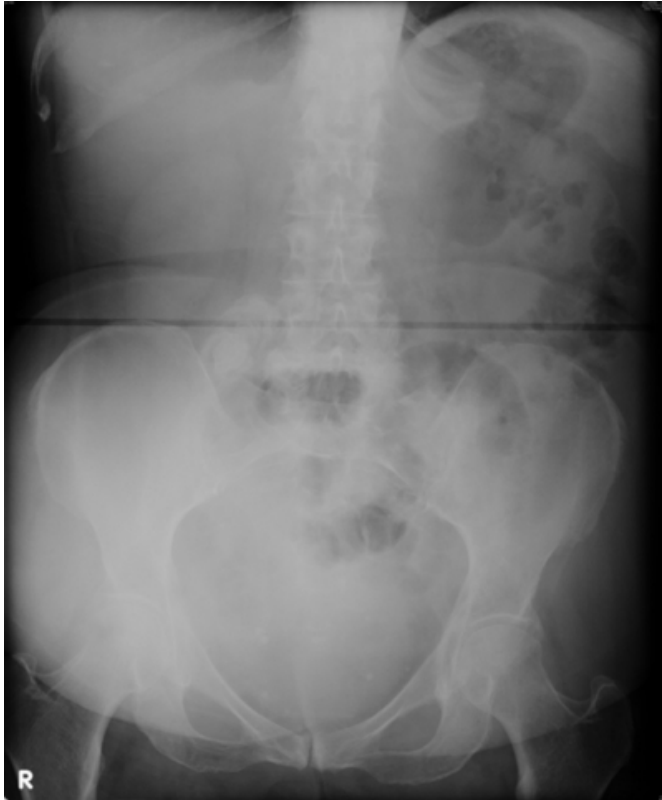
Six months ago, in May 2007, a parastomal hernia and a midline incisional hernia were diagnosed at routine follow-up. They were not treated at the time as they were uncomplicated and asymptomatic, and she was discharged. Four months ago, in July 2007, she was seen again by our

stoma team, as she was concerned that the parastomal hernia was now becoming unsightly. At this stage the parastomal hernia was moderate in size, soft, non-tender and semi-reducible but the stoma was working well. She was advised against lifting her grandchildren.

At admission, apart from a partial pressure of oxygen of 8.1 kPa on air, her systemic observations were unremarkable. On examination, her parastomal hernia was large, hard, tender and irreducible. The rest of her abdomen was soft and non-tender. Her abdominal radiograph showed a distended gallbladder and her chest radiograph was normal. Her blood tests on admission showed a white cell count of $15.5 \times 10^9/l$ with neutrophilia. The bilirubin was raised at $27 \mu\text{mol/l}$ but all the other liver biochemistry was normal. Her amylase and renal biochemistry were also unremarkable.

Figure 1

Image 1. Admission Abdominal Radiograph



She was placed on intravenous fluids, antibiotics, analgesia and nasogastric suction.

However, over the next twenty-four hours, her pain and tenderness failed to resolve. Nasogastric output increased and there was persistent irreducibility. This prompted an emergency laparotomy.

At laparotomy she was found to have two midline incisional hernias (containing only omentum) and a parastomal hernia with viable small bowel and a large incarcerated gallbladder, which showed signs of dusky constriction. An open cholecystectomy was therefore performed. A large stone was found in the gallbladder. The incarcerated small bowel was freed. Extensive adhesiolysis was required to free multiple loops of small bowel from the anterior abdominal wall. A pre-peritoneal mesh repair of the parastomal hernia was performed. The incisional hernias were also repaired. As the ileostomy was healthy and well sited it was not repositioned.

Histology of the gallbladder showed that it was grossly oedematous with chronic

inflammation and ulceration of the mucosa. There were early ischaemic changes; however, the muscle layer was largely

intact. The section through the cystic duct resection margin was normal and viable.

The patient went home a few days later but unfortunately presented again in March 2009 with another parastomal hernia, this time an ultrasound scan showed herniation of bowel visible through the abdominal wall just superior to the stoma. The stoma site was repositioned.

DISCUSSION

A hernia is defined as the protrusion of a viscus or part of a viscus through the walls of its containing cavity. Over the years, surgeons have been intrigued by the contents of hernia sacs.

Almost all intra-abdominal organs can be found in a hernia sac, including the vermiform appendix, stomach, small bowel, colon, omentum, ovary, fallopian tube and urinary bladder^{1,2,3}. Some are named after people who first described them. A Littre's hernia is one which contains a Meckel's diverticulum.⁴ An appendix in an inguinal hernia sac which has become complicated by acute appendicitis, is known as Amyand's hernia, after an eighteenth century surgeon, who described a case of acute appendicitis the hernia sac of a male child for the first time.⁵ Rene Croissant de Garengot described appendicitis in a femoral hernia, in 1731.⁶

Finding a gallbladder in a hernia is even rarer. To date, only three case reports exist in the literature, two of which were found in a parastomal hernia. The first, published in 1985⁷, reports a ninety-six year old female, who presented with nausea, vomiting, pyrexia and jaundice. On examination, an incarcerated epigastric hernia was found with focal redness and tenderness. Blood tests showed a white cell count of $20 \times 10^9/l$, slightly raised bilirubin, and slightly raised alkaline phosphatase levels. The patient was taken to theatre, where an incarcerated, oedematous and ischaemic gallbladder was found in the epigastric hernia. After opening the fascial ring and releasing the cystic structures, the ischaemic signs disappeared. The gallbladder was replaced in its anatomical site and the hernia was repaired. A cholecystectomy was not performed as the gallbladder was viable. The second, published in 2005⁸, reports a sixty-three year old female, who had had an end colostomy after transverse colonic resection for bowel ischaemia and presented five weeks postoperatively with abdominal pain, nausea and increased stoma output. Examination revealed a parastomal hernia and a small two-centimetre mass in the right upper quadrant, above the stoma site, which was healthy. Computerised tomography showed the gall bladder. Liver function tests

were normal and the common bile duct was not dilated. She was taken to theatre, where the gall bladder was reduced but not removed due to her cardiac comorbidity (cardiac ejection fraction of less than 30% with severe stenosis in multiple coronary vessels). The third, also published in 2005⁹, reports a seventy-three year old female with an ileal conduit placed in the right lower quadrant, who presented with acute incarcerated parastomal hernia. There were no symptoms of bowel obstruction. Blood tests showed a white cell count of $19.0 \times 10^9/L$ (77% neutrophils) and total bilirubin concentration of 1.7mg/dL. Surgical exploration revealed a hernia sac containing a twelve-centimetre inflamed gallbladder. A cholecystectomy was performed and the parastomal hernia repaired.

This report highlights the need to be aware of unusual contents of hernia sacs, which can have important implications for intra-operative management of the patient. In this case, the incarceration of the gallbladder in the parastomal hernia probably caused cystic duct obstruction and cystic blood vessel compression, both leading to ischaemic changes in the gallbladder wall. Given the ischemic changes in an already diseased gallbladder, a

cholecystectomy was performed. Unusual contents of hernia sacs can also have implications for patient consent, as procedures, which may not be anticipated during the pre-operative discussion, may need to be carried out.

References

1. Gurer A, Ozdogan M, Ozlem N, Yildirim A, Kulacoglu H, Aydin R. Uncommon content in groin hernia sac. *Hernia*; 2006; 10: 152-155
2. Greenberg J, Arnell TD. Diverticular abscess presenting as an incarcerated inguinal hernia. *Am Surg*; 2005; 71: 208-209
3. Casadio G, Chendi D, Franchella A. Fishbone ingestion: two cases of late presentation as pediatric emergencies. *J Pediatr Surg*; 2003; 38: 1399-1400
4. Ravikumar KK, Khope SS, Ganapathi BP. Littre's hernia in a child--an operative surprise (a case report). *J Postgrad Med*; 1989; 35: 112
5. Orr KB. Perforated appendix in an inguinal hernial sac: Amyand's hernia. *Med J Aust*; 1993; 159: 762-763
6. Nguyen ET, Komenaka IK. Strangulated femoral hernia containing a perforated appendix. *Can J Surg*; 2004; 47: 68-69
7. Goldman G, Rafael AJ, Hanoch K. Acute acalculous cholecystitis due to an incarcerated epigastric hernia. *Postgraduate Medical Journal*; 1985; 61, 1017-1018
8. Garcia RM, Brody F, Miller J, Ponsky TA. Parastomal herniation of the gallbladder. *Hernia*; 2005; 9: 397-399
9. St. Peter SD, Heppell J. Incarcerated gallbladder in a parastomal hernia. *J Can Chir*; 2005; Vol. 48, No 1, février

Author Information

Mohammed Rashid, MBBS (Hons) BSc (Hons)

Academic Foundation Doctor, Department of General Surgery Norfolk and Norwich University Hospital

Kumar Abayasekara, MS FRCS(Eng) FRCS(Gen.Surg)

Senior Registrar in Vascular and General Surgery, Norfolk and Norwich University Hospitals NHS Foundation Trust

Esther Mitchell, MD

Research Fellow, University of East Anglia