

Nasal Polyposis in Wegener's Granulomatosis: A rare presentation

Rijuneeta, N Panda, P Bambery, B Radotra

Citation

Rijuneeta, N Panda, P Bambery, B Radotra. *Nasal Polyposis in Wegener's Granulomatosis: A rare presentation*. The Internet Journal of Otorhinolaryngology. 2005 Volume 4 Number 2.

Abstract

Wegener's Granulomatosis (WG) is a rare granulomatosis vasculitis affecting upper, lower respiratory tracts and kidneys. A 15 year old boy presented with the complaints of unilateral nasal obstruction and was diagnosed as a case of nasal polyp for which endoscopic polypectomy was done but the symptoms kept on increasing instead of any relief. The further course of the disease and management is discussed.

INTRODUCTION

Wegener's granulomatosis (WG) is an uncommon, necrotising, granulomatous vasculitis usually affecting the upper and lower respiratory tracts and kidneys^{1, 3}. Several organs and systems can be involved within a variable disease course^{1,5}. WG belongs to a group of primary systemic vasculitides of unknown etiology that are associated with antineutrophil cytoplasmic antibodies (ANCA). Untreated, WG was invariably fatal. Satisfactory therapeutic responses were obtained only when cytotoxic drugs were used^{1,5}. Early diagnosis and treatment is of added significance because of the marked improvement in overall survival seen with cyclophosphamide therapy^{1,6}. However, in India, a significant number of patients are still being misdiagnosed as tuberculosis, thus leading to a delay in the institution of appropriate therapy.⁷ With the availability of cANCA and more recently, Proteinase-3 ELISA, invasive biopsy procedures may not be absolutely necessary in patients with characteristic clinical features⁸.

Although nose, sinus and pharynx involvement is seen in almost 84% of patients with WG, presentation of a unilateral antrochoanal poly is uncommon⁸.

Our patient presented with a greyish polyp causing unilateral nasal obstruction and epistaxis with no evidence of systemic disease. This is quite an unusual feature for patients with WG^{1,8}.

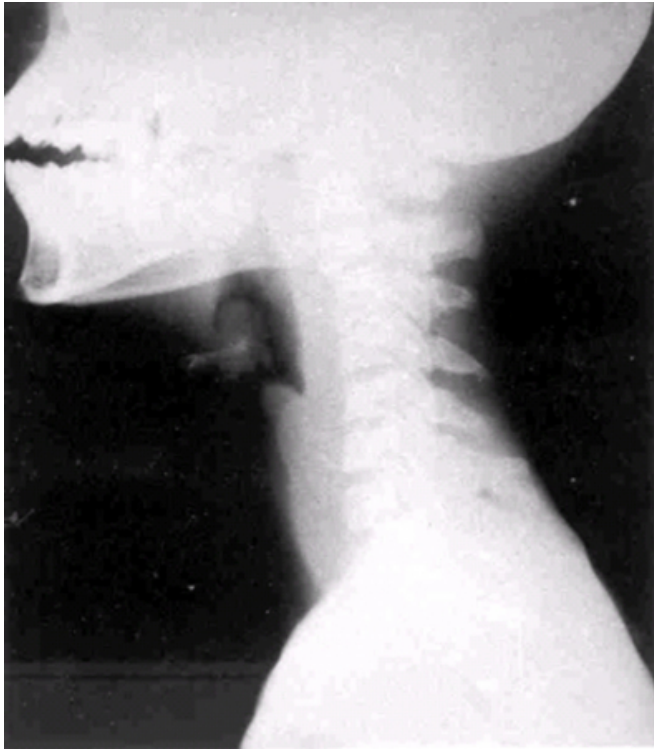
CASE REPORT

A 15-year-old boy presented with the complaints of

unilateral nasal obstruction and purulent nasal discharge on the right side since three months. There were no other complaints. Examination revealed a grayish, slough-covered polyp in the right nasal cavity. A contrast enhanced CT scan showed a hyper dense mass filling the right nasal cavity and extending into the right maxillary antrum depicting the picture of an antrochoanal polyp (fig.1).

Figure 1

Figure 1: CECT showing hyper dense mass filling the nasal cavity and Maxillary sinus.



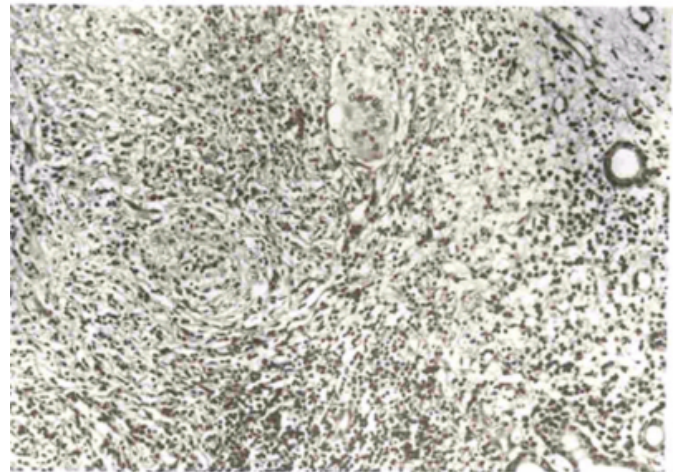
An Endoscopic polypectomy was done by a practitioner elsewhere. A diagnosis of granulomatous lesion with possibility of fungal granuloma or Tuberculosis was entertained. The patient was given antitubercular drugs, which he took for one month and stopped of his own. He presented to us in the ENT Outpatients of Postgraduate Institute of Medical Education and research Chandigarh, India with the complaints of high-grade fever since 7 days associated with chills and rigor. He had occasional bleeding from the nasal cavity along with purulent nasal discharge. There was also a difficulty and pain during swallowing solids and semisolids for one week. He did not have any history of drug or food allergy. There was history of unquantified loss of weight. He had undergone tonsillectomy for recurrent sore throat and odynophagia 8 months previously.

On examination, the patient was sick looking and thin. He had high-grade fever of 103°F and was dehydrated. On examination of nose, there was foul smelling purulent discharge and slough in both nasal cavities. There was tenderness of the external nose, but no bleeding at that time. There was tenderness over both the maxillary sinuses. Examination of the oral cavity revealed a slough covered mucosal ulceration and swelling of the soft palate, uvula and

buccal mucosa. On posterior rhinoscopy, there was purulent discharge at bilateral posterior choanae. Indirect laryngoscopy showed congested and edematous epiglottis with severe congestion of bilateral arytenoids, true cords and false cords. There were no clinically palpable lymph nodes in the neck and anywhere else in the body. Lateral X-ray of soft tissues of neck showed rounded, swollen epiglottis and arytenoids (Fig.2).

Figure 2

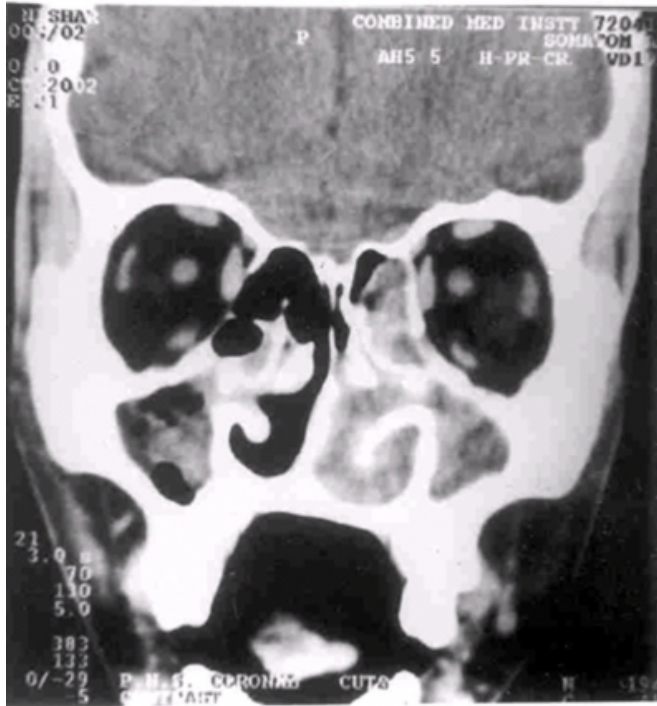Figure 2: X ray Soft Tissue Neck Lateral view showing rounded, swollen epiglottis and arytenoids



X-ray chest showed basal infiltrates on the right side (Fig.3), which got cleared after 5 days of treatment.

Figure 3

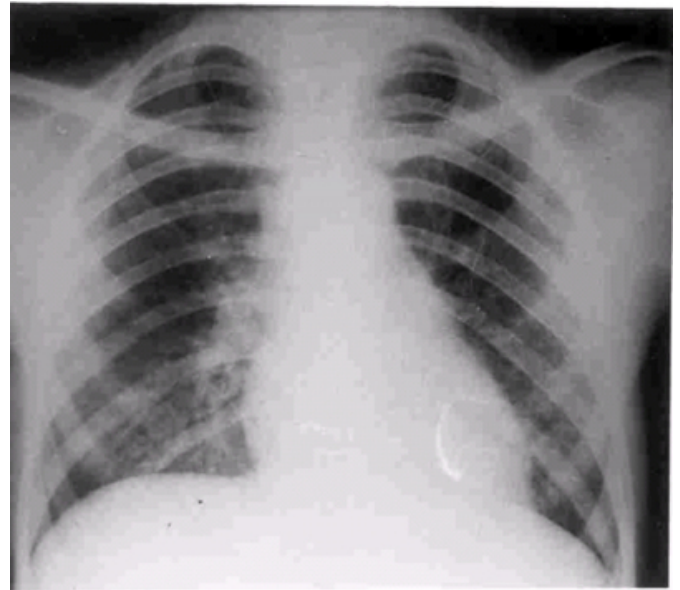
Figure 3: X-ray Chest PA view showing basal infiltrates on right side.



The sputum for AFB examination for three consecutive days was found negative. All renal and liver function tests were normal. C-ANCA was found strongly positive. Histopathology of the specimen from the nasal cavity was reviewed. It showed necrotic tissue with chronic inflammatory cells and fibrin deposits. (Fig 4).

Figure 4

Figure 4: Histopathology of the specimen showing necrotic tissue with chronic inflammatory cells and small vessel with vasculitis (H&E X 140).



Some fragments were lined by respiratory epithelium. Edema and lymphoplasmocytic infiltrate with focal lymphoid aggregate formation was seen. PAS and AFB stain were noncontributory. Within the necrotic areas, many blood vessels showed thrombosis and vascular necrosis as evidenced in EVG stain. So the possibility of WG was considered.

The patient was started on intravenous antibiotics, analgesics and antipyretics. The nasal discharge sent for gram staining and culture sensitivity grew pseudomonas aeruginosa sensitive to piperacillin. The patient started improving and remained alright for 5 days when he had acute episode of profuse bleeding from the nose and oral cavity, for which tracheotomy had to be done immediately along with packing of both the nose and oral cavity. After pack removal the patient had two more episodes of profuse bleeding. He was started on intravenous dexamethasone for three days and then on oral prednisolone 30mg tab and Azathioprine 75 mg once a day respectively. The patient showed remarkable improvement with this treatment.

At this time, the CECT was repeated which showed heterogeneous soft tissue density filling bilateral nasal cavities and Para nasal sinuses with lateral bowing of bilateral lamina papyracea. The patient started improving after the treatment and was decannulated successfully. He underwent panendoscopy, which showed a little slough in the nasal cavity and mild ulceration in the trachea. A biopsy

taken from the nasal cavity was found to contain necrotic tissue only. He was discharged on prednisolone and azathioprine and on follow up since two and half years with marked improvement in all symptoms.

DISCUSSION

WG is a distinct clinocomorphological entity. Anatomically, WG can be classified according to the extent of involvement of the upper airways and related structures (E), the lungs (L) and the kidneys (K)⁴. So the classic form of the disease is designated as ELK. Progression of disease from E to either EL or EK and then to ELK is well described⁴. Our patient had a limited involvement of nose, para nasal sinuses and upper airways only (E). In the Mayo clinic series 28% had E alone 22% had ELK, 16% each had L and EL, 10% had LK and 8% had EK at diagnosis whereas our center has reported that 64% of Indian patients with WG had ELK disease at diagnosis.

Our patient had presented with unilateral polyposis with no other symptoms. This is quite a rare presentation of WG. McDonald et al⁹, in a review of 108 patients with Wegener's Granulomatosis reported some of the less well known areas of involvement. None of the reported patients had nasal polyps. DeCruz¹⁰ et al reported nasal symptoms in almost all of their patients. However, none of the patients had nasal polyposis. Usually the presenting features are of chronic sinusitis and slough or crusting in the nasal cavity.

For a disease in which the average untreated survival was only 5 months², the delay in institution of therapy could have had a crucial impact on outcome. The diagnosis of WG, in an area of high prevalence of tuberculosis, is difficult. This patient's initial histopathology showed granulomatous inflammation, which was considered to represent tuberculosis. Subsequently he was started on antitubercular drugs. It was only on review here that vasculitis was looked for and subsequently demonstrated. This was similar to other studies from India in which most of the patients were receiving antitubercular drugs at the time of presentation^{7,8}.

The diagnosis of the WG can only be established at history^{1,11,14,15}. Among all the tissues, the lung offers the best yield. However, the sinuses, orbit, nose and ears may also provide adequate material for diagnosis. Laboratory tests are non-specific and radiology has many mimics. ANCA supports the diagnosis if present but does not exclude it. The response to treatment with prednisolone and cyclophosphamide is

very well known and gratifying but cyclophosphamide is known to cause cystitis, sterility, bladder cancer and myelodysplasia. Hence azathioprine was chosen to control WG in this young male.

To conclude, presence of nasal polyposis with intractable epistaxis without a relevant cause should raise the suspicion of vasculitis and warrants detailed histological examination.

CORRESPONDENCE TO

Dr. Naresh K Panda, MS, DNB, FRCS Ed Additional Professor Department of Otolaryngology PGIMER, Chandigarh, India Pin 160012

References

1. Fauci AS, Haynes BF, Kartz P, Wolff SM. Wegener's granulomatosis Prospective clinical and therapeutic experience with 85 patients for 21 years. *Ann Intern Med* 1983; 98: 76 - 85.
2. Walton EW. Giant Cell granuloma of the respiratory tract *Br Med J* 1958; 2: 265 - 270.
3. Godman GC, Churg J. Wegener's granulomatosis: pathology and review of literature. *Arch Pathol* 1954; 58: 533 - 553.
4. De Remee RA, McDonald TJ, Harrison EG. Wegener's granulomatosis, anatomic correlates. A proposed classification. *Mayo Clin Proc* 1976; 51: 777 - 781.
5. Fauci AS, Wolff SM. Wegener's granulomatosis. Studies in eighteen patients and a review of literature. *Medicine* 1973; 52: 535 - 561.
6. Israel HL, Patchefsky AS, Saldana MJ. Wegener's granulomatosis. Lymphomatoid granulomatosis and benign angitis and granulomatosis of lung. Recognition and treatment. *Ann Intern Med* 1977; 87: 691 - 699.
7. Bamberg P, Sakhuja V, Gupta A et al. Wegener's granulomatosis in North India. An analysis of eleven patients. *Rheumatoid Int.* 1987; 7: 243 - 247.
8. Kumar A, Pandhi A, Menon A. Wegener's Granulomatosis in India. Clinical features treatment and outcome of Twenty-five patients. *Indian J Chest Dis. Allied Sci* 2001; 43: 197 - 204.
9. McDonald TJ, DeRemee RA. Wegener's granulomatosis. *Laryngoscope* 1983; 93: 220 - 230.
10. D'Cruz DP, Baguley E, Asherson RA, Hughes GR. Ear Nose and Throat symptoms in sub acute Wegener's granulomatosis. *BMJ* 1989; 299 (6696): 419 - 422.
11. Wolff SM, Fauci AS, Horn RG, Dale DC. Wegener's granulomatosis. *Ann Intern Med* 1974; 81: 513 - 525.
12. Pinching AJ, Lockwood CM, Pussell BA, Rees AJ, Weny P, Evans DJ, Bowley N, Peters DK. Wegener granulomatosis: Observations on 18 patients with severe renal disease. *QJ Med* 1983; 52: 435 - 460.
13. DeRemee RA, McDonald TJ, Weiland LH. Wegener's granulomatosis. Observations on treatment with antimicrobial agents. *Mayo Clin Proc* 1985; 60: 32.
14. Cupps TR, Fauci AS. The vasculitides. In: Smith LH (ed) *Major problems in Internal medicine*. Saunders Philadelphia. 1981; 21: 72 - 87.
15. Liebow AA. Pulmonary angitis and granulomatosis. *Am Rev Respir Dis* 1973; 108: 1 - 18.

Author Information

Rijuneeta, M.S.

Department of Otolaryngology, Postgraduate Institute of Medical Education & Research

Naresh K. Panda, MS, DNB, FRCS (Ed)

Department of Internal Medicine, Postgraduate Institute of Medical Education & Research

P. Bambery, MD, FAMS

Department of Histopathology, Postgraduate Institute of Medical Education & Research

B.D. Radotra, M.D.

Department of Histopathology, Postgraduate Institute of Medical Education & Research