

Angle stable plate osteosynthesis for non-union of rib fractures

W Zuidema

Citation

W Zuidema. *Angle stable plate osteosynthesis for non-union of rib fractures*. The Internet Journal of Orthopedic Surgery. 2006 Volume 6 Number 2.

Abstract

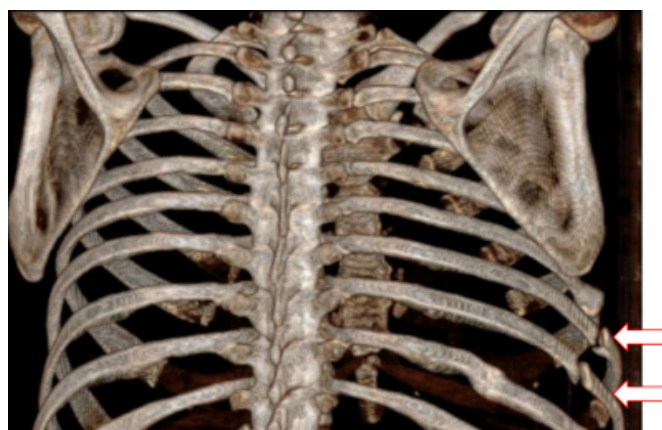Non-union after rib fractures is rare. In the English literature only a handful cases are described. The recommended treatment in most of these cases was resection of the pseudarthrosis or restriction of activity. In this article the case of a 42 year old woman is presented who sustained rib fractures after a traffic accident and developed a painful non-union of two of her rib fractures. Those were treated with angle stable osteosynthesis plate and screws.

CASE REPORT

A 42 year old woman was brought to the hospital after she was hit by a bus during a bicycle ride. She sustained a light head trauma, a processus spinosi fracture at the level of thoracic 10 and fractures of ribs 3 till 12 on the right side of her chest. There was no hemothorax, pneumothorax or flail chest.

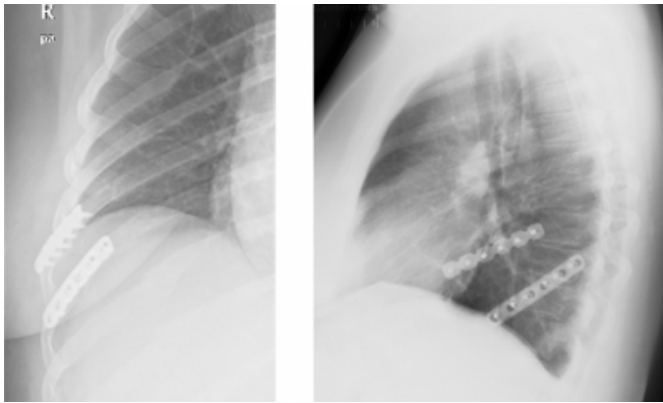
She was admitted to the medium care facility and pain was managed adequately using a thoracic epidural catheter. Her hospital stay was uneventful and she was discharged home after one week with oral pain medication. During visits to the out-patient clinic she consistently complained about pain in her right chest wall. After 8 months she still had pain localized on her 7th and 8th rib during work. Evaluation with reconstruction of a CT-scan of her chest wall showed healing of most of the rib fractures except for a non-union of the seventh and eighth rib.

Figure 1



Operative correction in the left lateral position through a single transverse incision was carried out, with resection of the pseudarthrosis of both ribs. After resection of the pseudarthrosis, successful reduction of the rib ends was achieved. The ribs were then both stabilized using two small fragment locking compression plates and angle stable screws (Synthes, Switzerland). Two six-hole plates were chosen, to allow for three screws on each side of the fracture. Because of a small opening in the pleura during excision of the pseudarthrotic tissue at the level of the seventh rib, a chest tube was placed on the same side through the fifth intercostal space. It was removed after two days, just after removing of the vacuum wound drain.

Figure 2



The patient made a fast and rapid recovery and after two weeks she had no pain whatsoever and re-started her work.

Discussion: Rib fractures are one of the most common injuries after traffic accidents. Most simple rib fractures heal well with minimal intervention and without lasting consequences to the patient. Very seldom, persistent localised pain due to a non-union of the rib fracture occurs.^{1,2,3,4,5,6} In the reported case the pain was preventing the patient to perform her (physical) activity at her job.

In case of persistent localised and ever present pain for more than 6 months after rib fractures, patients are usually well managed with an intercostal nerve block at that location since the source of the pain is the intercostal nerve.

Whenever there is a persistent localised pain on a rib, occurring only during physical activity more than 6 months after chest wall trauma, further diagnostics imaging may reveal a non-union of the rib fracture(s).

In the past these were mostly treated with rib resection or restriction of activities. The availability of titanium implants and especially the angle stable implants, makes it now possible to stabilize rib fractures or treat non-unions of the ribs with unicortical screws. This prevents any sharp screw point sticking out into the thoracic cavity and at the same time gives more than enough mechanical stability to lead to bony union. Furthermore, this technique does not put the neurovascular bundle at risk and there is no need to open the pleura intentionally.

The angle stable plate and screws seem to have advances above other surgical ways of treating painful non-union of the ribs, but further studies in this field are needed.

CORRESPONDENCE TO

W.P.Zuidema, MD Department of Trauma-surgery V.U.-
Medical Centre De Boelelaan 1117 1007 MB Amsterdam
The Netherlands w.zuidema@vumc.nl

References

1. Cacchione RN, Richardson JD, Seligson D. Painful non-union of multiple rib fractures managed by operative stabilization. *J Trauma* 2000; 48: 319-321
2. Ng ABY, Giannoudis PV, Bismil Q, Hinsche AF, Smith RM. Operative stabilisation of painful non-united multiple rib fractures. *Injury* 2001; 32(8): 637-639
3. Morgan-Jones RL, Mackie IG. Non-union of a fracture of the 8th rib. *Injury* 1996; 27(2): 147-148
4. Slater MS, Mayberry JC, Trunkey DD. Operative stabilization of a flail chest six years after injury. *Ann Thorac Surg* 2001; 72: 600-601
5. Kerr-Valentic MA, Arthur M, Mullins RJ, Pearson TE, Mayberry JC. Rib fracture pain and disability: can we do better. *J Trauma* 2003; 54: 1058-1064
6. Freiburger RH, Mayer V. Ununited bilateral fatigue fractures of the first ribs: a case report and review of the literature. *J Bone Joint Surg Am* 1964; 46: 615-618

Author Information

W.P. Zuidema, M.D.

Trauma Surgeon, Department of Trauma-surgery, V.U.- Medical Centre Amsterdam