

An interesting tumour case: Seeding To Incision Scar, Osseous Metaplasia In Metastasis And More

T Isken, E Ozgentas, H Gulkesen, K Bulut, G Karpuzuglu

Citation

T Isken, E Ozgentas, H Gulkesen, K Bulut, G Karpuzuglu. *An interesting tumour case: Seeding To Incision Scar, Osseous Metaplasia In Metastasis And More*. The Internet Journal of Urology. 2007 Volume 5 Number 2.

Abstract

We reported a tumour which has many different interesting characteristics. There was an ossified metastasis of bladder tumour to the abdominal wound 19 years after partial cystectomy. Also origin of the metastasis was direct seeding to the incision line. Additionally eight years after metastasectomy, this patient was alive without evidence of disease.

We want to remind following points again on the basis of related literature: (a) if no evidence of any other extrapulmonary disease are found, one should consider lung metastasectomy. (b) Calcification, connective tissue proliferation may complicate the clinical picture. (c) Inoculation of the tumour cells into the incision line can be expected for bladder carcinomas. To our knowledge, this is the fourth case of osteoid metaplasia in abdominal wall metastasis of transitional cell carcinoma, and total number of osteoid metaplasia in metastatic TCC cases reaches to seven with the case presented in this paper.

INTRODUCTION

The propensity for seeding of transitional cell tumours following transvesical surgery has been known for many years.^{1,2,3}

Lung metastases also are usually seen in transitional cell tumours. The role of surgery in lung metastases depends on the original source of the malignancy. Distant metastases of certain tumours show a preferential site of lodging and outgrowth.^{4,5,6} Such dissemination pattern makes the possibility of achieving surgical control much better than that with tumours that typically metastasize to multiple organs.

Ossified transitional cell carcinoma in primary and metastatic sites is very rare. Last literature which is related to ossified metastasis in transitional cell carcinoma was reported in 1995 by Kinouchi et al.⁷

We reported a tumour which has many different interesting characteristics. There was an ossified metastasis of bladder tumour to the abdominal wound 19 years after partial cystectomy. Also origin of the spreading of the metastasis was direct seeding to the incision line. Additionally eight years after metastasectomy, this patient was alive without evidence of disease.

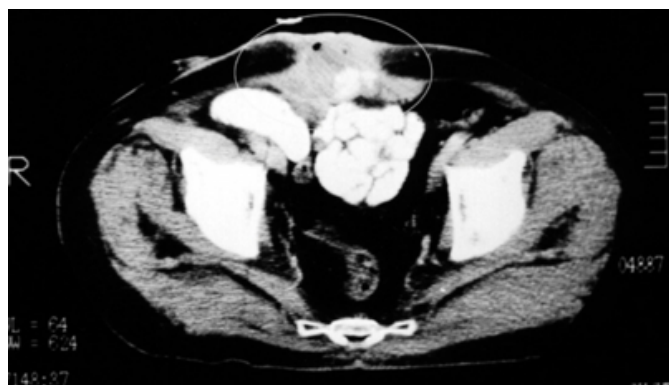CASE

A 52 years old male patient admitted with the complaint of suprapubic mass in 1993. He had partial cystectomy because of bladder transitional cell carcinoma (TCC) in 1976. In follow up, local recurrence was detected and total cystoprostatectomy and ileal conduit operation was performed in 1979. He had solitary TCC metastasis at lung and had lobectomy in 1988.

Physical examination revealed a three inches diameter mass in abdominal wall located at old incision scar. A fistula was present and haemorrhagic discharge was observed. View of the mass on the incision line has been considered keloid. Also the mass was evaluated as keloid by biopsy which was obtained outer surface of the mass. Haemorrhagic drainage continued for two years and no evidence of malignancy was detected in one more biopsy and cytopathologic examination of discharge. CT revealed partial calcification within the mass (figure-1).

Figure 1

Figure 1: Computerized axial tomography slice of the tumour. CT revealed partial calcification within the mass. (Ellipse shows tumour in abdominal wall).



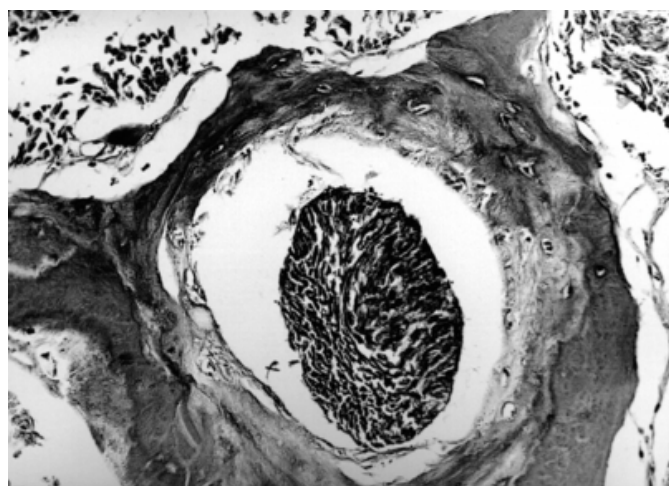
In January 1995, after surgical removal and abdominal wall reconstruction by rectus femoris flap, the mass was sent for pathologic examination.

In 1998, no other metastasis sign could be found at postoperative 3rd years (8 years after the lobectomy operation).

In examination of the pathologic specimen; cut surface was yellow-brown and showed partial calcification. The pathological diagnosis was grade 2 TCC metastasis and stromal osseous metaplasia (figure-2).

Figure 2

Figure 2: Histopathological findings reveal metastatic grade 2 transitional cell carcinoma with ossification



Postoperatively, it was decided not to give chemotherapy. Nine years after metastasectomy, this patient was alive without evidence of disease.

The patient had no evidence of disease by June 1999.

DISCUSSION

The origin of metastasis may be implantation to abdominal wall during previous abdominal operations. Bladder cancer is able to spread by implantation in abdominal wounds, denuded urothelium, resected prostatic fossa, or traumatized urethra. ⁸ Antiadherence agents can reduce these risks. ^{9,10} Implantation occurs most commonly with high-grade tumours. Tumour implantation into the resected prostatic fossa is an infrequent occurrence but, again, primarily occurs with high-grade and multiple tumours.

Transitional cell carcinoma is typically a tumour that metastasizes to multiple sites. This minimizes the role of surgery for distant disease. However, confronted with an isolated lung lesion suspected to be metastasis, surgery may potentially provide long-term survival and cure. In such highly selected cases, universally accepted criteria for pulmonary metastasectomy should be applied. ⁴ Siefker-Radtke et al showed 33% survival at 5 years after metastasectomy. This suggest that resection of metastatic disease is feasible and may contribute to long-term disease control especially when integrated with chemotherapy ¹¹ The metastatic mass at abdominal wall in our case was initially evaluated as benign, because of sampling error in biopsies and presence of calcification. Thus, the patient's therapy was delayed for two years.

We want to remind following points again for the bladder carcinoma on the basis of related literature: (a) For lung metastasis, if no evidence of local recurrence and no evidence of any other extrapulmonary disease are found, one should consider lung metastasectomy. Metastasectomy donate longer life without additional long metastasis than prediction. (b) Calcification, connective tissue proliferation, or infection may complicate the clinical and pathologic picture in tumour patients. (c) All mass must be considered as a metastasis again and again for a cancer patient. To avoid wrong diagnosis, we must be sure that biopsies must involve deep portion of this kind of mass. (d) Inoculation of the tumour cells into the incision line or around the operation area, can be expected for bladder carcinomas and as well as other carcinomas also for other carcinomas.

To our knowledge, this is the fourth case of osteoid metaplasia in abdominal wall metastasis of TCC, and total number of osteoid metaplasia in metastatic TCC cases reaches to seven ⁷ with the case presented in this paper.

CONCLUSION

Measures should be taken to prevent tumour cell seeding. Every physician knows that behaviour of the cancer can not estimate. Metastasectomy should be considered for the metastasis which is located only in one area. Osteoid metaplasia can be seen rarely in metastasis of the bladder tumours.

CORRESPONDENCE TO

Tonguc Isken M.D. Assistant Professor Kocaeli University
Faculty of Medicine Department of Plastic and
Reconstructive Surgery Kocaeli, TURKEY Phone: +90 262
3037202 e-mail: tongucisken@yahoo.com

References

1. Micali, S., Celia, A., Bove, P., et al. Tumor seeding in urological laparoscopy: an international survey. *J Urol* 2004; 171: 2151-4,
2. Fong, C. J., Chen, T., Hsieh, D.S., et al. Possibility of spontaneous seeding of transitional cell carcinoma of the ureter in renal tubules: another mechanism of transitional cell carcinoma dissemination. *Int J Urol* 2006; 13: 997-9,
3. Treuthardt, C., Danuser, H., Studer, U.E. Tumor seeding following percutaneous antegrade treatment of transitional cell carcinoma in the renal pelvis. *Eur Urol* 2004; 46: 442-3,
4. Davidson, R. S., Nwogu, C.E., Brentjens, M.J., et al. The surgical management of pulmonary metastasis: current concepts. *Surg Oncol* 2001; 10: 35-42,
5. Nakagawa, S., Nakao, M., Watanabe, H., et al. [Surgical resection of pulmonary metastasis from genitourinary cancers]. *Hinyokika Kiyo* 1989; 35: 225-9,
6. Orteza, A. M., Kandzari, S.J., Milam, D.F. Transitional cell carcinoma of the bladder with pulmonary metastasis: case report on 5-year survival following resection of metastasis. *J Urol* 1971; 105: 232-5,
7. Kinouchi, T., Hanafusa, T., Kuroda, M., et al. Ossified cystic metastasis of bladder tumor to abdominal wound after partial cystectomy. *J Urol* 1995; 153: 1049-50,
8. Weldon, T. E., Soloway, M.S. Susceptibility of urothelium to neoplastic cellular implantation. *Urology* 1975; 5: 824-7,
9. Brocks, C. P., Buttner, H., Bohle, A. Inhibition of tumor implantation by intravesical gemcitabine in a murine model of superficial bladder cancer. *J Urol* 2005; 174: 1115-8,
10. Van Every, M. J., Sago, A.L., Ehler, W.J., et al. Sucralfate inhibition of tumor cell implantation in the murine urinary bladder. *J Urol* 1988; 140: 188-90,
11. Siefker-Radtke, A. O., Walsh, G.L., Pisters, L.L., et al. Is there a role for surgery in the management of metastatic urothelial cancer? The M. D. Anderson experience. *J Urol* 2004; 171: 145-8,

Author Information

Tonguc Isken, M.D.

Department of Plastic and Reconstructive Surgery, Faculty of Medicine, Kocaeli University

Ege Ozgentas, M.D.

Department of Plastic and Reconstructive Surgery, Faculty of Medicine, Kocaeli University

Hakan Gulkesen, M.D., M.Sc.

Pathologist and Assistant Professor, Department of Biostatistics and Medical Informatics, Faculty of Medicine, Kocaeli University

Kemal Bulut, M.D.

Department of Urology, Faculty of Medicine, Kocaeli University

Gülten Karpuzuglu, M.D.

Department of Urology, Faculty of Medicine, Kocaeli University