

Familial Hypertrophic Cardiomyopathy: A Case Report From Kumasi, Ghana

Y Adu-Boakye, I Ogyefo, J Kudiabor, G Solomon

Citation

Y Adu-Boakye, I Ogyefo, J Kudiabor, G Solomon. *Familial Hypertrophic Cardiomyopathy: A Case Report From Kumasi, Ghana*. The Internet Journal of Cardiology. 2021 Volume 16 Number 1.

DOI: [10.5580/IJC.55857](https://doi.org/10.5580/IJC.55857)

Abstract

Hypertrophic cardiomyopathy is a familial disease with an autosomal dominant mode of inheritance in about 60% of cases. It is usually asymptomatic in its presentation and commonly detected incidentally. Some patients may present with chest pain, palpitations, dizziness, and sudden cardiac death from vigorous exercise. We present a familial case of hypertrophic cardiomyopathy with an index patient referred on account of chest pain and palpitations. An electrocardiogram showed deep septal Q-waves, T-wave inversions in the lateral leads and left ventricular hypertrophy. An echocardiogram showed asymmetrical septal hypertrophy with a left ventricular wall thickness of 21.2mm and a systolic anterior motion (SAM). A family screen of some first-degree family members who consented to ECG and echocardiogram was performed. The mother of the index patient fulfilled the criteria for HCM on ECG and echocardiogram.

INTRODUCTION

Hypertrophic cardiomyopathy (HCM), previously known as hypertrophic obstructive cardiomyopathy (HOCM) or idiopathic hypertrophic subaortic sclerosis (IHSS) is defined by the presence of increased left ventricular (LV) wall thickness that is not solely explained by abnormal loading conditions [1]. It has diverse clinical presentations and can be found in all age groups from infancy to adulthood. The disease is found globally affecting 1 in every 500 people [2]. It is the leading cause of sudden death in young people. It is caused by mutations in cardiac sarcomere protein genes [3]. HCM is a familial disease in about 60% of cases with an autosomal dominant mode of inheritance, with incomplete and age-dependent penetrance [4]. Anderson-Fabry disease is the most common metabolic disorder associated with HCM with a prevalence of around 0.5–1% in patients older than 35–40 years [5], pathologically HCM is characterized by idiopathic symmetrical or asymmetric cardiac hypertrophy, fibrosis and cardiomyocyte disarray [6].

Clinically most patients with HCM are without symptoms and may be detected incidentally. But some patients experience symptoms that include; chest pain, dizziness, shortness of breath, palpitations, fatigue, and inability to perform vigorous exercise. They commonly die from sudden cardiac death [7]. Symptoms experienced usually result from

impaired sarcoplasmic calcium kinetics and myofibre disarray [8]. This may lead to left ventricular outflow tract (LVOT) obstruction, mitral regurgitation, myocardial ischemia, diastolic dysfunction, abnormal vascular responses, and supraventricular and ventricular arrhythmias [9].

Hypertrophic cardiomyopathy may be suspected based on the above symptoms and or strong family history. ECG may be important in evaluating an HCM patient but the diagnosis is confirmed using an echocardiogram. 75- 90% of HCM cases usually have abnormal ECG findings in the form of overt left ventricular hypertrophy [10]. Diagnostic criteria for HCM in an adult is defined by a wall thickness ≥ 15 mm in one or more LV myocardial segments—as measured by any imaging technique (echocardiography, cardiac magnetic resonance imaging (CMR) or computed tomography (CT))—that is not explained solely by loading conditions [1]. In situations of the lesser degree of wall thickness, 13-14mm, it is important to evaluate the patient for other features including family history, non-cardiac symptoms and signs, electrocardiogram (ECG) abnormalities, laboratory tests and multi-modality cardiac imaging for the diagnosis of HCM [1]. Other important echocardiogram findings in HCM include; Assessment of LVOT obstruction, systolic anterior motion – SAM, assessment of systolic and diastolic LV

function and left atrial size [1], [11], [12]. This article reports a case of familial hypertrophic cardiomyopathy which was detected in Kumasi, Ghana.

CASE PRESENTATION

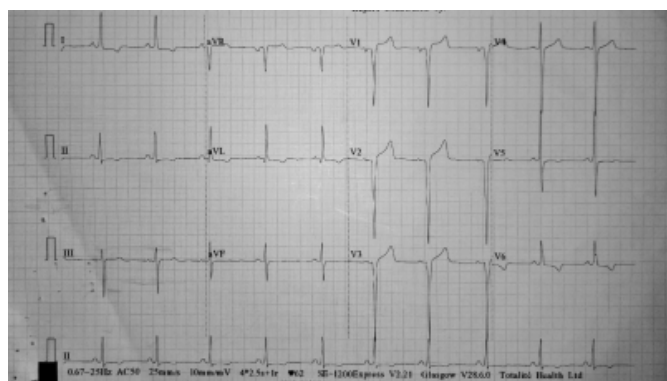
We report a case of a 31-year-old woman who was referred to us with a history of recurrent palpitations, chest pain and dyspnoea over the previous eight months. The patient had no syncopal episodes. She had no family history of similar symptoms to what she presented with nor sudden cardiac death. The significant examination finding was a double impulse apical cardiac beat, on palpation.

The patient presented with a chest radiograph which showed some cardiomegaly, with a cardiothoracic ratio of 0.52, and more significantly, an electrocardiogram which suggested:

- i. left atrial enlargement
- ii. left ventricular hypertrophy, fulfilling by the Cornell voltage criteria
- iii. narrow, deep Q waves, of uncertain etiology in leads V1 and V2
- iv. repolarization abnormalities in leads I, II, aVL V5,V6

Figure 1

A 12-lead ECG of the index patient showing deep Q waves in V1 and V2, left ventricular hypertrophy and T wave inversions in the lateral leads



Based on the history and electrocardiogram findings, hypertrophic cardiomyopathy was suspected. A transthoracic 2-dimensional echocardiogram was done, which showed evidence of

- a. severe asymmetrical septal hypertrophy with left ventricular outflow tract obstruction in systole, with septal wall thickness: 21.2 mm. Left ventricular posterior wall thickness was 9.1 mm. Ratio of septal wall thickness to left ventricular posterior wall thickness was 2.3
- b. dilated left atrium

c. systolic anterior motion of the anterior mitral valve leaflet

d. normal left ventricular systolic function

Figure 2

Transthoracic echocardiogram (Parasternal short axis view at the level of papillary muscles) of the index patient, showing asymmetric septal hypertrophy.

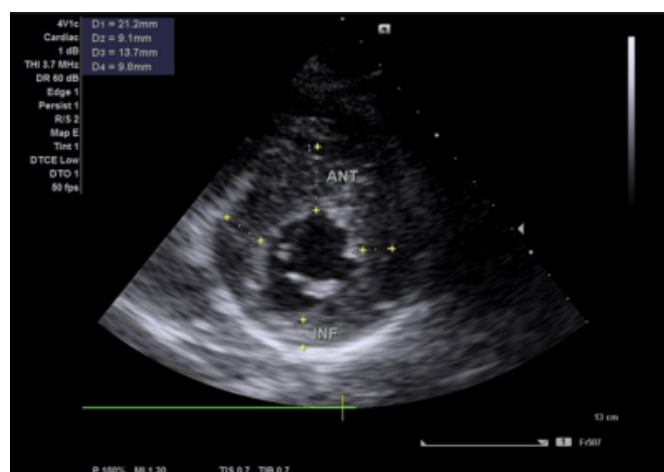
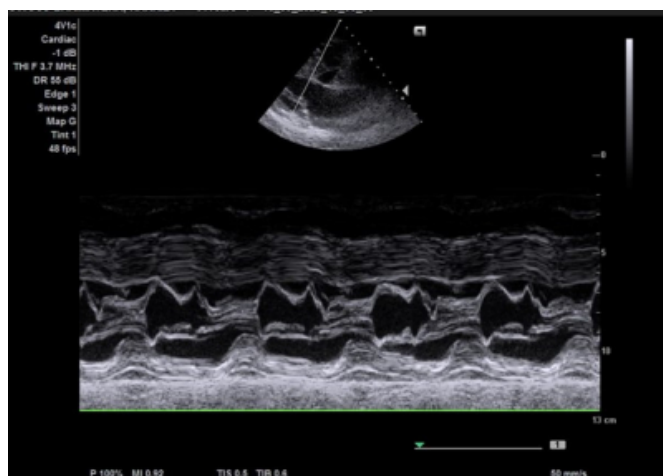


Figure 3

Transthoracic echocardiogram (M mode of parasternal long axis view) of the index patient, showing thickened interventricular septum with SAM demonstrated by contact of the anterior mitral valve leaflet with the septum.



A Holter electrocardiogram showed secondary repolarization abnormalities, left ventricular hypertrophy, occasional monomorphic premature ventricular contractions and a single ventricular couplet.

The patient's risk for sudden cardiac death was assessed as follows:

Table 1

Major Risk Factor	
History of cardiac arrest or spontaneous sustained ventricular tachycardia	Negative
Syncope	Negative
Family history of sudden cardiac death	Negative
Spontaneous non-sustained ventricular tachycardia	Negative
Left ventricular thickness > 30mm	Negative
Abnormal blood pressure response to exercise	Not assessed

Adapted from [13]

The patient was classified as relatively low risk for sudden cardiac death from hypertrophic cardiomyopathy from the accepted baseline risk of 0.5% per year [13]. She was subsequently started on bisoprolol, a beta blocker and was advised to avoid vigorous physical activity. She is on regular follow-up at the cardiology clinic.

Screening of her immediate family was done. The patient comes from a family of 5; mother, father and 3 male siblings. None of the relative had any symptom of a sort. Consent was sought from 4 of the patient’s relatives excluding the father (He lives in another country) for screening with an echocardiogram. Two (mother, one brother) out four, gave consent for the screening. Out the two, the echocardiogram diagnostic criteria was met in the mother but not the brother.

Figure 4

A 12-lead ECG of the index patient’s mother left ventricular hypertrophy and T wave inversions in the lateral leads

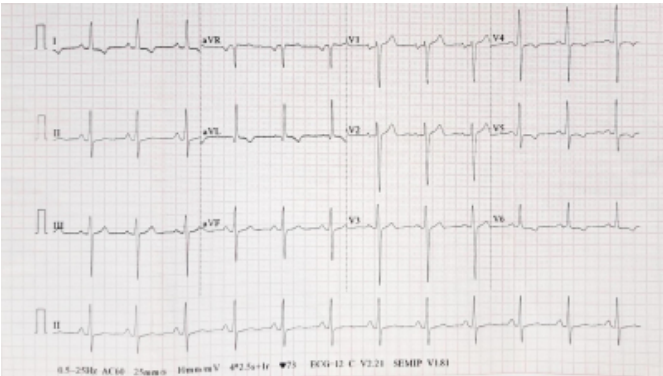


Figure 5

Transthoracic echocardiogram (M mode of parasternal long axis view) of the index patient’s mother showing thickened interventricular septum

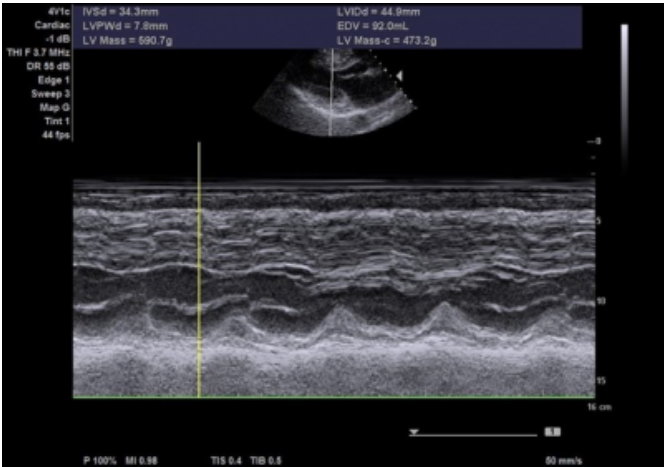
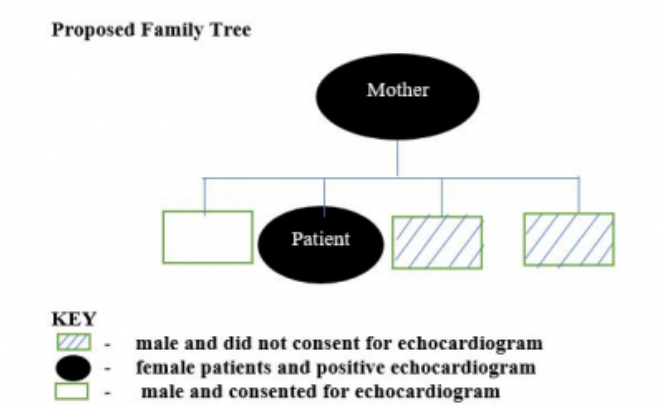


Figure 6

Proposed Family Tree



DISCUSSION

People with hypertrophic cardiomyopathy may present with dyspnoea, syncopal and pre-syncopal symptoms, angina pectoris, palpitations, dizziness, signs of heart failure and most devastatingly, sudden cardiac death [13]. In this report, the patient had been asymptomatic until about 8 months prior to presentation when she started experiencing the above symptoms. Most cases of HCM may be asymptomatic as in the case of the patient’s mother, and may only be detected during screening.

Hypertrophic cardiomyopathy was for a long time thought to be rare in Africa, without adequately screening for it. With the increasing availability of electrocardiograms, echocardiograms and other forms of cardiac imaging, the prevalence has been found to be clinically significant, with

rates similar to those found elsewhere [14], [15]. Click or tap here to enter text. For example, hypertrophic cardiomyopathy accounted for 9.4% of patients with cardiomyopathies who were referred to the National Cardiothoracic Centre, Accra, Ghana for heart failure over a four-year period [16]. Click or tap here to enter text. A macroscopic autopsy study of cardiomegaly conducted at the Korle Bu Teaching Hospital Mortuary over three years found the prevalence of hypertrophic cardiomyopathy to be 5% [17]. Click or tap here to enter text. Hypertrophic cardiomyopathy accounted for about 2% of people referred for echocardiography over a two-year period at Lagos University Teaching Hospital [18]. Click or tap here to enter text. Similarly, the aetiology, based on extensive genetic investigations in South Africa, has been found to be comparable to those of Europe and America [14].

Adult ventricular wall thickness ≥ 15 mm in one or more LV myocardial segments is diagnostic for HCM [1]. In this study, the patient had a left ventricular wall thickness of 21.2 mm. Other important echocardiogram findings in the patient included a dilated left atrium and systolic anterior motion of the anterior mitral leaflet. The size of the left atrium in HCM often provide an important prognostic factor. It may indicate the presence and severity of mitral regurgitation and diastolic dysfunction and a possible atrial myopathy [19]. Systolic anterior motion (SAM) has been described long ago as a feature of HCM even though it can also be observed in conditions other than HCM [20]. SAM may lead to left ventricular outflow tract obstruction [11]. Diastolic dysfunction is a frequent finding in HCM [1]. It is caused by the increased interstitial fibrosis and the slowed relaxation and increased stiffness of the thickened ventricular wall [4]. The patient in this case report however did not have diastolic dysfunction. She also had a normal left ventricular systolic function.

CONCLUSION

It is important that patients, especially young adults who otherwise would be deemed as healthy, who present with suggestive symptoms should be investigated for hypertrophic cardiomyopathy, with the tools that are available, especially the diagnostic modality of choice: two-dimensional Doppler echocardiography.

References

[1] J. L. Zamorano et al., "2014 ESC guidelines on diagnosis and management of hypertrophic cardiomyopathy: The task force for the diagnosis and management of hypertrophic cardiomyopathy of the European Society of Cardiology (ESC)," *Eur. Heart J.*, vol. 35, no. 39, pp. 2733–2779, 2014,

doi: 10.1093/eurheartj/ehu284.

[2] B. J. Maron and M. S. Maron, "Hypertrophic cardiomyopathy," *Lancet*, vol. 381, no. 9862, pp. 242–255, 2013, doi: 10.1016/S0140-6736(12)60397-3.

[3] N. Frey, M. Luedde, and H. A. Katus, "Mechanisms of disease: Hypertrophic cardiomyopathy," *Nat. Rev. Cardiol.*, vol. 9, no. 2, pp. 91–100, 2012, doi: 10.1038/nrcardio.2011.159.

[4] A. J. Marian and E. Braunwald, "Hypertrophic cardiomyopathy: Genetics, pathogenesis, clinical manifestations, diagnosis, and therapy," *Circ. Res.*, vol. 121, no. 7, pp. 749–770, 2017, doi: 10.1161/CIRCRESAHA.117.311059.

[5] P. Elliott et al., "Prevalence of Anderson-Fabry disease in patients with hypertrophic cardiomyopathy: The European Anderson-Fabry Disease Survey," *Heart*, vol. 97, no. 23, pp. 1957–1960, 2011, doi: 10.1136/heartjnl-2011-300364.

[6] C. J. McLeod et al., "Histologic characterization of hypertrophic cardiomyopathy with and without myofibrillar mutations," *Am. Heart J.*, vol. 158, no. 5, pp. 799–805, 2009, doi: 10.1016/j.ahj.2009.09.006.

[7] S. R. Ommen et al., "2020 AHA/ACC Guideline for the Diagnosis and Treatment of Patients with Hypertrophic Cardiomyopathy: Executive Summary: A Report of the American College of Cardiology/American Heart Association Joint Committee on Clinical Practice Guidelines," *Circulation*, pp. 533–557, 2020, doi: 10.1161/CIR.0000000000000938.

[8] A. Malhotra and S. Sharma, "Hypertrophic cardiomyopathy in athletes," *Eur. Cardiol. Rev.*, vol. 12, no. 2, pp. 80–82, 2017, doi: 10.15420/ecr.2017.12.1.

[9] S. Sen-Chowdhry, D. Jacoby, J. C. Moon, and W. J. McKenna, "Update on hypertrophic cardiomyopathy and a guide to the guidelines," *Nat. Rev. Cardiol.*, vol. 13, no. 11, pp. 651–675, 2016, doi: 10.1038/nrcardio.2016.140.

[10] B. J. Maron, "The electrocardiogram as a diagnostic tool for hypertrophic cardiomyopathy: Revisited," *Ann. Noninvasive Electrocardiol.*, vol. 6, no. 4, pp. 277–279, 2001, doi: 10.1111/j.1542-474X.2001.tb00118.x.

[11] A. Pantazis, A. S. Vischer, M. C. Perez-Tome, and S. Castelletti, "Diagnosis and management of hypertrophic cardiomyopathy," *Echo Res. Pract.*, vol. 2, no. 1, pp. R45–R53, 2015, doi: 10.1530/ERP-15-0007.

[12] V. M. Parato et al., "Echocardiographic diagnosis of the different phenotypes of hypertrophic cardiomyopathy," *Cardiovasc. Ultrasound*, vol. 14, no. 1, pp. 1–12, 2016, doi: 10.1186/s12947-016-0072-5.

[13] N. K. Lakdawala, L. W. Stevenson, and J. Loscalzo, "Cardiomyopathy and Myocarditis," in *Harrison's Principles of Internal Medicine*, 20e, J. L. Jameson, A. S. Fauci, D. L. Kasper, S. L. Hauser, D. L. Longo, and J. Loscalzo, Eds. New York, NY: McGraw-Hill Education, 2018.

[14] A. O. Falase and O. S. Ogah, "Cardiomyopathies and myocardial disorders in Africa: Present status and the way forward," *Cardiovasc. J. Afr.*, vol. 23, no. 10, pp. 552–562, Nov. 2012, doi: 10.5830/CVJA-2012-046.

[15] K. Sliwa, A. Damasceno, and B. M. Mayosi, "Epidemiology and etiology of cardiomyopathy in Africa," *Circulation*, vol. 112, no. 23, pp. 3577–3583, 2005, doi: 10.1161/CIRCULATIONAHA.105.542894.

[16] A. G. B. Amoah and C. Kallen, "Aetiology of heart failure as seen from a national cardiac referral centre in africa," *Cardiology*, vol. 93, no. 1–2, pp. 11–18, 2000, doi: 10.1159/000006996.

[17] A. Akosa and H. Armah, "Cardiomegaly in Ghana: An Autopsy Study," *Ghana Med. J.*, vol. 39, no. 4, p. 122, 2005, Accessed: Feb. 15, 2021. [Online]. Available: /pmc/articles/PMC1790827/.

[18] A. Mbakwem, D. Oke, and J. Ajuluchukwu, "Hypertrophic Cardiomyopathy in South Western Nigeria," *SA Hear.*, 2017, doi: 10.24170/6-2-1998.

[19] S. F. Nagueh et al., "American society of echocardiography clinical recommendations for multimodality cardiovascular imaging of patients with hypertrophic cardiomyopathy: Endorsed by the American society of nuclear cardiology, society for cardiovascular

magnetic resonance, and," *J. Am. Soc. Echocardiogr.*, vol. 24, no. 5, pp. 473–498, 2011, doi: 10.1016/j.echo.2011.03.006.

[20] D. R. Boughner, R. L. Schuld, and J. A. Persaud, "Hypertrophic obstructive cardiomyopathy: Assessment by echocardiographic and Doppler ultrasound techniques," *Heart*, vol. 37, no. 9, pp. 917–923, 1975, doi: 10.1136/hrt.37.9.917.

Author Information

Yaw Adu-Boakye

Komfo Anokye Teaching Hospital; Kwame Nkrumah University of Science and Technology
Kumasi, Ghana

Isaac Nana Ogyefo

Komfo Anokye Teaching Hospital
Kumasi, Ghana

Jeffery Kudiabor

Komfo Anokye Teaching Hospital
Kumasi, Ghana

Gyabaah Solomon

Komfo Anokye Teaching Hospital
Kumasi, Ghana