

Root Caries: An Aging Problem

B Gupta, C Marya, V Juneja, V Dahiya

Citation

B Gupta, C Marya, V Juneja, V Dahiya. *Root Caries: An Aging Problem*. The Internet Journal of Dental Science. 2006 Volume 5 Number 1.

Abstract

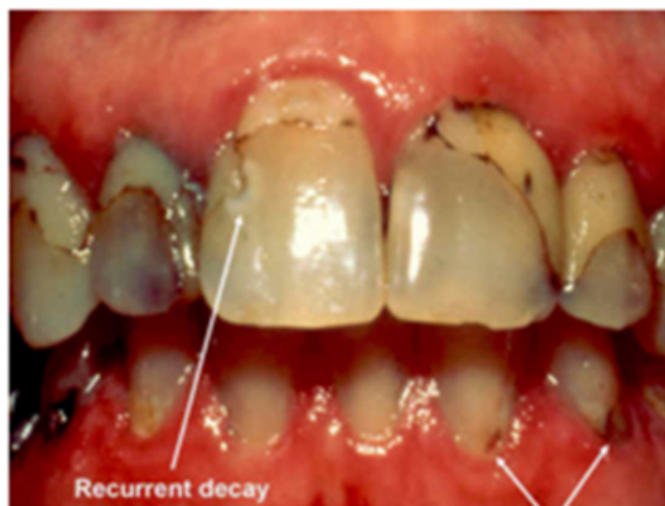Root caries is a lesion located on the root surface of a tooth, usually close to or below the gingival margin. Root caries has become an important dental problem because people are living longer and keeping their teeth longer. As patients grow older, their gums recede and root surfaces are exposed, making them more susceptible to root caries. Any caries-prone patient having gingival recession can develop root caries. However, the elderly are usually more vulnerable to root caries because of several medical conditions. Many older patients use medications that reduce saliva flow and cause them to have a dry mouth. Root caries can be diagnosed by a dentist during regular dental examination. X-rays are also helpful to diagnose root caries. Treatment of root caries generally requires the placement of a restoration or crown.

INTRODUCTION

Root caries is a common problem among the elderly. Root caries, by definition, occurs on the root of the tooth. The term “primary” as it is used with root caries refers to new dental caries occurring in the absence of a restoration. Secondary (recurrent) root caries refers to caries occurring adjacent to an existing restoration. (Figure 1)

Figure 1

Figure 1: Photograph showing recurrent caries on 11 & root caries on mandibular teeth.



Root caries most often occurs supragingivally, at or close to (within 2 mm) the cemento-enamel junction. This phenomenon is due to the location of the gingival margin at the time conditions were favorable for caries to occur. The location of root caries has been positively associated with

age and gingival recession. Root caries occurs in a location adjacent to the crest of the gingiva where dental plaque accumulates. They occur predominantly on the proximal (mesial and distal) surfaces, followed by the facial surface.

It afflicts a large percentage of geriatric patients and is a very difficult problem for dentists to manage. The etiology of root caries is multifactorial. The factors implicated in the development of root lesions include dietary habits, microbial plaque, and a decreased salivary flow. Root lesions are often very difficult to restore due to their location, problems with moisture control, and proximity to the pulp and are therefore prone to high recurrence rates. The treatment and management considerations for root caries vary depending upon the extent and location of the lesion, as well as the type of materials being used. Under normal circumstances, this loss of calcium (demineralization) is compensated for by the uptake of calcium (remineralization) from the tooth's microenvironment. This dynamic process of demineralization and remineralization takes place more or less continually and equally in a favorable oral environment. In an unfavorable environment, the remineralization rate does not sufficiently neutralize the rate of demineralization, and caries occurs. (1,2,3,4,5,6)

PREVALENCE

The reported percentage of new lesions developing were ranging from 36% to 67% (2,7,8,9,10). Hellyer 1990 reported the prevalence of 88.4% in 55 years and above aged people. (11) S.Imazato reported that 39% of the subjects had one or

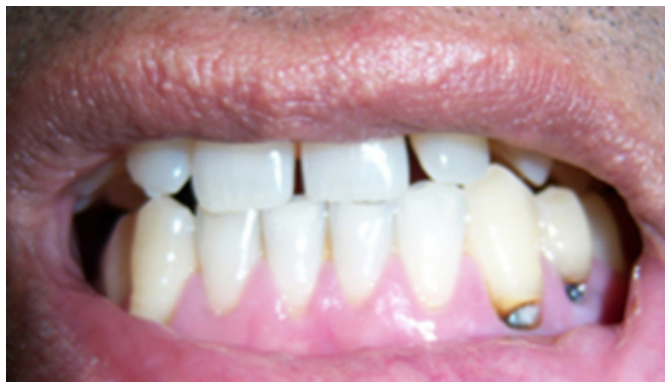more decayed roots and 53.3% had at least one decayed or filled lesion. Root caries was seen most frequently on canine teeth followed by first premolar.⁽¹²⁾

CLINICAL FEATURES

The clinical investigators who studied root caries provided clinical descriptions of the signs and symptoms of root caries lesions. The most commonly used clinical signs to describe root caries utilized visual (color, contour, surface cavitation), and tactile (surface texture) specifications (Figure 2). There are no reported clinical symptoms of root caries although pain may be present in advanced lesions.^(13,14,15,16)

Figure 2

Figure 2: Photograph showing root caries in 33 & 34.



DISTRIBUTION WITH IN THE MOUTH

There is a characteristic distribution for root caries lesions within the oral cavity.

Mandibular molars most effected followed by maxillary anterior teeth & maxillary posteriors. Mandibular anteriors seem to be least susceptible. The buccal and interproximal surfaces are more susceptible than the palatal or lingual aspect of affected teeth. ⁽¹⁵⁾

RISK FACTORS

Risk factors associated with the high prevalence of root caries among older adults include:

- Decrease salivary flow or xerostomia,
- Exposure of root surfaces due to periodontal (gum) disease,
- Chronic medical conditions,
- Radiation treatment for head and neck cancer,
- Physical limitations,

- Diminished manual dexterity due to stroke, arthritis, or Parkinson's disease,
- Cognitive deficits due to mental illness, depression, Alzheimer's disease or dementia, Sjögren's syndrome (an autoimmune disease),
- Diabetes,
- Poor oral hygiene,
- Multiple medication use,
- Changes in dietary habits.
- Previous root caries experience, either in the form of filled surfaces or decayed untreated lesions is also a potent risk factor for the development of new lesions (17)
- Serum albumin concentration :A. Yoshihara (2003)conducted a study to evaluate, by serum albumin concentrations, the relationship between the general health condition and root caries. The findings of the study indicated that a relationship between root caries and serum albumin concentration in these elderly subjects is highly possible. (18)

MICROBIOLOGICAL ASPECT

The organisms most commonly associated with root caries are *Actinomyces viscosus* / *naeslundii*, *Streptococcus mutans*, *Lactobacilli*, and *Candida* species. Jordan and Hammond(1972) suggested Gram-positive filamentous bacteria.⁽¹⁹⁾

Ellen et al(1985) in their study suggested that species other than those regarded as potential pathogens could be associated in high numbers with root lesions and caries-free root surfaces.⁽²⁰⁾ Brown et al. (1986) pointed out that the flora was more complex than reported and included *Rothia* and *Bifidobacterium*.⁽²¹⁾

Keltjens et al. (1987) recorded their lesions as 'soft' and 'hard'. They found significantly higher numbers of *S. mutans* associated with the 'soft' lesions. No significant differences were detected between caries-free surfaces and the 'hard' lesion surfaces.⁽²²⁾

Emilson et al. (1988) noted extreme variability in the contribution of *mutans streptococci* to the cultivable flora and were unable to show significant differences between the

contributions of 'mutans streptococci' to sound and carious root surfaces.⁽²³⁾

DIAGNOSIS OF ROOT CARIES

Various tests have been used for the diagnosis of root caries. Clinicians look to diagnostic tests in the hope that, can a diagnostic test increase or decrease the clinician's "best guess" as to Whether root caries is or is not present? Depending on the test, clinicians can disagree as to whether the test is positive or negative.

MICROBIOLOGICAL

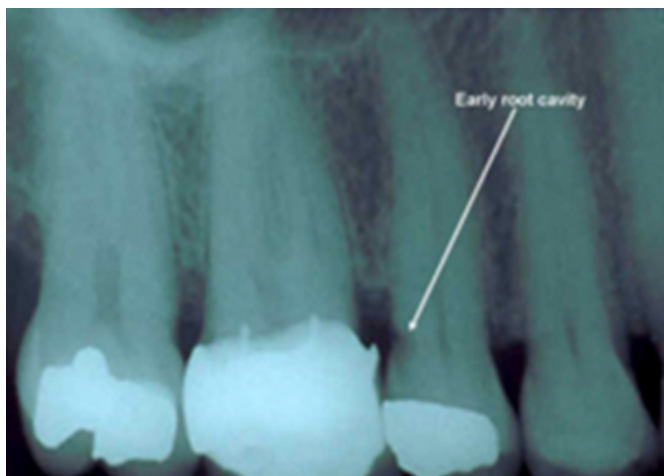
The Tests determining the presence or absence of mutans streptococci and Lactobacilli are the known to be clinically helpful.

RADIOGRAPHS

For the proximal surfaces, radiography produces good results, but the supporting evidence is weak. (Figure 3).

Figure 3

Figure 3: IOPA X-Ray with root caries in premolar.



FLUOROGENIC ENZYME ASSAY

Used by Collier et al. estimates bacterial counts, particularly mutans streptococci and Lactobacilli, in plaque overlying root caries and, therefore, supports the evidence for mutans streptococci and Lactobacilli diagnostic tests.

Estimation of the Salivary secretion rate. Salivary buffer effect . Oral sugar clearance time. Fluorescent Dye and Diazonium dye. ^(24*25*26*27*28*29*30*31*32)

MANAGEMENT OF ROOT CARIES

PREVENTION (PRIMARY AND SECONDARY)

1. Identification of risk factors for root caries at the individual level.

2. An accurate diagnosis of root caries.
3. Dietary, oral hygiene and correct brushing advice.
4. Appropriate fluoride regimens such as high fluoride (e.g., 5 000ppm) dentifrice, gel, varnish.
5. Prescribe, if appropriate chlorhexidine (as a mouthwash, spray, gel or varnish), other similar Antiseptics, and/or remineralizing products with calcium phosphopeptide-amorphous calcium Phosphate (CPP-ACP).
6. Prescribe regimens to stimulate salivary flow, such as chewing gum with or without the inclusion of active ingredients (e.g., chlorhexidine, xylitol, CPP-ACP), sucking sugarless candies, sucking buffered citric/fruit acid tablets, using systemic cholinergic medications (e.g., pilocarpine/ cimeviline, with monitoring of adverse effects)
7. Prescribing saliva substitutes, such as gels, sprays and liquids, with placement around dentures as well as on teeth and oral soft tissues.
8. Review patients on a schedule appropriate to their level of risk (17)

TREATMENT

1. Remineralization: Depending on the depth and extension of the lesion, management may include remineralization, There is no doubt that remineralization of a carious root surface lesion is practicable. The remineralised surface is dark brown or black with a leathery texture initially and eventually hardens to a give a polished highly mineralized surface.
2. Surface Recontouring: The earliest form of interception should be removal of softened tissue, followed by the recontouring of the root structure to give it a smooth and cleansable surface.
3. Restoration of the Defect; Once the carious lesion has been established ,The repair of the lesion in the form of a restoration becomes mandatory. Caries removal using hand instruments, supplemented by chemo-mechanical caries removal systems, may be appropriate for specific groups of patients. There is some evidence that glass-ionomer cement (conventional or resin-modified) may be the

material of choice for the restoration of root caries lesions, especially if sub-gingival.(17)

Several materials and procedures can be used to restore decayed roots. However, the type of restoration will be determined based on several factors. These factors include:

- the extent and severity of the decay
- the patient's age and socioeconomic status
- the patient's motivation to improve oral health
- the patient's esthetic concerns

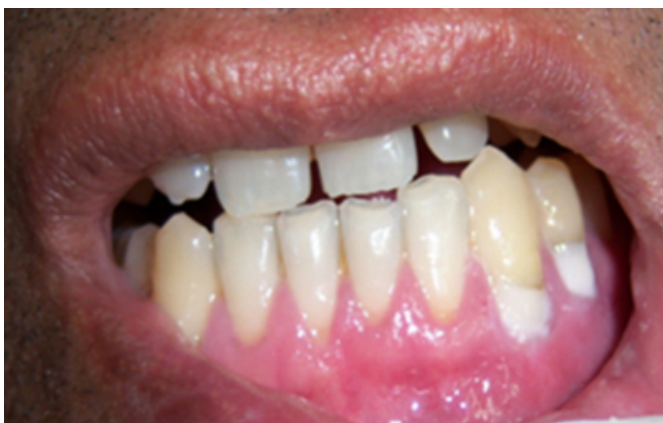MATERIALS USED IN RESTORING SEVERE CAVITATIONS:

GLASS IONOMER WITH FLUORIDE RELEASE .(FIGURE 4)

- is the material of choice
- does not cause pulpal irritation
- contains 20% fluoride
- is relatively easy to place and esthetically compatible
- is anticariogenic, antibacterial, and adhesive to root structure

Figure 4

Figure 4: Teeth restored with Glass Ionomer filling.



RESIN COMPOSITE:

- is not used as much as glass ionomer with fluoride
- is not recommended for patients with poor oral hygiene

- is not as effective as glass ionomer in releasing the fluoride it contains
- can be used in patients with good oral hygiene

AMALGAM WITH FLUORIDE RELEASE:

- is not a preferred material to use in root caries restoration
- may not be considered safe by patients
- is difficult to place due to location of decay

In order for a material to be considered adequate for use in restoring root surface caries it should: provide a good seal between the restoration and tooth, be esthetically compatible, be easy to place, and provide continuous fluoride release.

Ozone Therapy: Ozone can be considered as an alternative management strategy for root caries. Recently, it has been shown that ozone application was effective to kill the great majority of micro-organisms in primary root carious lesions (PRCLs), which has been validated by a root caries severity index and clinical diagnostic criteria for PRCLs. The ozone delivery system is a portable apparatus with an ozone generator for the treatment of caries and delivers ozone at a concentration of 2,100 ppm. The vacuum pump pulls air through the generator to supply ozone to the lesion and purges the system of ozone after ozone treatment.

Use of 10% sodium hypochlorite (oxidant) on demineralised root dentine lesions improved their potential to remineralise since sodium hypochlorite is a non-specific proteolytic agent. Studies have shown that when root dentine samples were treated with sodium hypochlorite, the permeability of fluoride ions increased. Removal of organic materials from dentine lesions was an acceptable approach to enhance remineralisation.(33*34*35*36*37*38*39)

References

1. David W. Banting, The Diagnosis of Root Caries. Journal of Dental Education. 2001, 65: 10:991-996.
2. Banting DW, Ellen RP, Fillery ED. A longitudinal study of root caries: baseline and incidence data. J Dent Res. 1985;64(9):1141-1144.
3. Lynch E, Beighton D. A comparison of primary root caries lesions classified according to colour. Caries Res. 1994;28(4):233-239.
4. Shaeken MJM, Keltjens HMAM, Van der Hoeven JS. Effects of fluoride and chlorhexidine on the microflora of dental root surfaces and progression of root-surface caries. J

Dent Res. 1991;70(2):150-153.

5. Fure S. Five-year incidence of coronal and root caries in 60-, 70- and 80-year-old Swedish individuals. *Caries Res.* 1997;31:249-258.

6. Banting DW, Papas A, Clark DC, Proskin HM, Schultz M, Perry R. The effectiveness of 10% chlorhexidine varnish treatment on dental caries incidence in adults with dry mouth. *Gerodontology.* 2001;17(2):2-11.

7. Hand JS, Hunt RJ, Beck JD. 1988 Coronal and root caries in older Iowans: 36-month incidence. *Gerodontics.* 1988 Jun;4:136-139.

8. Wallace MC, Reteif DH, Bradley E L Incidence of root caries in older adults.

9. 1988 Aug;19(8):8

10. MacEntee MI, Clark DC, GLICK N. Predictors of caries in old age. *Gerodontology* 1993;10:90-97.

11. Ravald N, Hamp SE, Birkhed D. Long term evaluation of root surface caries in periodontally treated patients. *J Clin Perio.* 1986;13:758-767

12. Hellyer, Beighton et al. Root caries in Older people attending a general dental practice in East Sussex. *Brit Den Journal* 1990;169:7:201-206

13. S. IMAZATO, K. IKEBE, T. NOKUBI, S. EBISU, A. W. G. WALLS . Prevalence of root caries in a selected population of older adults in Japan . *Journal of Oral Rehabilitation.* 2006 ; 33 (2), 137-143.

14. Hix JO, O'Leary TJ. The relationship between cemental caries, oral hygiene status and fermentable carbohydrate intake. *J. Periodontol* 1976;47:398-404.

15. Banting DW, Ellen RP, Fillery ED. Prevalence of root surface caries among institutionalized older persons. *Community Dent Oral Epidemiol.* 1980;8:84-88.

16. Katz RV, Hazen SP, Chilton NW, Mumma RD. Prevalence and intraoral distribution of root caries in an adult population. *Caries Res.* 1982;16:265-271.

17. Vehkalahti MM, Rajala M, Tuominen R, Paunio I. Prevalence of root caries in the adult Finnish population. *Community Dent Oral Epidemiol.* 1983;11:188-190.

18. J J Murray. The prevention of oral disease. Third edition .Oxford university press 1996:174-181.

19. Yoshihara A, Hanada N, and Miyazaki M. Association between Serum Albumin and Root Caries in Community-dwelling Older Adults. *J Dent Res.* 2003; 82(3): 218-222.

20. Jordan H.V. and Hammond B.F. Filamentous Bacteria Isolated from Human Root Surface Caries. *Arch Oral Biol.* 1972; 17:1333-1342.

21. Ellen R.P.; Banting D.W.; and Fillery E.D. Streptococcus mutans and Lactobacillus Detection in the Assessment of Dental Root Surface Caries Risk. *J Dent Res.* 1985; 64:1245- 1249.

22. Brown L.R.; Billings R.J.; and Kaster A.G. Quantitative Comparisons of Potentially Cariogenic Microorganisms Cultured from Non-carious and Carious Root and Coronal Surfaces. *Infect Immun.* 1986; 51:765-770.

23. Keltjens H.M.A.; Schaeken M.J.M.; Van der Hoeven J.S.; and Hendricks J.C.M. Microflora of Plaque from Sound and Carious Root Surfaces. *Caries Res.* 1987; 21:193-199.

24. Emilson C.G.; Klock B.; and Sanford C.B. Microbial Flora Associated with Presence of Root Surface Caries in Periodontally Treated Patients. *Scand J Dent Res.* 1988; 96:40-49.

25. Ravald N. Root surface caries. *Current Opinion in Periodontol.* 1994:78-86.

26. Ravald N, Birkhed D. Factors associated with active and inactive root caries in patients with periodontal disease. *Caries Res.* 1991;25:377-84.

27. Scheinin A, Pienihakkinen K, Tiekso J, Holmberg S, Fukuda M, Suzuki A. Multifactorial modeling for root caries prediction: 3-year follow-up results. *Community Dent Oral Epidemiol.* 1994;22(2):126-129.

28. Nordenram G, Bergvit A, Johnson G, Henriksson CO, Anneroth G. Macroscopic and radiologic examination of proximal root surface caries. *Acta Odont Scand* 1988;46:95-99.

29. van der Veen MH, ten Bosch JJ. An in vitro evaluation of fluorescein penetration into natural root surface carious lesions. *Caries Res.* 1993;27(4):258-261.

30. van der Veen MH, ten Bosch JJ. A fiber-optic setup for quantification of root surface demineralization. *Eur J Oral Sci.* 1996;104(2 [Pt 1]):118-122.

31. van der Veen MH, Tsuda H, Arends J, ten Bosch JJ. Evaluation of sodium fluorescein for quantitative diagnosis of root caries. *J Dent Res.* 1996;75(1):588-593.

32. Collier FI, Heath MR, Lynch E, Beighton D. Assessment of the clinical status of primary root caries lesions using an enzymatic dye. *Caries Res.* 1993;27(1):60-64.

33. Wilkinson SC, Higham SM, Ingram GS, Edgar WM. Visualization of root caries lesions by means of a diazonium dye. *Adv Dent Res.* 1997;11(4):515-522.

34. Baysan A, R. Whiley, Lynch E: Anti-microbial effects of a novel ozone generating device on micro-organisms associated with primary root carious lesions in vitro. *Caries Res.* 2000; 34: 498-501.

35. Baysan A, Lynch E, Ellwood R, Davies R, Petersson L, Borsboom P: Reversal of primary root caries using dentifrices containing 5,000 and 1,100 ppm fluoride. *Caries Res.* 2001; 35: 41-46.

36. Baysan A, Lynch E, Grootveld M: The use of ozone for the management of primary root carious lesions. *Tissue Preservation and Caries Treatment.* Quintessence Book 2001, Chapter 3, p. 49-67.

37. Beighton D, Lynch E, Heath MR: A microbiological study of primary root caries lesions with different treatment needs. *J Dent Res.* 1993; 73: 623-629.

38. Emilson CG: Effects of chlorhexidine gel treatment on Streptococcus mutans population in human saliva and dental plaque. *Scand J Dent Res.* 1981; 89: 239-246.

39. Inaba D, Duscher H, Jongebloed W, Odelius H, Takagi O, Arends J: The effects of a sodium hypochlorite treatment on demineralized root dentin. *Eur J Oral Sci.* 1995; 103: 368-374.

40. Inaba D, Ruben J, Takagi O, Arends J: Effects of sodium hypochlorite treatment on remineralization of human root dentine in vitro. *Caries Res.* 1996; 30: 214-218.

Author Information

Bhavna Gupta, BDS, MDS

Senior Lecturer, Department Of Pedodontics, Sudha Rustagi College of Dental Sciences & Research

C. M. Marya, BDS MDS

Professor & Head, Department Of Community Dentistry, Sudha Rustagi College of Dental Sciences& Research

Vishal Juneja, BDS

Reader & Head, Department Of Dental Anatomy, Sudha Rustagi College of Dental Sciences& Research

Vandana Dahiya

Dental Surgeon, HCMS