

Management Of A Difficult Airway In A Child With Epidermolysis Bullosa Dystrophica Using An LMA In Combination With Video Laryngoscopy

J J Choi, R Abrams, M Greenberg

Citation

J J Choi, R Abrams, M Greenberg. *Management Of A Difficult Airway In A Child With Epidermolysis Bullosa Dystrophica Using An LMA In Combination With Video Laryngoscopy*. The Internet Journal of Anesthesiology. 2022 Volume 41 Number 1.

DOI: [10.5580/IJA.56446](https://doi.org/10.5580/IJA.56446)

Abstract

We describe a novel approach to airway management in a patient with Dystrophic Epidermolysis Bullosa (DEB). Within a time frame of two weeks, a series of two surgeries were planned to repair this patient's recurrent syndactyly and flexion contractures. Due to the patient having a known difficult airway a Laryngeal Mask Airway (LMA) was used to maintain the airway during both cases. We outline the use of video laryngoscopy during LMA insertion, and inspection of the airway before and after use in each case. We found no damage due to the LMA or the laryngoscope in either case. In patients with EB requiring general anesthesia, we conclude that LMA insertion and use for airway management avoided mucosal damage and was safe, even for multiple cases in close proximity. Use of an LMA for airway management should be considered in EB patients to reduce the risk of intubation trauma, and to prevent skin damage during prolonged mask anesthesia.

INTRODUCTION

Epidermolysis Bullosa (EB) is a rare disorder characterized by fragility of the epidermis involving the formation of bullae, as well as ulcers and erosions after relatively minor trauma¹. These blisters form on the mucocutaneous surfaces due to inherited deficiencies in connective tissue structures (keratin, collagen, laminin)². EB is broadly categorized into three subtypes based on histologic patterns². Dystrophic EB (DEB) is considered the most severe, of the survivable forms, with significant scarring and contractures leading to pseudosyndactyly of digits, esophageal strictures, and contractures of the mouth³. These patients often need multiple surgeries in their childhood, which demand careful anesthetic considerations for positioning, monitoring, and airway management, given their fragile skin, as has been previously described⁴.

Airway management in DEB can be challenging due to pre-existing microstomia, ankyloglossia, laryngeal stenosis, esophageal strictures, GERD, and ease of forming new oropharyngeal blisters⁵. Preoperative evaluation is especially critical in these patients; however, a favorable airway on exam may still pose difficulty due to anatomic variation that

may be unable to be assessed prior to surgery⁶. Cautious preparation is necessary, with back-up airway devices readily available, should direct laryngoscopy prove to be impossible. Even mask ventilation can promote blistering due to shear forces on facial skin⁷. Damage to the oropharyngeal mucosa or laryngotracheal structures can result in severe dysphagia or airway compromise⁸. Spontaneous ventilation without airway manipulation is desired, but may not always be a feasible option^{9,10}.

In this report, we present a patient with Dystrophic Epidermolysis Bullosa, in whom an LMA was used for airway management, in combination with gentle video laryngoscopy for examination of the airway before and after the procedure.

CASE REPORT

The patient is a 14 year-old left-handed male (1.27 m, 22.8 kg) with DEB presenting with recurrent syndactyly and flexion contractures after syndactyly release surgery 5 years prior. He was scheduled for de-cocooning of the left hand with finger flexion contracture release and full thickness skin grafting (Figure 1). The right hand had been repaired 2 years earlier. Of note, the patient was part of an ongoing clinical

study involving regular topical application of gel-impregnated collagen type VII with a viral factor to assist with wound healing on the prior surgical site. With the assistance of his mother at home, the patient worked diligently on daily hand therapy exercises to improve range of motion. He stated that he was able to use his hands to play video games and was performing well with fine motor tasks such as pinching and gripping. He continued to apply AlumaFoam® splints on a daily basis to the fingers and his wrist of his right hand. Functionally, the patient denied significant pain or residual wound problems on his right hand. Healing of the right hand had progressed well, with few remaining healing wounds in the third and fourth web spaces. Upon preoperative examination of the airway, the patient was noted to have limited mouth opening, and was a Mallampati III, worse than for the previous procedure.

Prior to the surgery, a preoperative huddle was performed to familiarize all members of the surgical team to the special needs required of an EB patient, and we used all skin precautions, as has been reported previously. We employed minimal monitoring in an attempt to decrease the risk of skin injury and used a lubricated clip pulse oximeter probe on the ear tragus for heart rate, rhythm and saturation readings. After induction, cuff blood pressures were spaced out to every 15 minutes to minimize pressure and traction on the leg. A lubricated mask was used for induction, with 70% nitrous oxide and increasing concentrations of sevoflurane. Special attention was paid while mask ventilating the patient to prevent skin lesions. Intravenous access was obtained after induction, with a 22 g catheter, which was wrapped with Vaseline gauze and Kling™ rolled gauze, covered with Coban™. Special care was taken to offload compressive pressure from the IV, the IV tubing, and hub on the skin.

The patient was then given 30 mg (1.3 mg/kg) of propofol and 30 mg (1.3 mg/kg) of rocuronium to facilitate laryngoscopy after mask induction. Since this case was to be relatively short and previous intubation had proven to be difficult, the team decided to use a LMA (Air-Q size 2.5). After paralysis was achieved, video laryngoscopy with a lubricated #3 Glidescope™ was performed, yielding an adequate view of the glottis. At this point, under video guidance, the LMA was carefully inserted into optimal position. Using the glidescope as an examination tool a few shallow pre-existing lesions were noted in the oropharynx (Figure 2A) and the LMA was inserted with ease. Optimal

position of the LMA with no leak was confirmed with end tidal CO₂, chest rise, and adequate tidal volumes. No extra gas was added to the LMA, as it was not necessary to get a seal. The LMA was secured with a lubricant-soaked twill tie over Mepilex™ to prevent pressure sores. All points of contact with the skin were lined with Vaseline gauze.

Anesthesia was maintained with sevoflurane and a dexmedetomidine infusion titrated from 0.7 to 2.2 mcg/kg/hr based on heart rate. The patient was ventilated on pressure control settings. To reduce post-operative pain and pruritus, an opioid-free anesthetic was employed. In addition a nerve block was done on the field by the surgeons and weight-based ketorolac and intravenous acetaminophen given at the end of the case.

The surgery proceeded without difficulty, with successful pseudosyndactyly release and full thickness skin grafts (harvested from right groin) placed between the web spaces and middle and ring finger proximal interphalangeal joints (Figure 3). Fingers were fixed in extension with K wires. The groin incision was injected at the start of the case with lidocaine with epinephrine 7 mL 1% 1:100,000 and the wrist blocked at the conclusion of the case with bupivacaine 16 mL 0.25%. The wounds were dressed with xeroform gauze, Kerlix™, and a fiberglass sugar tong cast.

Prior to extubation, the effects of the muscle relaxant were reversed with sugammadex, and all anesthetics were discontinued. The decision was made to extubate the patient while deeply anesthetized to decrease the risk of trauma from coughing and bucking. With the patient still deeply anesthetized, the LMA was carefully removed without apparent complication. With the video laryngoscope, the oropharynx and supra-glottic regions were again assessed for any new trauma or lesions from baseline. No new areas of erythema were observed, and the oropharyngeal lesions noted on first look were re-demonstrated (Figure 2B). The patient was carefully lifted from the operating table to a gurney using a draw sheet that kept his lubricated gel pads in place. He was transferred to PACU where his recovery was unremarkable, without pain, pruritus, nausea, or coughing. He was stable and discharged home the same day. Using the above technique, an identical anesthetic plan and sequence were replicated during the subsequent operation one week later for washout and dressing change. We noted that prior to placing the LMA for the follow up dressing change, there were no new lesions created during the first case.

Figure 1

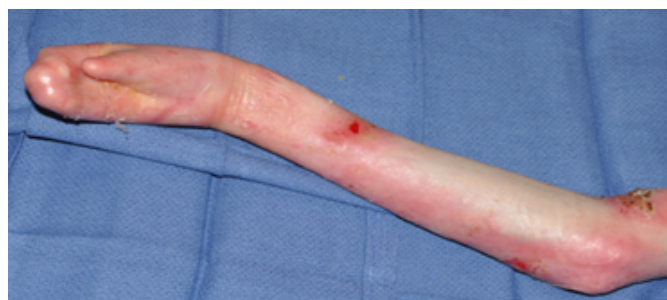

Figure 2

A: pharynx of patient before LMA placement B: Pharynx of patient after LMA removal

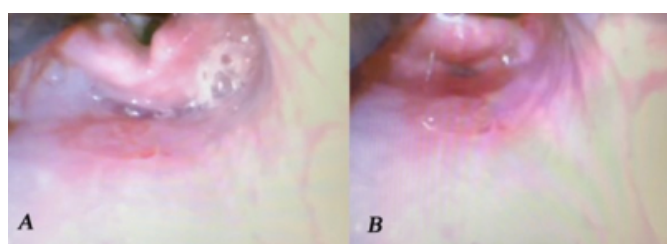
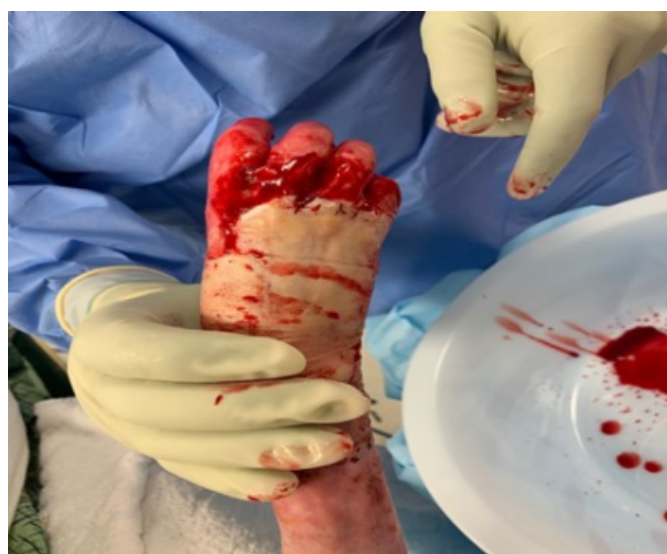

Figure 3



DISCUSSION

Patients with Epidermolysis Bullosa pose a unique challenge to the anesthesiologist, demanding very specific and thoughtful care to avoid injury and airway compromise. Considering that these patients are likely to undergo multiple surgeries in their early years, it is imperative to create a standard of practice and over the past few decades, there has been a growing body of knowledge suggesting best practices

for safe anesthesia.¹¹

Optimal positioning is easily achieved with gel pads, Vaseline gauze, XeroformTM, copious petroleum based lubrication, and minimal touch principles.¹² Monitoring can be streamlined to utilize pulse oximetry for oxygenation and heart rate, non-invasive temperature and blood pressures cycling at longer intervals to reduce pressure on skin. All adhesive tapes that would otherwise normally be used to secure the airway and IV should be avoided. Less clear is a standard strategy for airway management, as each patient's unique anatomy and surgical factors significantly impact the approach. Many techniques have been reported for patients with EB, each with potential advantages and challenges to be considered while developing an anesthesia plan¹³. We have previously documented by direct vision with fiberoptic bronchoscopy, that endotracheal intubation can be done without causing airway damage¹⁴.

Extreme care must be taken during mask ventilation to avoid undue manipulation, pressure, or shearing forces on the face and mandible. Petroleum based lubrication should be generously applied to the mask and gloves, with minimal mandibular traction, using a two handed technique for ventilation. It is noted that these patients are often easy to mask ventilate due to oral and lingual scarring creating space in the oropharynx without obstruction¹⁵. While these children may be able to tolerate mask ventilation for short cases, prolonged masking is not ideal, and intubation of the trachea is often necessary for longer duration surgeries¹⁶. Intubation techniques should minimize trauma to the oropharynx and trachea without creation of new bullae or ulcers. Well lubricated LMAs and blind nasal intubation have been used with success, with a low incidence of new bullae formation¹⁶; however, they are not free of traumatic contact and the lack of direct visualization and inability to assess for new trauma post-operatively makes these methods less desirable.

Direct laryngoscopy is the standard for favorable airways with good success in most patients¹⁶. When a difficult airway is expected, awake-fiberoptic intubation may be considered. However, this technique will not be tolerated in children¹⁶. If initial laryngoscopy is unsuccessful, glidescope, fiberoptic, or a combination of the two techniques dramatically improves intubating conditions, allows for easy visualization of structures, and can confirm placement of the ETT¹⁶. The use of a glidescope to assist placement of a nasal fiberoptic bronchoscope has been described, with the benefit of having

a grade 1 view of the cords while passing the fiberoptic bronchoscope¹⁴.

We describe airway management in an EB patient using an LMA technique with video laryngoscopic assistance, designed for first-pass success but can also be used as a rescue maneuver. This method may be of benefit in certain circumstances, especially when providing general anesthesia for relatively short or non-invasive surgeries, or efficiently securing the airway following failed initial direct laryngoscopy. The Glidescope™ MAC blade functions by direct contact with the tongue with minimal epiglottal pressure to generate optimal conditions for visualization of the vocal cords¹⁴. When lubricated generously with petroleum-based lube, the risk of shearing trauma can be greatly minimized. Additionally, the tongue is the most resistant tissue in the oropharynx to bullae formation and can be manipulated carefully without the same concern for epithelial damage with a Miller blade, or via nasal intubation¹⁶. This method may reduce additional damage due to repeated instrumentation of the upper airway or trachea, especially if the patient has extensive ulceration prior to surgery.

Anesthesiologists caring for patients with DEB strive to prevent new sores or bullae formation during the procedure or as a result of perioperative care¹⁷. While other reports have noted that LMA use is safe in these patients, to our knowledge this is the first report of the use of video technology to actually demonstrate the technique does not cause damage. In this case, it was clear upon re-examination that no new trauma was present in the oropharynx, allowing the providers to feel confident that airway management was not responsible for any new oropharyngeal sores. Imaging captured during intubation and extubation may also help with anesthetic planning for future surgeries.

Recent therapeutic advancements for patients with EB involving exogenous administration of topical collagen-based gene therapies have gained traction and are being studied extensively via clinical trials in patients¹⁸, including ours. Specifically, our patient is participating in a clinical trial based out of Orange County, California that studied the potential beneficial impact of dressing local skin sores with a topical medication consisting of viral factor infected with the collagen VII gene. On examination of the patient, it was obvious that the treatments appeared to be helping greatly with healing and promoting more durable skin growth. An avenue of future study particularly relevant to

anesthesiologists caring for DEB would be whether new gene therapies applied topically during the perioperative period could promote consistent wound healing in delicate mucosal surfaces of the airway, such as the oropharynx and laryngotracheal structures¹⁹. With the advent of more advanced molecular therapeutic options for EB patients, the pre-operative airway assessment may benefit greatly, as these patients require serial operative interventions.

CONCLUSION

For patients with Epidermolysis Bullosa, even with a favorable airway exam, it is prudent to have available airway adjuncts such as video laryngoscope and fiberoptic bronchoscope, should a difficult airway arise. We have demonstrated that video assisted placement of an LMA is a safe and practical method to secure an airway, avoid extended mask ventilation, and minimize oropharyngeal trauma. This technique also has the benefit of airway visualization, documenting bullae/ulcers prior to surgery, and confirm adequate placement prior to the start of surgery.

References

1. Bowen L, Burtonwood M. Anaesthetic management of children with epidermolysis bullosa. *BJA Education*. 2018;18(2):41-45
2. Herod J, Denyer J, Goldman A, Howard R. Epidermolysis bullosa in children: pathophysiology, anaesthesia and pain management. *Pediatric Anesthesia*. 2002;12(5):388-397.
3. Nandi R, Howard R. Anesthesia and Epidermolysis Bullosa. *Dermatol Clin* 2010;28:319-324
4. Griffin RP, Mayou BJ. The anaesthetic management of patients with dystrophic epidermolysis bullosa. *Anaesthesia*. 1993;48(9):810-815. doi:10.1111/j.1365-2044.1993.tb07599.x.
5. Gottschalk A, Venherm S, Vowinkel T. Anesthesia for balloon dilatation of esophageal strictures in children with epidermolysis bullosa dystrophica: from intubation to sedation. *Current Opinion in Anaesthesiology*. 2010;23(4):518-522. doi:10.1097/aco.0b013e32833bb50b.
6. Ames W.A, Mayou BJ, Williams K. Anaesthetic management of epidermolysis bullosa. *British Journal of Anaesthesia*. 1999;82(5):746-751.
7. Crowley K, Shevchenko Y. Anesthetic management of a difficult airway in a patient with epidermolysis bullosa: a case report. *AANA Journal*. 2004;23(4):261-263.
8. Ozkan AS, Kayhan GE, Akbas S. Emergency difficult airway management in a patient with severe epidermolysis bullosa. *Turk J Anesthesiol Reanim*. 2016; 44:270-272.
9. Fitzmaurice BC, Lambert BG. Failed fiberoptic intubation in a child with epidermolysis bullosa, rescued with combined use of the glidescope. *Pediatric Anesthesia*. 2016;26:255-256.
10. Aronson L.A. Images in Anesthesiology: Child with junctional epidermolysis bullosa, hoarseness, and nasal obstruction demonstrating severe laryngeal stenosis. *Anesthesiology* 2016;125(5):1044.
11. Van Den Huevel I, Bosch M, Langer M. Anesthetic management in pediatric patients with epidermolysis bullosa: a single center experience. *Minerva*

Anesthesiologica. 2013;79(7); 727-732.

12. Furukawa L, Krane E. Guidelines for the anesthetic management of epidermolysis bullosa (EB). Division of Pediatric Anesthesia and Pain Management Lucile Salter Packard Childrens Hospital. 2012.

<http://med.stanford.edu/content/dam/sm/pedsanesthesia/documents/EBanesthesiaguidelines.pdf>

13. Frohlich S, O'Sullivan E Airway management in adult patients with epidermolysis bullosa dystrophica: a case series. Journal of the Association of Anesthetists of Great Britain and Ireland. 2011;66:842-843.

14. A Rosenbaum, M Follansbee, J Crowley. Management of a Difficult Airway in a Child with Epidermolysis Bullosa Dystrophica Using a Combination of Direct Laryngoscopy and Fiberoptic Bronchoscopy. The Internet Journal of Anesthesiology. 2019 Volume 38 Number 1.

15. Lin AN, Lateef F, Kelly R. Anesthetic management in epidermolysis bullosa: review of 129 anesthetic episodes in

32 patients. Journal of the American Academy of Dermatology. 1994;30(3):412-416.

16. James I, Wark H. Airway management during anesthesia in patients with epidermolysis bullosa dystrophica. Anesthesiology. 1982;56(4):323-326.

17. Tuncer S, Sezgin B, Kaya B. An algorithmic approach for the management of hand deformities in dystrophic epidermolysis bullosa. J Plast Surg Hand Surg. 2018 Apr;52(2):80-86.

18. Has C, South A, Uitto J. Molecular Therapeutics in Development for Epidermolysis Bullosa: Update 2020. Mol Diagn Ther. 2020;24(3):299-309. doi:10.1007/s40291-020-00466-7

19. Gurevich I, Agarwal P, Zhan P. In vivo topical gene therapy for recessive dystrophic epidermolysis bullosa: a phase 1 and 2 trial. Nat Med 28, 780–788 (2022). <https://doi.org/10.1038/s41591-022-01737-y>

Author Information

John J. Choi, MD. Resident Physician, PGY-3

UC San Diego Health. Department of Anesthesiology

R. Abrams

M. Greenberg